

PATIENT

Nemo Guerrero

SPECIES

Canine

BREED

Scottish Terrier

SEX

Neutered Male

AGE

13y

WEIGHT

21.4lbs

INTERPRETED BY

Kathleen Sennello DVM,
MS, Diplomate ACVIM
(Small Animal Internal
Medicine)

**IMAGING
PERFORMED BY**

Loetitia Saint-Jacques,
LVT

HOSPITAL NAME

MountainView Animal
Hospital

REFERRING VET

Dr. Sarah Kalivoda

INVOICE

10030

DATE

2/10/2023

PRESENTING CLINICAL SIGNS

suspect protein losing enteropathy. chronic diarrhea and weight loss w/ minimal response to anti-diarrheal's, diet management. ~ Current medications ~metronidazole, proviable

Abnormal PE/Chem/CBC/UA Results: eosinophilia 6.1 (0.07-1.49), basophilia 0.4 (0-0.1) -fecal PCR screen negative hypocalcemia (8) TP: 4.5 albumin 1.6 ALP:284 USG 1.020, UPC 0.3 ~

ULTRASONOGRAPHIC EXAMINATION OF THE ABDOMEN

Urinary System

The urinary bladder is moderately distended with anechoic urine. The Bladder wall, trigone, ureteral papillae, and visible urethra (to a depth of 2cm) appear normal with no evidence of wall thickening, mucosal irregularities, masses, or cystic calculi.

The prostate is large in size (2.87 cm) with smooth borders for this neutered male dog. The parenchyma is heterogenous and hyperechoic, and has a small parenchymal cyst measuring 0.47 cm. The prostatic urethra appears normal with no evidence of irregularity, invasion, mass effect or calculi.

The left kidney has a normal shape and size (5.6 cm) with small cortical cysts. Overall echogenicity is slightly hyperechoic with poor corticomedullary distinction and a typical 1:3 cortex: medulla ratio. There is no evidence of focal perinephric inflammation or effusion. Mild pyelectasia measuring at 2.8 cm. There is no evidence of pyelectasia, nephroliths, infarcts or hydroureter. Renal vasculature is normal.

The right kidney has a normal shape and size (4.5 cm). Overall echogenicity is slightly hyperechoic with poor corticomedullary distinction and a typical 1:3 cortex: medulla ratio. There is no evidence of focal perinephric inflammation or effusion. There is no evidence of pyelectasia, nephroliths, infarcts or hydroureter. Renal vasculature is normal.

Adrenal Glands

The left adrenal gland is normal in size measuring 0.63 cm at the caudal pole. It is observed in its normal position cranial to the left renal artery. It is normal in appearance (uniformly hypoechoic) and shape with no evidence of a mass effect.

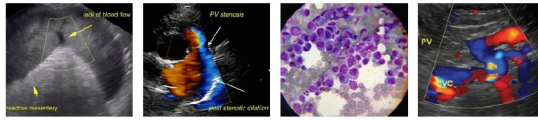
The right adrenal gland is normal in size measuring 0.53 cm at the caudal pole. It is observed in its normal position between the cranial aspect of the right kidney and the caudal vena cava. It is normal in appearance (uniformly hypoechoic) and shape with no evidence of a mass effect.

Spleen

The spleen is subjectively normal in size, echotexture is homogenous, and the splenic capsule is smooth with no irregularities. The blood flow through the hilus and splenic parenchyma appears normal. No focal parenchymal abnormalities are visualized.

Liver

The liver is large in size, and normal in echogenicity with smooth peripheral margins. The parenchyma is heterogenous in echotexture with subtle, indistinct focal mottling. The visible portions of the vasculature and biliary tract appear normal. There is a hyperechoic region/mass effect along the



PATIENT

Nemo Guerrero

SPECIES

Canine

BREED

Scottish Terrier

SEX

Neutered Male

AGE

13y

WEIGHT

21.4lbs

INTERPRETED BY

Kathleen Sennello DVM,
MS, Diplomate ACVIM
(Small Animal Internal
Medicine)

**IMAGING
PERFORMED BY**

Loetitia Saint-Jacques,
LVT

HOSPITAL NAME

MountainView Animal
Hospital

REFERRING VET

Dr. Sarah Kalivoda

INVOICE

10030

DATE

2/10/2023

diaphragmatic surface of the liver measuring 2.68 cm x 3.51cm. Additionally, there is hypoechoic area/mass lesion towards the ventral aspect of the liver measuring 2.71 cm x 1.46 cm.

The gall bladder lumen is significantly distended. Some areas of the wall appear mildly thickened with adherent debris and some areas have early mucosal stranding and organization of the debris into an early mucocele. There is a large amount of primarily non-organized echogenic debris present as well. There is no evidence of bile duct dilation.

Gastrointestinal

The stomach contains minimal luminal contents. It measures at a normal thickness of <0.7cm with some variability due to the presence of rugal folds. The distinction of the gastric wall layers is adequate and there is no impression of reduced peristaltic activity. No masses or focal lesions were observed.

The visualized areas of duodenum, jejunum and ileum have a relatively uniform diameter with minimal fluid distension. Wall thickness is normal. Bowel loops follow a curvilinear path with distinct wall layering maintaining the typical 1:3 muscularis: mucosa layer ratio. The duodenum measured as normal (0.43 cm), and the jejunum measured as normal (0.32 cm.) Visualized peristalsis appears appropriate. There is a large mid abdominal hypoechoic, irregular bowel mass measuring approximately 6.17 cm x 7.13 cm with thickened wall measuring 1.75 cm and complete loss of layering. This lesion could be arising from the large or small bowel.

The ileocecal junction was visualized and exhibited normal intact wall layering and is subjectively of normal thickness. Sections of colon are visualized with formed fecal material and gas shadowing distally. There is no observed focal or generalized colon wall thickening or loss of layering. There is a large midabdominal bowel mass described under small intestine. It is difficult to discern if this is arising from the small or large bowel.

Pancreas

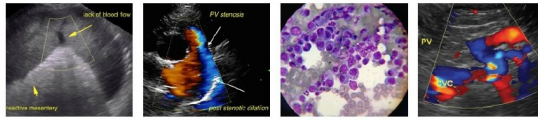
The area pancreas is normal and isoechoic to surrounding mesentery. There is no evidence of nodules or cystic lesions. There is no evidence of regional mesenteric inflammation or fluid.

Free Abdomen

Evaluation of the peritoneal cavity did not reveal any free fluid and no significant lymphadenomegaly. The Medial iliac nodes appear normal and there was no evidence of a caudal aortic thrombus at the bifurcation. The omentum is hyperechoic around the large bowel mass.

PRIMARY FINDINGS

- Large irregular bowel mass with severely thickened walls and complete loss of layering. This is a midabdominal bowel mass, arising either from the small or large bowel. Primary differential would be round cell neoplasia. Recommend a fine needle aspirate.
- Decreased corticomedullary distinction in both kidneys with small cortical cysts and left sided pyelectasia. The bilateral renal findings are consistent with age-related change. Pyelectasia of the left kidney could be consistent with pyelonephritis, chronic renal disease, secondary to PU/PD or fluid therapy (if applicable), other.
- Large hyperechoic prostate with hypoechoic cysts. Correlate this with the age of neutering, in most dogs this would be very atypical and there would be a significant concern for underlying



PATIENT

Nemo Guerrero

SPECIES

Canine

BREED

Scottish Terrier

SEX

Neutered Male

AGE

13y

WEIGHT

21.4lbs

INTERPRETED BY

Kathleen Sennello DVM,
MS, Diplomate ACVIM
(Small Animal Internal
Medicine)

IMAGING PERFORMED BY

Loetitia Saint-Jacques,
LVT

HOSPITAL NAME

MountainView Animal
Hospital

REFERRING VET

Dr. Sarah Kalivoda

INVOICE

10030

DATE

2/10/2023

neoplastic change. Scottie's have large prostates so this could be normal in this individual.

- Large heterogenous liver with hyper and hypoechoic ill-defined mass lesions. The diffuse hepatic changes are non-specific and could be consistent with vacuolar hepatopathy, nodular hyperplasia, inflammatory/immune-mediated disease, fibrosis, extramedullary hematopoiesis, toxic hepatopathy (e.g., copper), infiltrative neoplasia (less likely) or other hepatopathy. Both lesions described are ill-defined and do not appear to significantly deviate the hepatic margins. Consider sampling or continued monitoring.
- Significantly distended gallbladder with large number of intraluminal debris and very early organization. The gall bladder changes are most consistent with a developing mucocele. Consider medical management and close monitoring for progression of this lesion.

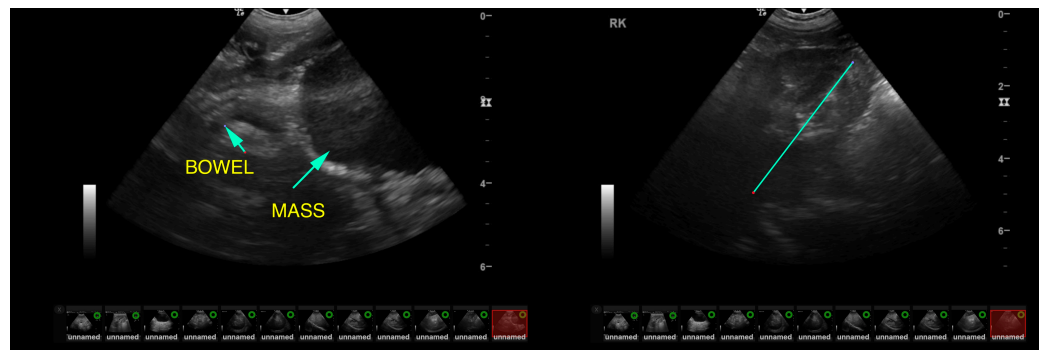
INTERPRETATION OF THE FINDINGS & FURTHER RECOMMENDATIONS

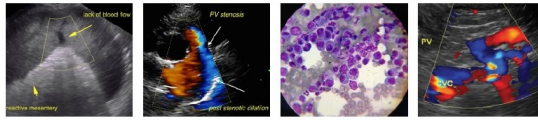
There is a very large midabdominal bowel mass visualized, the wall is severely thickened with complete loss of layering and surrounding inflammation. Recommend a fine needle aspirate of this lesion, as round cell neoplasia would be the primary differential but carcinoma and other differentials are possible. The exact origin of this mass effect is unclear as it may involve both small and large bowel. Based on a cytologic diagnosis, consultation with veterinary oncologist should be considered, to discuss possible medical and surgical options.

Recommend three view thoracic radiographs to evaluate for possible concurrent thoracic disease/involvement.

The liver is heterogenous with numerous ill-defined lesions. Cannot rule out the possibility of metastatic disease, but benign regenerative nodule type lesions are also possible.

The prostate is large, hyperechoic, and mildly cystic in this neutered male dog. This is atypical for most neutered dogs unless, the patient was neutered after puberty or recently. Additionally, Scottie's have large prostates, so this could be normal for this individual. Consider a fine needle aspirate of the prostate.





PATIENT

Nemo Guerrero

SPECIES

Canine

BREED

Scottish Terrier

SEX

Neutered Male

AGE

13y

WEIGHT

21.4lbs

INTERPRETED BY

Kathleen Sennello DVM,
 MS, Diplomate ACVIM
 (Small Animal Internal
 Medicine)

**IMAGING
 PERFORMED BY**

Loetitia Saint-Jacques,
 LVT

HOSPITAL NAME

MountainView Animal
 Hospital

REFERRING VET

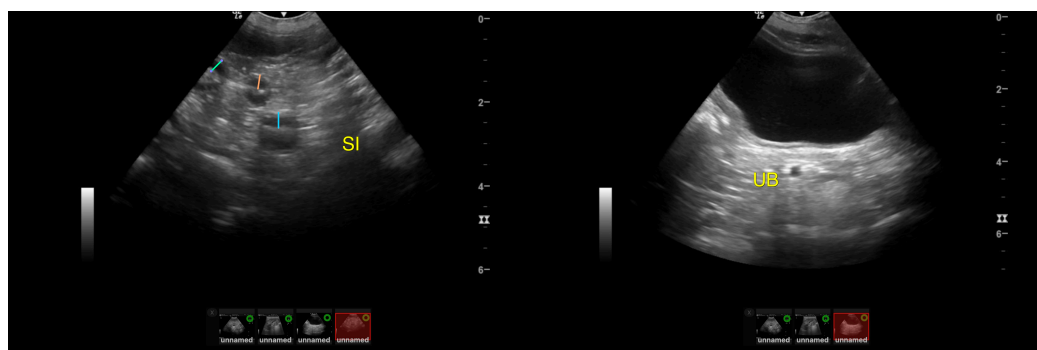
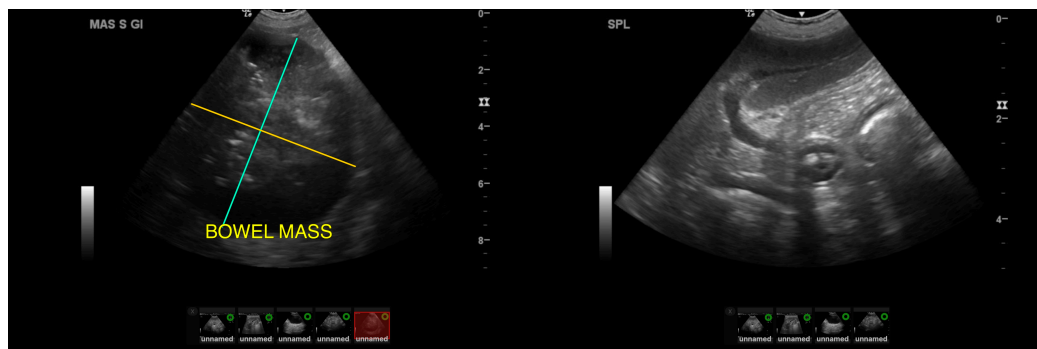
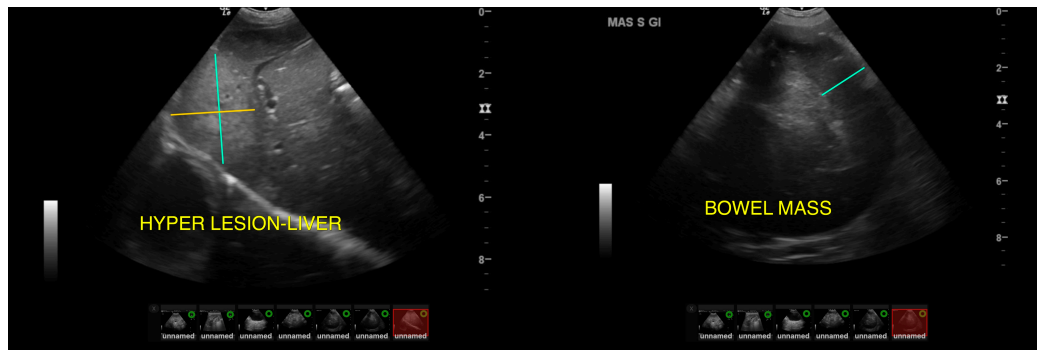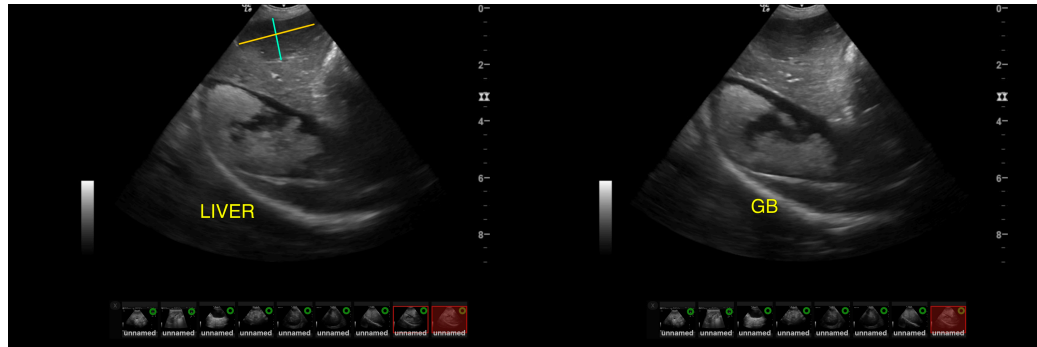
Dr. Sarah Kalivoda

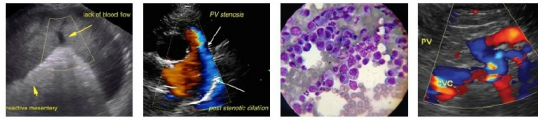
INVOICE

10030

DATE

2/10/2023





PATIENT

Nemo Guerrero

SPECIES

Canine

BREED

Scottish Terrier

SEX

Neutered Male

AGE

13y

WEIGHT

21.4lbs

INTERPRETED BY

Kathleen Sennello DVM,
 MS, Diplomate ACVIM
 (Small Animal Internal
 Medicine)

IMAGING PERFORMED BY

Loetitia Saint-Jacques,
 LVT

HOSPITAL NAME

MountainView Animal
 Hospital

REFERRING VET

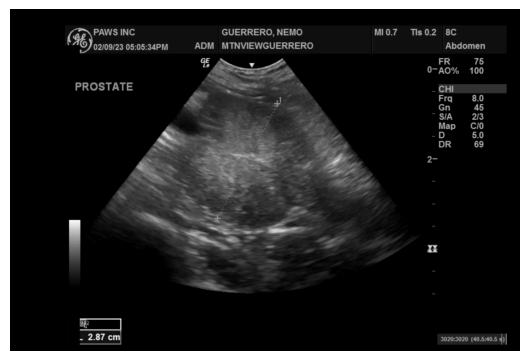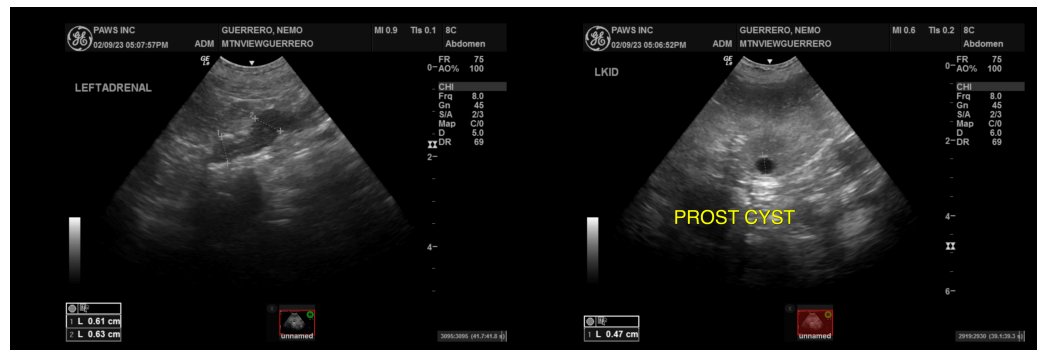
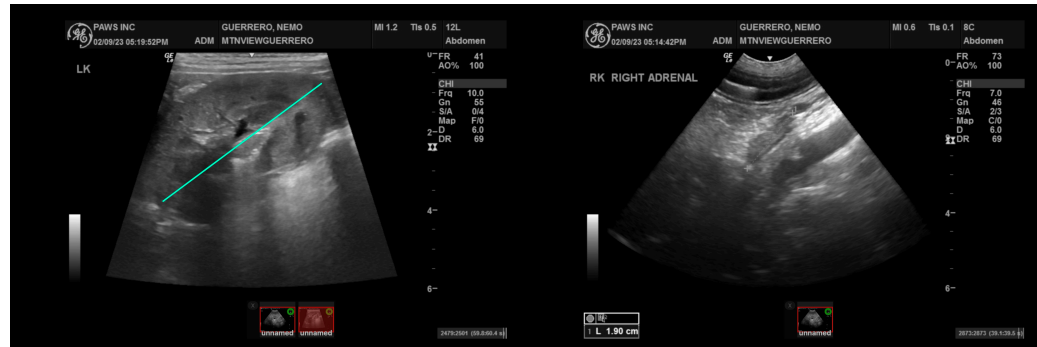
Dr. Sarah Kalivoda

INVOICE

10030

DATE

2/10/2023



The information and recommendations provided are based on the images presented by the referring veterinarian/sonographer. No evaluation can be communicated regarding pathology that was not visible in the image/video clips provided.

Thank you for this referral. If the clinical or image interpretation does not parallel your findings or if I can be of any further assistance, please contact me.

Kathleen Sennello DVM, MS, Diplomate ACVIM (Small animal Internal Medicine)

kathleen.sennello@sonopath.com