



PATIENT

Desmond Aiken

SPECIES

Feline

BREED

DSH

SEX

Neutered Male

AGE

7/27/2014

WEIGHT

8.5 lbs

INTERPRETED BY

Eric Lindquist, DMV
DABVP, Cert IVUSS

**IMAGING
PERFORMED BY**

Denise Bruno, LVT,
RDMS

HOSPITAL NAME

Brooklyn Heights VH

REFERRING VET

Dr. Thomson

INVOICE

0000

DATE

10/19/21

PRESENTING CLINICAL SIGNS

History: Intestinal thickening

Decreased globulins/Protein

Evaluate for IBD, lymphoma

Labs + Radiographs attached

ULTRASONOGRAPHIC EXAMINATION OF THE ABDOMEN

Urinary System

The **urinary bladder**, trigone, and pelvic urethra presented normal thicknesses and normal tone. The ureters were not visible which is normal. No uroliths or sediment were visualized and anechoic urine was present. No evidence of inflammatory or neoplastic changes was noted. Ureteral papillae were normal.

The **kidneys** revealed largely normal size and structure, corticomedullary definition and ratio (cortex 1/3 of medulla) were essentially maintained with some age-related loss of curvilinear patterns regarding the capsule and C/M junction. The cortices presented largely uniform texture with some increased echogenicity expected for this age patient. Medullary structure differed distinctly from that of the cortex and no evidence of pelvic dilation was present. Slight mineralization was noted in the kidneys. The right kidney measured 4.13 cm. The left kidney measured 3.64 cm.

Adrenal Glands

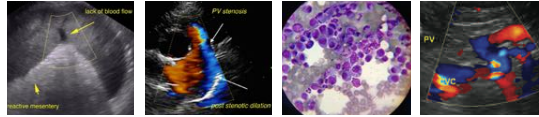
Both **adrenal glands** were visualized and recognized as having normal shape, size, position and echogenicity for this breed. The phrenic vasculature, glandular echogenicity and detail were unremarkable. Capsule, cortex, and medullary definition were normal for this age patient. The right adrenal gland measured 0.29 cm. The left adrenal gland measured 0.36 cm.

Spleen

The **spleen** presented a smooth homogeneous parenchyma hyperechoic to liver and renal cortical parenchyma. The capsule was smooth without noticeable expansion or deviation from within the spleen or adjacent pathology. The splenic vasculature demonstrated normal volume without signs of congestion or thrombosis. No sonographic evidence of acute or chronic inflammatory, neoplastic, or infarctual changes was noted.

Liver

The **liver** images submitted revealed subjectively normal liver size, contour, and structure. Parenchymal echogenicity was naturally coarse and hypoechoic to the spleen. Vascular and biliary tracts were of normal volume with no evidence of congestion. The gallbladder presented acceptably thin walls with primarily anechoic content. The cystic and common bile ducts were normal. No pathological hepatic lymphadenopathy was evident. No overt structural evidence of inflammatory, infiltrative or regenerative pathology was evident.



PATIENT

Gastrointestinal

Desmond Aiken

SPECIES

Feline

BREED

DSH

SEX

Neutered Male

AGE

7/27/2014

WEIGHT

8.5 lbs

INTERPRETED BY

Eric Lindquist, DMV
DABVP, Cert IVUSS

IMAGING PERFORMED BY

Denise Bruno, LVT,
RDMS

HOSPITAL NAME

Brooklyn Heights VH

REFERRING VET

Dr. Thomson

INVOICE

0000

DATE

10/19/21

The stomach was empty and not overtly involved in the process. An extensive intestinal mass was noted in the cranial abdomen and measured 7.3 x 4.7 cm. The mass was undifferentiated and impinged upon the stomach cranially. A separate mass was noted in the cranial abdomen and involved the small intestine. Variable other areas of intestinal thickening were noted without loss of detail. However, two separate GI masses are consistent with intestinal lymphoma. Regional inflammation was noted around the intestinal masses. Micrometastasis is a potential in these cases.

Pancreas

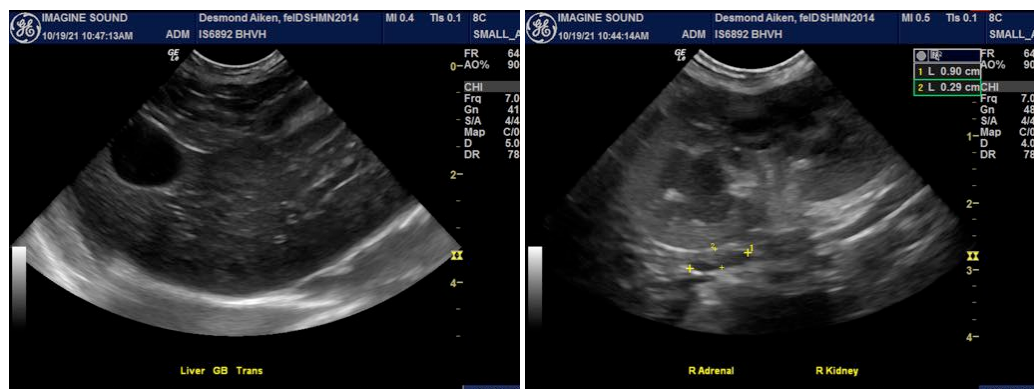
The base and limbs of the **pancreas** were observed to be largely isoechoic to surrounding omental fat. Some parenchymal remodeling, however, with mild deviation from curvilinear normalcy was observed. Pancreatic duct and capsular irregularities were present consistent with age related changes. If pain upon imaging (+ Murphy sign) was present or if the patient is focally painful in subxiphoid palpation then low-grade smoldering chronic pancreatitis should be suspected.

ULTRASONOGRAPHIC FINDINGS

Two separate intestinal masses.

INTERPRETATION OF THE FINDINGS & FURTHER RECOMMENDATIONS

Assessment of the FNA results and immediate chemotherapeutic intervention is recommended. The prognosis is guarded to poor depending upon the type of neoplasia and responsiveness to chemotherapy.





PATIENT

Desmond Aiken

SPECIES

Feline

BREED

DSH

SEX

Neutered Male

AGE

7/27/2014

WEIGHT

8.5 lbs

INTERPRETED BY

Eric Lindquist, DMV
DABVP, Cert IVUSS

**IMAGING
PERFORMED BY**

Denise Bruno, LVT,
RDMS

HOSPITAL NAME

Brooklyn Heights VH

REFERRING VET

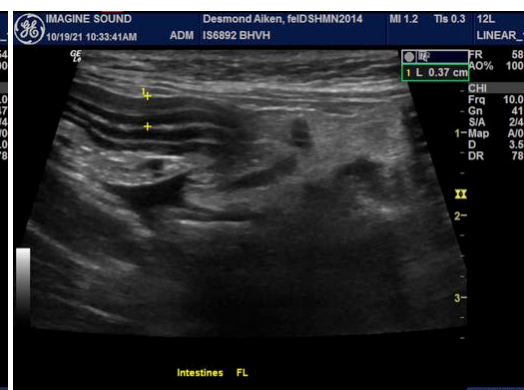
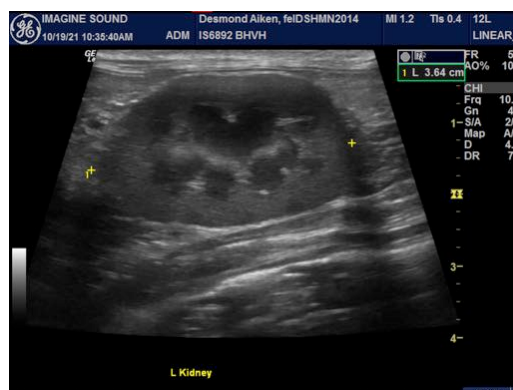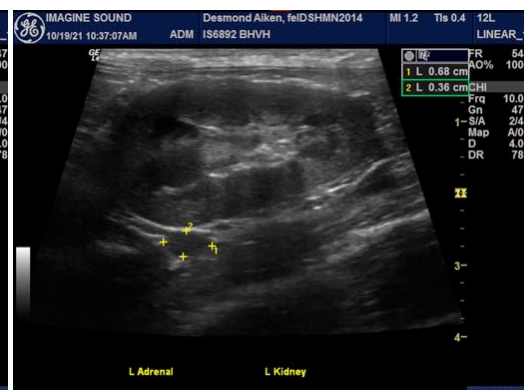
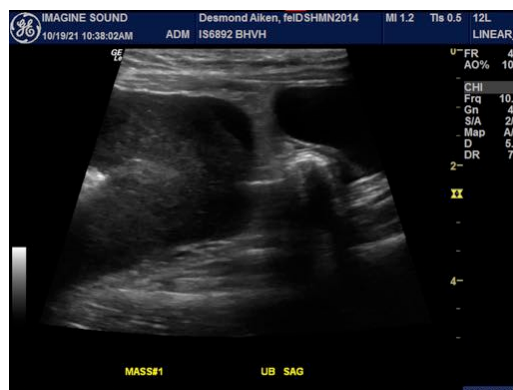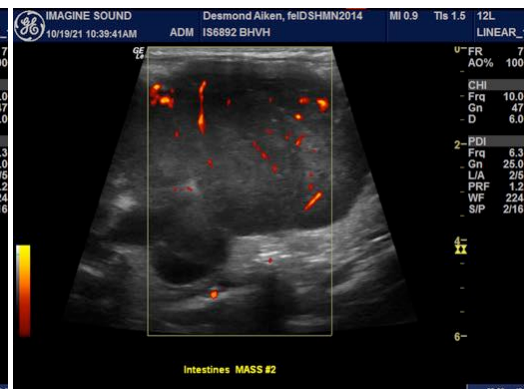
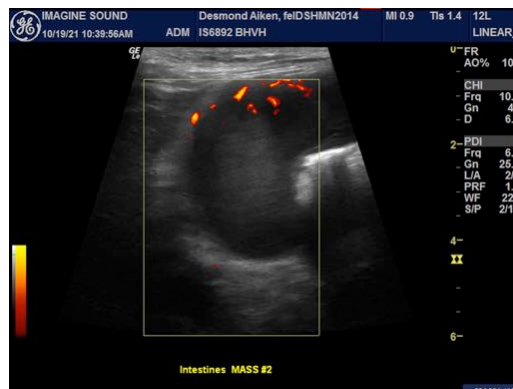
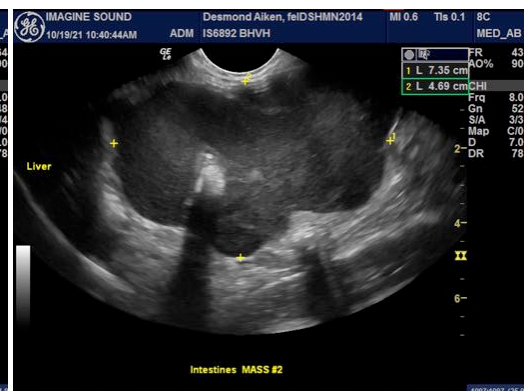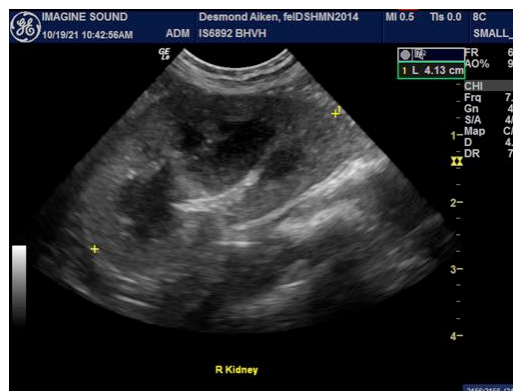Dr. Thomson

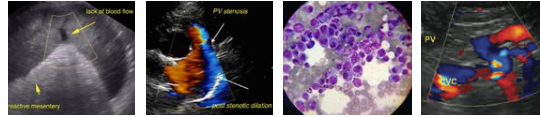
INVOICE

0000

DATE

10/19/21





PATIENT

Desmond Aiken

SPECIES

Feline

BREED

DSH

SEX

Neutered Male

AGE

7/27/2014

WEIGHT

8.5 lbs

INTERPRETED BY

Eric Lindquist, DMV
DABVP, Cert IVUSS

**IMAGING
PERFORMED BY**

Denise Bruno, LVT,
RDMS

HOSPITAL NAME

Brooklyn Heights VH

REFERRING VET

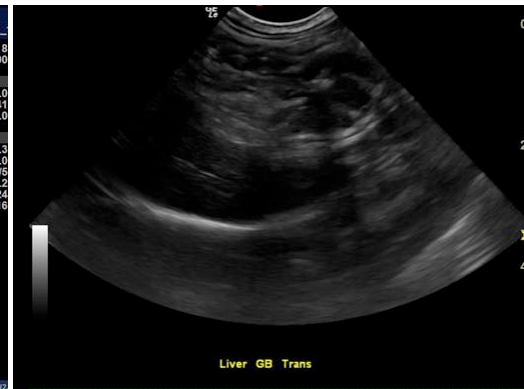
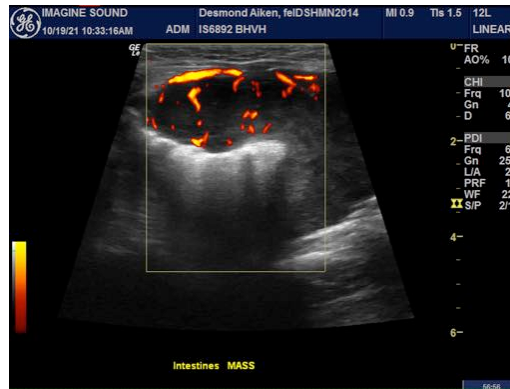
Dr. Thomson

INVOICE

0000

DATE

10/19/21



The information and recommendations provided are based on the images presented by the referring veterinarian. No evaluation can be communicated regarding pathology that was not visible in the image/video clips provided.

Thank you for this referral. If the clinical or image interpretation does not parallel your findings or if I can be of any further assistance please contact me.

Eric Lindquist, DMV, DABVP, Cert. IVUSS, CEO of SonoPath.com
Eric.Lindquist@SonoPath.com