



**PATIENT**

Eddie Parisen

**SPECIES**

Canine

**BREED**

Retriever Mix

**SEX**

Neutered Male

**AGE**

9 Years 5 Months

**WEIGHT**

99 Pounds

**INTERPRETED BY**

Tam Mengine DVM,  
DABVP (Canine/Feline  
Practice)

**IMAGING PERFORMED BY**

Vincent Ravancho,  
CVT

**HOSPITAL NAME**

Sova AH

**REFERRING VET**

Dr. Ammeraal

**INVOICE**

36751

**DATE**

4/24/26

**PRESENTING CLINICAL SIGNS**

History: Recheck - Stage B2 Myxomatous Mitral Valve Disease. Grade III/VI HM

Current medications - Pimobendan q12hr - did not get this AM. Apoquel 16 mg SID.

**ULTRASONOGRAPHIC EXAMINATION OF THE HEART**

| CANINE CARDIAC PARAMETERS | MR VMAX (m/s) | TR VMAX (m/s) | LA/AO (m-mode long axis) | LA/AO (Heart Base; Swe) | FS (%)               | EF (%)                                   | EPSS (cm)                                |
|---------------------------|---------------|---------------|--------------------------|-------------------------|----------------------|--|--|
| NORMAL PARAMETER          | 4.5-5.5       | <2.7          | 1.3                      | Up to 1.6               | 28-40                | 40-100                                   | <0.6                                     |
| PATIENT                   | 4.8           | 2.7           | NM                       | 1.5                     | 50                   | NM                                       | 0.3                                      |
| CANINE CARDIAC PARAMETERS | HR (BPM)      | AV VMAX (m/s) | PV MAX (m/s)             | BODY WEIGHT (kg)        | LAD LA MAX 4 Chamber | LVIDd Avg; 2D and m-mode short axis (cm) | LVIDs Avg; 2D and m-mode short axis (cm) |
| NORMAL PARAMETER          | 50-100        | 0.7-1.7       | 0.7-1.6                  |                         |                      |  |  |
| PATIENT                   | 145           | NM            | 0.8                      | 45                      | 5.3                  | 5.2                                      | 2.6                                      |

**Cardiac Presentation**

The **left atrium** is mildly enlarged, with no evidence of smoke or thrombus formation. The **left ventricle** is mildly dilated with normal wall thickness and demonstrates good systolic function. The **right atrium** is subjectively of normal size and **right ventricle** dimensions, and systolic function are subjectively normal. There is significant **mitral valve** regurgitation, with prolapse of the anterior leaflet, and trivial **tricuspid valve** regurgitation noted, with irregular thickening of the mitral valve leaflets. No vegetative lesions were seen. The **aortic** and **pulmonary valves** both exhibit normal appearance and function. The **main pulmonary artery** appears normal. There is no evidence of clinically significant pulmonary hypertension. No pericardial/pleural effusion or cardiac masses are seen. There is no evidence of an arrhythmia.

**ULTRASONOGRAPHIC FINDINGS**

- Myxomatous mitral valve disease (MMVD) – Stage B2 - stable as compared to December 2025

**INTERPRETATION OF THE FINDINGS & FURTHER RECOMMENDATIONS**

- There has been no progression of the patient's heart enlargement since the last echocardiogram in December 2025. Thus, it is recommended to continue pimobendan at the current dose, and no other cardiac medications are indicated at this time.
- Daily monitoring of the sleeping respiratory rate at home is recommended, and if the sleeping respiratory exceeds 35 breaths per minute, then a prompt recheck physical examination and chest radiographs to assess for pulmonary edema would be warranted.



**PATIENT**

Eddie Parisen

**SPECIES**

Canine

**BREED**

Retriever Mix

**SEX**

Neutered Male

**AGE**

9 Years 5 Months

**WEIGHT**

99 Pounds

**INTERPRETED BY**

Tam Mengine DVM,  
DABVP (Canine/Feline  
Practice)

**IMAGING  
PERFORMED BY**

Vincent Ravancho,  
CVT

**HOSPITAL NAME**

Sova AH

**REFERRING VET**

Dr. Ammeraal

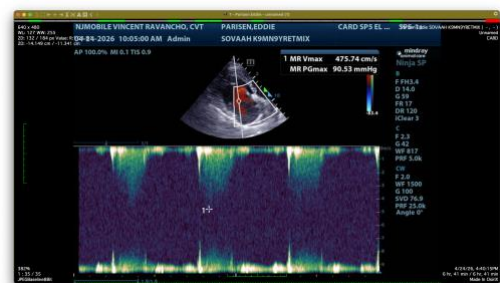
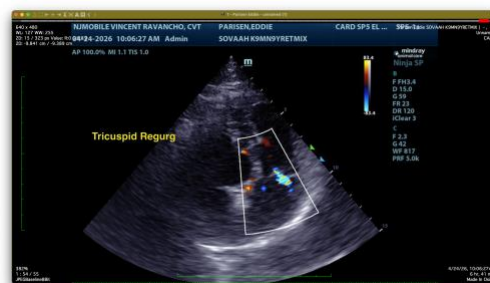
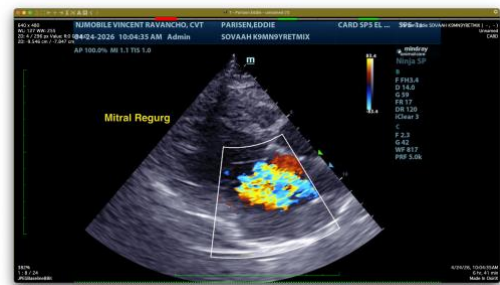
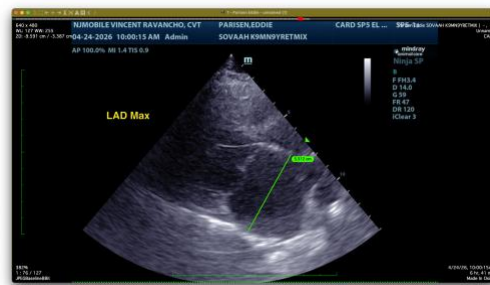
**INVOICE**

36751

**DATE**

4/24/26

- The patient may benefit from a cardiac diet such as Purina’s “CardioCare” veterinary diet. Omega-3 Fatty acid supplementation may also be of benefit.
- Extremely vigorous exercise should be avoided, but there are no restrictions on moderate exercise, such as leash walking.
- Recheck echocardiogram is recommended in 6-8 months. MMVD is a progressive disease, and it is likely that additional medication may be needed in the future.
- If anesthesia is needed, the following recommendations are suggested:
  - Avoid a-2 agonists such as dexmedetomidine and xylazine.
  - Pre-medication with an opiate and a benzodiazepine is recommended. Additionally, Gabapentin 10mg/kg PO and trazodone 5mg/kg PO given first thing in the morning on the day of the procedure can further reduce inhalant anesthetic requirements.
  - Pre-oxygenation, followed by induction with propofol or alfaxalone is recommended, followed by maintenance with isoflurane or sevoflurane.
  - When feasible, the use of local anesthetic blocks can decrease maintenance anesthetic requirements.
  - Moderate use of IV fluids throughout the procedure is recommended, with a starting dose of 3-5ml/kg/hr, with modest increases as needed to support blood pressure, but not to exceed a total volume of 20-30ml/kg for the procedure. The minimum volume necessary to maintain adequate blood pressure is desirable.
  - Use atropine, if necessary, to maintain a HR > 90 throughout the procedure. If available, a dopamine or dobutamine CRI can be used for additional blood pressure support if the patient experiences hypotension.





**PATIENT**

Eddie Parisen

The information and recommendations provided are based on the images presented by the referring veterinarian/sonographer. No evaluation can be communicated regarding pathology that was not visible in the image/video clips provided.

**SPECIES**

Canine

Thank you for this referral. If the clinical or image interpretation does not parallel your findings or if I can be of any further assistance please contact me.

**Tam Mengine, DVM, DABVP (canine/feline practice)**

**BREED**

Retriever Mix

info@SonoPath.com

**SEX**

Neutered Male

**AGE**

9 Years 5 Months

**WEIGHT**

99 Pounds

**INTERPRETED BY**

Tam Mengine DVM,  
DABVP (Canine/Feline  
Practice)

**IMAGING  
PERFORMED BY**

Vincent Ravancho,  
CVT

**HOSPITAL NAME**

Sova AH

**REFERRING VET**

Dr. Ammeraal

**INVOICE**

36751

**DATE**

4/24/26