



PATIENT

Ivee FOFF

SPECIES

Feline

BREED

DSH

SEX

Spayed Female

AGE

5 Months

WEIGHT

6.8 Pounds

INTERPRETED BY

Tam Mengine DVM,
DABVP (Canine/Feline
Practice)

IMAGING PERFORMED BY

Dr. Karen Ebersole
DVM, DABVP (Canine
and Feline)

HOSPITAL NAME

Scanvet

REFERRING VET

Dr. Giroux

INVOICE

36043

DATE

3/1/26

PRESENTING CLINICAL SIGNS

- Heart murmur
- Recent onset head tilt
- Acting normal at home
- Gabapentin for sedation

Abnormal PE/Chem/CBC/UA Results: PE: Grade 4/6 systolic heart murmur, head tilt. Rest of exam WNL. BW (2/11/2026) - WBC 19k, Lymph 9.4 k. Rest NSF. Fecal Ag (2/11) - Roundworm +

ULTRASONOGRAPHIC EXAMINATION OF THE HEART

FELINE CARDIAC PARAMETERS	BODY WEIGHT (kg)	HR (BPM)	IVSd (cm)	LVIDd (cm)	LVWd (cm)	FS (%)	EF (%)
NORMAL PARAMETER	-----	150-240	0.3-0.6	1.0-2.1	0.25-0.6	35-67	80-100
PATIENT	3.1	192	0.3	1.7	0.3	41	NM
FELINE CARDIAC PARAMETERS	LA/AO (m-mode long axis)	LA/AO HEART BASE (Sisson)	LAD LA MAX 4 Chamber		LVOT VEL. (m/s)	RVOT VEL. (m/s)	IVRT (m/)
NORMAL PARAMETER	<1.5	1.6	0.7-1.7		<1.6	<1.3	40-60
PATIENT	1.6	1.3	1.4		1.2	1.7	64
Adapted from June Boon, Veterinary Echocardiography, 1998 Sisson D et al. JVIM 1991; 5: 232, Jacobs et al. Am J Vet Res 1985; 46:1705							

Cardiac Presentation

The **left atrium** is at the upper limits of normal size, with no evidence of spontaneous echocardiographic contrast or thrombus formation. Left atrial systolic function appears adequate. The **left ventricle** exhibits normal free wall thickness and demonstrates good systolic function. Ventricular septum diastolic wall measurements are within normal limits. The **right atrium** is subjectively of normal size and **right ventricle** dimensions, and systolic function are subjectively normal. There is turbulent blood flow noted in the region of the perimembranous ventricular septum, with predominantly left-to-right flow observed with color and spectral Doppler interrogation. The defect measures 3.0 mm in diameter, with an Ao:VSD ratio of supporting a restrictive VSD. While the flow velocity across the VSD (3.9 m/s) is less typical of a restrictive VSD, it is also possible that this velocity is underestimated. The **mitral, tricuspid, aortic** and **pulmonary valves** all exhibit normal



PATIENT

Ivee FOFF

SPECIES

Feline

BREED

DSH

SEX

Spayed Female

AGE

5 Months

WEIGHT

6.8 Pounds

INTERPRETED BY

Tam Mengine DVM,
DABVP (Canine/Feline
Practice)

IMAGING PERFORMED BY

Dr. Karen Ebersole
DVM, DABVP (Canine
and Feline)

HOSPITAL NAME

Scanvet

REFERRING VET

Dr. Giroux

INVOICE

36043

DATE

3/1/26

appearance and function, and no vegetative lesions were seen. Flow velocity in the left ventricular outflow tract is normal, while flow velocity in the right ventricular outflow tract is mildly increased, likely due to "relative pulmonic stenosis" due to the left to right shunting. The **main pulmonary artery and its branches** appear subjectively dilated, however there is no other evidence of pulmonary hypertension at this time. There is no evidence of pericardial or pleural effusion, and no masses are seen.

ULTRASONOGRAPHIC FINDINGS

Left-to right perimembranous ventricular shunting defect (VSD) without evidence of hemodynamic significance at this time

INTERPRETATION OF THE FINDINGS & FURTHER RECOMMENDATIONS

The echocardiographic findings are consistent with a left-to-right ventricular septal defect. Evaluation by a board-certified cardiologist should be considered to further characterize the defect and evaluate shunting volume, but this would be unlikely to change underlying patient management at this time.

If the VSD is indeed restrictive, which seems likely, then it should not have an impact on the patient's long-term prognosis. If in fact there is a significant volume of left to right shunting, however, then the patient's long-term prognosis is more guarded, and an interventional procedure, such as pulmonary artery banding, may be indicated, to reduce the risk of future complications such as left sided congestive heart failure, thromboembolic disease, or shunt reversal due to secondary pulmonary hypertension. The client should be advised to monitor the sleeping respiratory rate, as this may be an early indicator of progression to congestive heart failure. Recheck echocardiogram would be recommended in 6 -12 months, once the patient is fully grown, to further characterize the lesion and whether any medical or surgical intervention would be indicated.

This patient has a mild risk of complications with general anesthesia. They are at risk for fluid overload, but also at risk for right to left shunting should they become hypotensive. The following recommendations for anesthesia are suggested:

- Avoid drugs that may cause significant vasodilation, such as acepromazine
- Pre-medicate with an opiate, and if needed a benzodiazepine. Oral gabapentin 2 hours prior to the procedure can also help lessen anesthetic needs.
- Induction with propofol or alfaxalone would be recommended over other induction protocols. The patient should be pre-oxygenated with flow-by O2 for 1-2 minutes prior to induction.
- Maintenance anesthesia on isoflurane or sevoflurane.
- Local blocks would be recommended whenever possible, to reduce inhalant anesthetic requirements.
- IV fluids should be used at modest doses, starting at 1-2ml/kg/hr.
- Continuous monitoring of ECG, pulse ox, capnography and blood pressure is recommended.
- Perioperative antibiotics should be considered, as humans with VSDs have an increased risk of developing endocarditis, though this has not been definitively demonstrated in cats.



PATIENT

Ivee FOFF

SPECIES

Feline

BREED

DSH

SEX

Spayed Female

AGE

5 Months

WEIGHT

6.8 Pounds

INTERPRETED BY

Tam Mengine DVM,
DABVP (Canine/Feline
Practice)

**IMAGING
PERFORMED BY**

Dr. Karen Ebersole
DVM, DABVP (Canine
and Feline)

HOSPITAL NAME

Scanvet

REFERRING VET

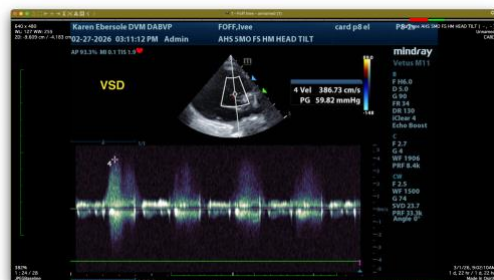
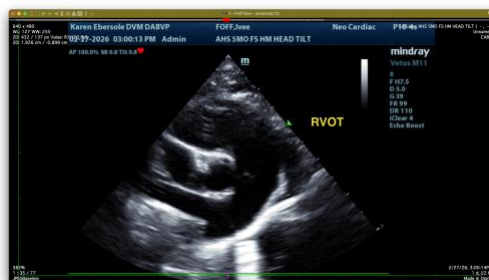
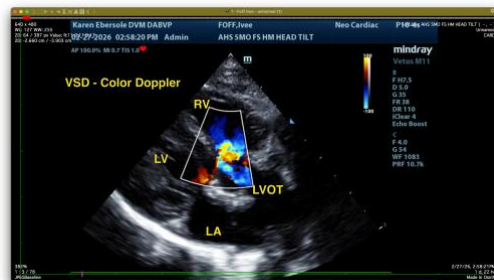
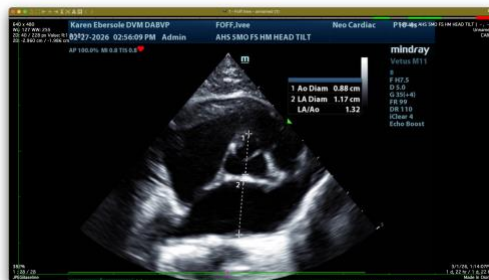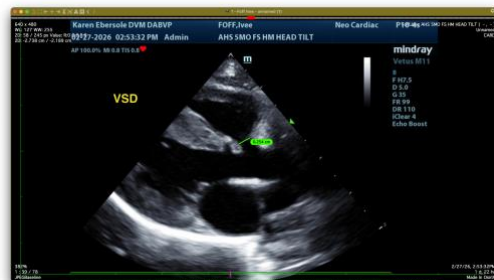
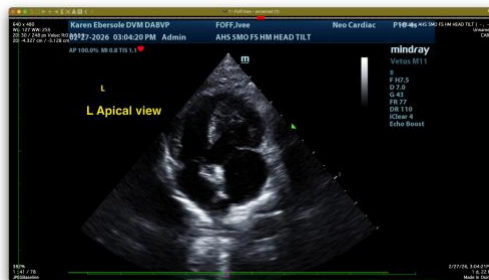
Dr. Giroux

INVOICE

36043

DATE

3/1/26



The information and recommendations provided are based on the images presented by the referring veterinarian/sonographer. No evaluation can be communicated regarding pathology that was not visible in the image/video clips provided.

Thank you for this referral. If the clinical or image interpretation does not parallel your findings or if I can be of any further assistance please contact me.

Tam Mengine, DVM, DABVP (canine/feline practice)

info@SonoPath.com