



**PATIENT**

Teddy Rogin

**SPECIES**

Canine

**BREED**

Cavalier King Charles  
Spaniel

**SEX**

Neutered Male

**AGE**

8 Years 6 Months

**WEIGHT**

30 pounds

**INTERPRETED BY**

Tam Mengine, DVM,  
DABVP (canine/feline  
practice)

**IMAGING  
PERFORMED BY**

Rebecca Hamilton

**HOSPITAL NAME**

Wyckoff Veterinary  
Hospital

**REFERRING VET**

Dr. Scott

**INVOICE**

13754

**DATE**

02/13/26

**PRESENTING CLINICAL SIGNS**

- Murmur 3/6
- chiari- like malformation neuro signs
- Meds: Rimadyl, Gabapentin

Abnormal PE/Chem/CBC/UA Results: WNL

**ULTRASONOGRAPHIC EXAMINATION OF THE HEART**

| CANINE<br>CARDIAC<br>PARAMETERS | MR<br>VMAX<br>(m/s) | TR<br>VMAX<br>(m/s) | LA/AO<br>(m-mode long<br>axis) | LA/AO<br>(Heart Base;<br>Swe) | FS<br>(%)                  | EF<br>(%)  | EPSS<br>(cm)   |
|---------------------------------|---------------------|---------------------|--------------------------------|-------------------------------|----------------------------|--|--|
| NORMAL<br>PARAMETER             | 4.5-5.5             | <2.7                | 1.3                            | Up to 1.6                     | 28-40                      | 40-100   | <0.6   |
| PATIENT                         | 6.4                 | NM                  |                                | 1.5                           | 35                         | 66   | 0.2  |
| CANINE<br>CARDIAC<br>PARAMETERS | HR<br>(BPM)         | AV<br>VMAX<br>(m/s) | PV<br>MAX<br>(m/s)             | BODY<br>WEIGHT<br>(kg)        | LAD<br>LA MAX 4<br>Chamber | LVIDd<br>Avg; 2D and m-<br>mode short axis<br>(cm) | LVIDs<br>Avg; 2D and<br>m-mode short<br>axis<br>(cm) |
| NORMAL<br>PARAMETER             | 50-100              | 0.7-1.7             | 0.7-1.6                        |                               |                            |  |  |
| PATIENT                         | 176                 | 1.3                 | 0.7                            | 13.6                          | 2.7                        | 3.0  | 2.0  |

**Cardiac Presentation**

The **left atrium** is of normal size with no evidence of spontaneous echo contrast or thrombus formation. The **left ventricle** is normal in diameter with normal wall thickness and demonstrates good systolic function. The **right atrium** is subjectively of normal size and **right ventricular** dimensions, and systolic function are subjectively normal. There is mild to moderate **mitral valve** regurgitation and trivial **tricuspid valve** regurgitation noted, with irregular thickening of the valve leaflets. There was no evidence of chordae tendineae rupture or valvular prolapse in either valve and no vegetative lesions were seen. Estimates of left ventricular filling pressures are normal (Mitral E-vel. 0.7 m/s, mitral A-vel. 0.8 m/s), and there was reversal of the E and A waves, which is an incidental finding in geriatric patients. The **aortic** and **pulmonary valves** both exhibit normal appearance and function. The **main pulmonary artery** appears normal. There is no evidence of pulmonary hypertension. No pericardial/pleural effusion or cardiac masses are seen. There is no evidence of an arrhythmia.

**ULTRASONOGRAPHIC FINDINGS**

Myxomatous mitral valve disease – Stage B1.

**INTERPRETATION OF THE FINDINGS & FURTHER RECOMMENDATIONS**

- No medication is warranted at this time.



**PATIENT**

Teddy Rogin

**SPECIES**

Canine

**BREED**

Cavalier King Charles  
Spaniel

**SEX**

Neutered Male

**AGE**

8 Years 6 Months

**WEIGHT**

30 pounds

**INTERPRETED BY**

Tam Mengine, DVM,  
DABVP (canine/feline  
practice)

**IMAGING  
PERFORMED BY**

Rebecca Hamilton

**HOSPITAL NAME**

Wyckoff Veterinary  
Hospital

**REFERRING VET**

Dr. Scott

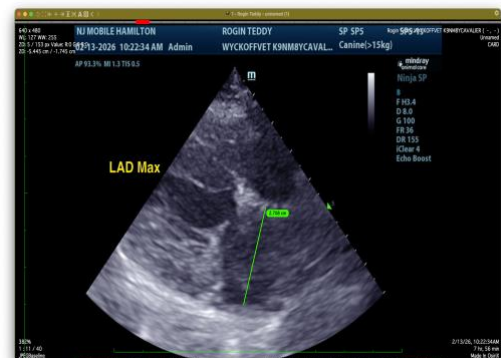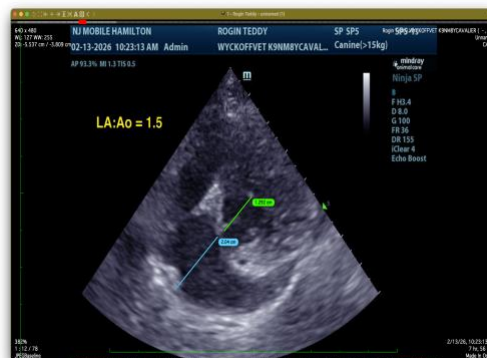
**INVOICE**

13754

**DATE**

02/13/26

- Daily monitoring of the sleeping respiratory rate at home is recommended, and if the sleeping respiratory exceeds 35 breaths per minute, then a prompt recheck physical examination and chest radiographs to assess for pulmonary edema would be warranted.
- The patient may benefit from a cardiac diet such as Purina’s “CardioCare” veterinary diet. Omega-3 Fatty acid supplementation may also be of benefit.
- Extremely vigorous exercise should be avoided, but there are no restrictions on moderate exercise, such as leash walking.
- Recheck echocardiogram is recommended in 6-8 months. MMVD is a progressive disease, and while no medication is warranted now, it may be beneficial in the future.
- If anesthesia is needed, the following recommendations are suggested:
  - Avoid a-2 agonists such as dexmedetomidine and xylazine.
  - Pre-medication with an opiate and a benzodiazepine is recommended. Additionally, Gabapentin 10mg/kg PO and trazodone 5mg/kg PO given first thing in the morning on the day of the procedure can further reduce inhalant anesthetic requirements.
  - Pre-oxygenation, followed by induction with propofol or Alfaxalone is recommended, followed by maintenance with isoflurane or sevoflurane.
  - When feasible, the use of local anesthetic blocks can decrease maintenance anesthetic requirements.
  - Moderate use of IV fluids throughout the procedure is recommended, with a starting dose of 3-5ml/kg/hr, with modest increases as needed to support blood pressure, but not to exceed a total volume of 20-30ml/kg for the procedure. The minimum volume necessary to maintain adequate blood pressure is desirable.
  - Use atropine, if necessary, to maintain a HR > 90 throughout the procedure. If available, a dopamine or dobutamine CRI can be used for additional blood pressure support if the patient experiences hypotension.





**PATIENT**

Teddy Rogin

**SPECIES**

Canine

**BREED**

Cavalier King Charles  
 Spaniel

**SEX**

Neutered Male

**AGE**

8 Years 6 Months

**WEIGHT**

30 pounds

**INTERPRETED BY**

Tam Mengine, DVM,  
 DABVP (canine/feline  
 practice)

**IMAGING  
 PERFORMED BY**

Rebecca Hamilton

**HOSPITAL NAME**

Wyckoff Veterinary  
 Hospital

**REFERRING VET**

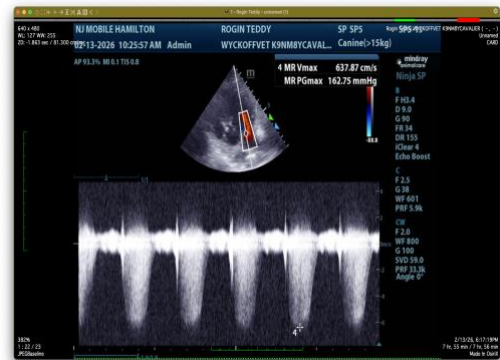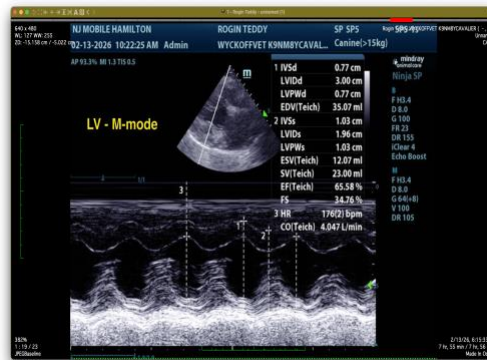
Dr. Scott

**INVOICE**

13754

**DATE**

02/13/26



The information and recommendations provided are based on the images presented by the referring veterinarian/sonographer. No evaluation can be communicated regarding pathology that was not visible in the image/video clips provided.

Thank you for this referral. If the clinical or image interpretation does not parallel your findings or if I can be of any further assistance, please contact me.

**Tam Mengine, DVM, DABVP (canine/feline practice)**

info@SonoPath.com