



**PATIENT PRESENTING CLINICAL SIGNS**

Potus Lowell History: New HM - Grade 1/6 this past spring, now Grade 2/6. No clinical signs of cardiac disease. Gabapentin for sedation.

**SPECIES**

Abnormal PE/Chem/CBC/UA Results: PE: Grade 2/6 systolic heart murmur. BW: NSF

Canine

**ULTRASONOGRAPHIC EXAMINATION OF THE HEART**

**BREED**

Chihuahua mix

**SEX**

Neutered Male

**AGE**

12

**WEIGHT**

12 lbs

**INTERPRETED BY**

Tam Mengine, DVM, DABVP (canine/feline practice)

**IMAGING PERFORMED BY**

Karen Ebersole, DVM, DABVP (Canine/Feline Practice)

**HOSPITAL NAME**

Scanvet

**REFERRING VET**

Dr. Porcelli

CANINE CARDIAC PARAMETERS	MR VMAX (m/s)	TR VMAX (m/s)	LA/AO (m-mode long axis)	LA/AO (Heart Base; Swe)	FS (%)	EF (%)	EPSS (cm)
NORMAL PARAMETER	4.5-5.5	<2.7	1.3	Up to 1.6	28-40	40-100	<0.6
PATIENT	5.3	1.3	1.2	1.1	37	69	0.3
CANINE CARDIAC PARAMETERS	HR (BPM)	AV VMAX (m/s)	PV MAX (m/s)	BODY WEIGHT (kg)	LAD LA MAX 4 Chamber	LVIDd Avg; 2D and m-mode short axis (cm)	LVIDs Avg; 2D and m-mode short axis
NORMAL PARAMETER	50-100	0.7-1.7	0.7-1.6				
PATIENT	99	1.1	1.0	5.5	2.6	2.9	1.8

**Cardiac Presentation**

The left atrium is of normal size with no evidence of spontaneous echo contrast or thrombus formation. The left ventricle is at the upper limits of normal diameter, with normal wall thickness, and demonstrates good systolic function. The right atrium is subjectively of normal size and right ventricular dimensions, and systolic function are subjectively normal. There is mild to moderate mitral valve regurgitation and mild tricuspid valve regurgitation noted, with irregular thickening of the valve leaflets and prolapse of the anterior mitral valve leaflet. There was no evidence of chordae tendineae rupture or valvular prolapse in either valve and no vegetative lesions were seen. Estimates of left ventricular filling pressures are normal (Mitral E-vel. 0.6 m/s, mitral A-vel. 0.7 m/s), and there was reversal of the E and A waves, which is an incidental finding in geriatric patients. The aortic and pulmonary valves both exhibit normal appearance and function. The main pulmonary artery appears normal. There is no evidence of pulmonary hypertension. No pericardial/pleural effusion or cardiac masses are seen. There is no evidence of an arrhythmia.

**ULTRASONOGRAPHIC FINDINGS**

Myxomatous mitral valve disease – Stage B1.

**INTERPRETATION OF THE FINDINGS & FURTHER RECOMMENDATIONS**

**INVOICE**

22233

**DATE**

12-7-25

- No cardiac medication is warranted at this time.
- Daily monitoring of the sleeping respiratory rate at home is recommended, and if the sleeping respiratory exceeds 35 breaths per minute, then a prompt recheck physical examination and chest radiographs to assess for pulmonary edema would be warranted.
- The patient may benefit from a cardiac diet such as Purina’s “CardioCare” veterinary diet. Omega-3 Fatty acid supplementation may also be of benefit.



**PATIENT**

Potus Lowell

**SPECIES**

Canine

**BREED**

Chihuahua mix

**SEX**

Neutered Male

**AGE**

12

**WEIGHT**

12 lbs

**INTERPRETED BY**

Tam Mengine, DVM,  
DABVP (canine/feline  
practice)

**IMAGING  
PERFORMED BY**

Karen Ebersole, DVM,  
DABVP (Canine/Feline  
Practice)

**HOSPITAL NAME**

Scanvet

**REFERRING VET**

Dr. Porcelli

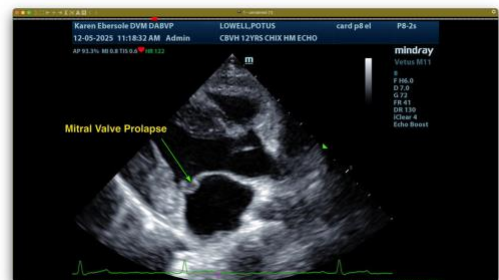
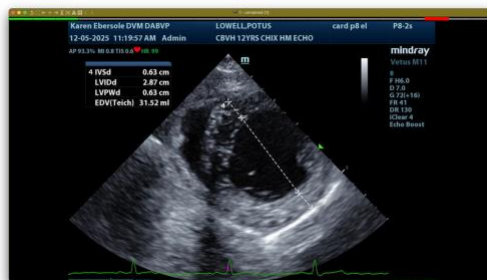
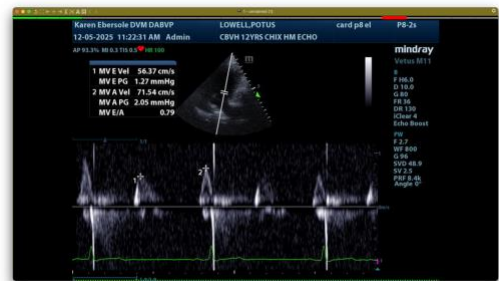
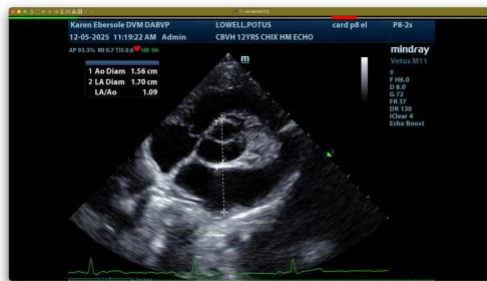
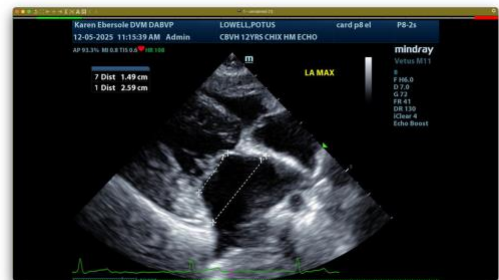
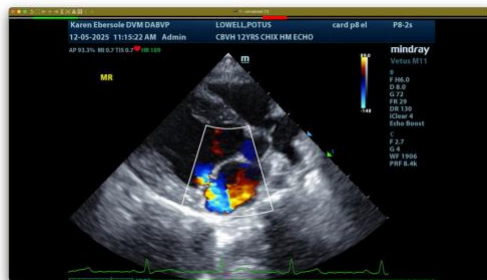
**INVOICE**

22233

**DATE**

12-7-25

- Extremely vigorous exercise should be avoided, but there are no restrictions on moderate exercise, such as leash walking.
- Recheck echocardiogram is recommended in 6-8 months. MMVD is a progressive disease, and while no medication is warranted now, it may be beneficial in the future.
- If anesthesia is needed, the following recommendations are suggested:
- Avoid a-2 agonists such as dexmedetomidine and xylazine.
- Pre-medication with an opiate and a benzodiazepine is recommended. Additionally, Gabapentin 10mg/kg PO and trazodone 5mg/kg PO given first thing in the morning on the day of the procedure can further reduce inhalant anesthetic requirements.
- Pre-oxygenation, followed by induction with propofol or alfaxalone is recommended, followed by maintenance with isoflurane or sevoflurane.
- When feasible, the use of local anesthetic blocks can decrease maintenance anesthetic requirements.
- Moderate use of IV fluids throughout the procedure is recommended, with a starting dose of 3-5ml/kg/hr, with modest increases as needed to support blood pressure, but not to exceed a total volume of 20-30ml/kg for the procedure. The minimum volume necessary to maintain adequate blood pressure is desirable.
- Use atropine, if necessary, to maintain a HR > 90 throughout the procedure. If available, a dopamine or dobutamine CRI can be used for additional blood pressure support if the patient experiences hypotension.





## PATIENT

Potus Lowell

The information and recommendations provided are based on the images presented by the referring veterinarian/sonographer. No evaluation can be communicated regarding pathology that was not visible in the image/video clips provided.

## SPECIES

Canine

Thank you for this referral. If the clinical or image interpretation does not parallel your findings or if I can be of any further assistance please contact me.

## BREED

Chihuahua mix

Tam Mengine, DVM, DABVP (canine/feline practice)  
info@SonoPath.com

## SEX

Neutered Male

## AGE

12

## WEIGHT

12 lbs

## INTERPRETED BY

Tam Mengine, DVM,  
DABVP (canine/feline  
practice)

## IMAGING PERFORMED BY

Karen Ebersole, DVM,  
DABVP (Canine/Feline  
Practice)

## HOSPITAL NAME

Scanvet

## REFERRING VET

Dr. Porcelli

## INVOICE

22233

## DATE

12-7-25