



**PATIENT PRESENTING CLINICAL SIGNS**

Johnny Colvin 4-5/6 murmur

**SPECIES ULTRASONOGRAPHIC EXAMINATION OF THE HEART**

Canine

**BREED**

Chihuahua

**SEX**

Neutered Male

**AGE**

12 Years 7 Months

**WEIGHT**

Not Provided

<b>CANINE CARDIAC PARAMETERS</b>	<b>MR VMAX (m/s)</b>	<b>TR VMAX (m/s)</b>	<b>LA/AO (m-mode long axis)</b>	<b>LA/AO (Heart Base; Swe)</b>	<b>FS (%)</b>	<b>EF (%)</b>	<b>EPSS (cm)</b>
<b>NORMAL PARAMETER</b>	4.5-5.5	<2.7	1.3	Up to 1.6	28-40	40-100	<0.6
<b>PATIENT</b>	6.0	N/A	1.3	1.3	48	NM	0.3
<b>CANINE CARDIAC PARAMETERS</b>	<b>HR (BPM)</b>	<b>AV VMAX (m/s)</b>	<b>PV MAX (m/s)</b>	<b>BODY WEIGHT (kg)</b>	<b>LAD LA MAX 4 Chamber</b>	<b>LVIDd Avg; 2D and m-mode short axis (cm)</b>	<b>LVIDs Avg; 2D and m-mode short axis (cm)</b>
<b>NORMAL PARAMETER</b>	50-100	0.7-1.7	0.7-1.6				
<b>PATIENT</b>	162	1.0	0.7	N/A	NM	2.1	1.1

**INTERPRETED BY**

Tam Mengine, DVM, DABVP (canine/feline practice)

**IMAGING PERFORMED BY**

Kerri Becker

**HOSPITAL NAME**

Sova Animal Hospital

**REFERRING VET**

Dr. Ammeraal

**INVOICE**

12596

**DATE**

12/05/25

**Cardiac Presentation**

The **left atrium** is of subjectively normal size with no evidence of spontaneous echo contrast or thrombus formation. The **left ventricle** is subjectively normal in diameter with normal wall thickness and demonstrates good systolic function. The **right atrium** is subjectively of normal size and **right ventricular** dimensions, and systolic function are subjectively normal. There is mild to moderate **mitral valve** regurgitation and no **tricuspid valve** regurgitation noted, with irregular thickening of the mitral valve leaflets. There was no evidence of chordae tendineae rupture or valvular prolapse in either valve and no vegetative lesions were seen. The **aortic** and **pulmonary valves** both exhibit normal appearance and function. The **main pulmonary artery** appears normal. There is no evidence of pulmonary hypertension. No pericardial/pleural effusion or cardiac masses are seen. There is no evidence of an arrhythmia.

**ULTRASONOGRAPHIC FINDINGS**

Myxomatous mitral valve disease – Stage B1

**INTERPRETATION OF THE FINDINGS & FURTHER RECOMMENDATIONS**

- No medication is warranted at this time.
- Daily monitoring of the sleeping respiratory rate at home is recommended, and if the sleeping respiratory exceeds 35 breaths per minute, then a prompt recheck physical examination and chest radiographs to assess for pulmonary edema would be warranted.
- The patient may benefit from a cardiac diet such as Purina’s “CardioCare” veterinary diet. Omega-3 Fatty acid supplementation may also be of benefit.



**PATIENT**

Johnny Colvin

**SPECIES**

Canine

**BREED**

Chihuahua

**SEX**

Neutered Male

**AGE**

12 Years 7 Months

**WEIGHT**

Not Provided

**INTERPRETED BY**

Tam Mengine, DVM,  
DABVP (canine/feline  
practice)

**IMAGING PERFORMED BY**

Kerri Becker

**HOSPITAL NAME**

Sova Animal Hospital

**REFERRING VET**

Dr. Ammeraal

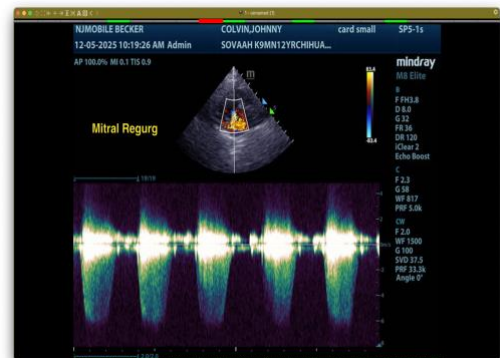
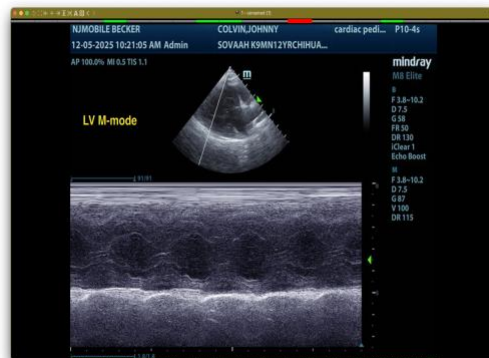
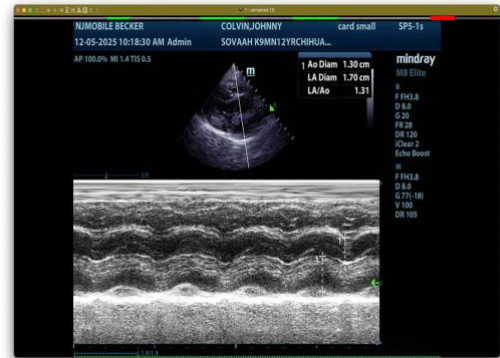
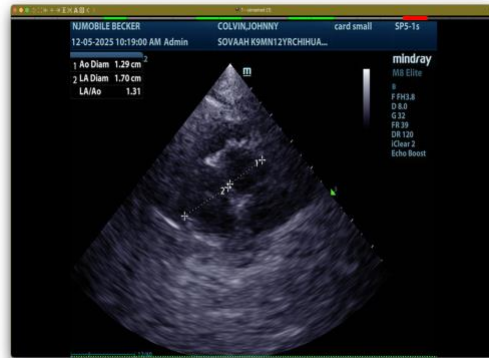**INVOICE**

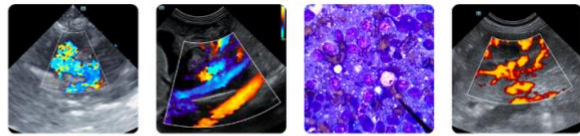
12596

**DATE**

12/05/25

- Extremely vigorous exercise should be avoided, but there are no restrictions on moderate exercise, such as leash walking.
- Recheck echocardiogram is recommended in 6-8 months. MMVD is a progressive disease, and while no medication is warranted now, it may be beneficial in the future.
- If anesthesia is needed, the following recommendations are suggested:
  - Avoid a-2 agonists such as dexmedetomidine and xylazine.
  - Pre-medication with an opiate and a benzodiazepine is recommended. Additionally, Gabapentin 10mg/kg PO and trazodone 5mg/kg PO given first thing in the morning on the day of the procedure can further reduce inhalant anesthetic requirements.
  - Pre-oxygenation, followed by induction with propofol or Alfaxalone is recommended, followed by maintenance with isoflurane or sevoflurane.
  - When feasible, the use of local anesthetic blocks can decrease maintenance anesthetic requirements.
  - Moderate use of IV fluids throughout the procedure is recommended, with a starting dose of 3-5ml/kg/hr, with modest increases as needed to support blood pressure, but not to exceed a total volume of 20-30ml/kg for the procedure. The minimum volume necessary to maintain adequate blood pressure is desirable.
  - Use atropine, if necessary, to maintain a HR > 90 throughout the procedure. If available, a dopamine or dobutamine CRI can be used for additional blood pressure support if the patient experiences hypotension.





**PATIENT**

Johnny Colvin

The information and recommendations provided are based on the images presented by the referring veterinarian/sonographer. No evaluation can be communicated regarding pathology that was not visible in the image/video clips provided.

**SPECIES**

Canine

Thank you for this referral. If the clinical or image interpretation does not parallel your findings or if I can be of any further assistance, please contact me.

**Tam Mengine, DVM, DABVP (canine/feline practice)**

**BREED**

Chihuahua

info@SonoPath.com

**SEX**

Neutered Male

**AGE**

12 Years 7 Months

**WEIGHT**

Not Provided

**INTERPRETED BY**

Tam Mengine, DVM,  
DABVP (canine/feline  
practice)

**IMAGING  
PERFORMED BY**

Kerri Becker

**HOSPITAL NAME**

Sova Animal Hospital

**REFERRING VET**

Dr. Ammeraal

**INVOICE**

12596

**DATE**

12/05/25