



## PATIENT

Zoey Sardini

## SPECIES

Canine

## BREED

Italian Greyhound

## SEX

Spayed Female

## AGE

9 Years

## WEIGHT

10 Pounds

## PRESENTING CLINICAL SIGNS

Patient presents for heart murmur (no clinical signs); needs dental under general anesthesia. No current meds. Bloods pending.

## ULTRASONOGRAPHIC EXAMINATION OF THE HEART

CANINE CARDIAC PARAMETERS	MR VMAX (m/s)	TR VMAX (m/s)	LA/AO (Boon method)	LA/AO (Heart Base; Swe)	FS (%)	EF (%)	EPSS (cm)
NORMAL PARAMETER	4.5-5.5	<2.7	1.3	<1.3	28-40	40-100	<0.6
PATIENT	5.8	1.2	NM	1.37	30%	60%	1mm
CANINE CARDIAC PARAMETERS	HR (BPM)	AV VMAX (m/s)	PV MAX (m/s)	BODY WEIGHT (kg)	LA 2D short axis Base view (cm)	LVIDd Avg; 2D and m-mode short axis (cm)	LVIDs Avg; 2D and m-mode short axis (cm)
NORMAL PARAMETER	50-100	0.7-1.7	0.7-1.6				
PATIENT	128	1.4	0.81	4.5kg	1.41	2.38	1.67

## INTERPRETED BY

Tam Mengine, DVM, DABVP (canine/feline practice)

## IMAGING PERFORMED BY

Kelly Vazquez

## HOSPITAL NAME

Parsipanny AH

## REFERRING VET

Dr. Linda Dulude

## INVOICE

18949

## DATE

12/2/22

### Cardiac Presentation

The **left atrium** is of normal size with no evidence of smoke or thrombus formation. The **left ventricle** is normal in diameter with normal wall thickness and demonstrates good systolic function. The **right atrium** is subjectively of normal size and **right ventricle** dimensions and systolic function are subjectively normal. There is mild to moderate **mitral valve** regurgitation and mild **tricuspid valve** regurgitation noted, with irregular thickening of the valve leaflets. There was no evidence of chordae tendineae rupture or valvular prolapse in either valve and no vegetative lesions were seen. The **aortic** and **pulmonary valves** both exhibit normal appearance and function. The **main pulmonary artery** appears normal. There is no evidence of pulmonary hypertension. No pericardial/pleural effusion or cardiac masses are seen. There is no evidence of an arrhythmia.

## ULTRASONOGRAPHIC FINDINGS

- Myxomatous mitral valve disease – Stage B1. Myxomatous tricuspid valve disease.

## INTERPRETATION OF THE FINDINGS & FURTHER RECOMMENDATIONS

- No medication is warranted at this time.
- Daily monitoring of the sleeping respiratory rate at home is recommended, and if the sleeping respiratory exceeds 35 breaths per minute, then a prompt recheck physical examination and chest radiographs to assess for pulmonary edema would be warranted.
- The patient may benefit from a cardiac diet such as Purina's "CardioCare" veterinary diet.
- Recheck echocardiogram is recommended in 6-8 months. MMVD is a progressive disease, and it is likely that while no medication is warranted now, it will be beneficial in the future.
- If anesthesia is needed, the following recommendations are suggested:



## PATIENT

Zoey Sardini

## SPECIES

Canine

## BREED

Italian Greyhound

## SEX

Spayed Female

## AGE

9 Years

## WEIGHT

10 Pounds

## INTERPRETED BY

Tam Mengine, DVM,  
DABVP (canine/feline  
practice)

## IMAGING PERFORMED BY

Kelly Vazquez

## HOSPITAL NAME

Parsipanny AH

## REFERRING VET

Dr. Linda Dulude

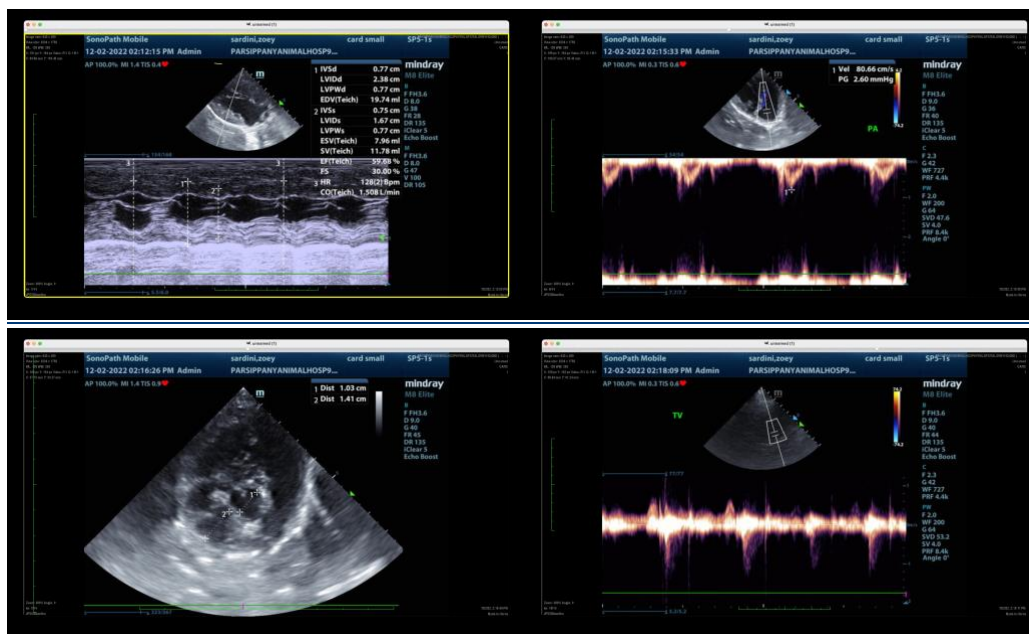
## INVOICE

18949

## DATE

12/2/22

- Avoid a-2 agonists such as dexmedetomidine and xylazine.
- Pre-medication with an opiate and a benzodiazepine is recommended (refer to . Additionally, Gabapentin 10mg/kg PO and trazodone 5mg/kg PO given first thing in the morning on the day of the procedure can further reduce inhalant anesthetic requirements.
- Pre-oxygenation, followed by induction with propofol or alfaxalone is recommended, followed by maintenance with isoflurane or sevoflurane.
- When feasible, the use of local anesthetic blocks can decrease maintenance anesthetic requirements.
- Moderate use of IV fluids throughout the procedure is recommended, with a starting dose of 3-5ml/kg/hr, with modest increases as needed to support blood pressure, but not to exceed a total volume of 20-30ml/kg for the procedure. The minimum volume necessary to maintain adequate blood pressure is desirable.
- Use atropine, if necessary, to maintain a HR > 90 throughout the procedure. If available, a dopamine or dobutamine CRI can be used for additional blood pressure support if the patient experiences hypotension.





## PATIENT

Zoey Sardini

## SPECIES

Canine

## BREED

Italian Greyhound

## SEX

Spayed Female

## AGE

9 Years

## WEIGHT

10 Pounds

## INTERPRETED BY

Tam Mengine, DVM,  
DABVP (canine/feline  
practice)

## IMAGING PERFORMED BY

Kelly Vazquez

## HOSPITAL NAME

Parsipanny AH

## REFERRING VET

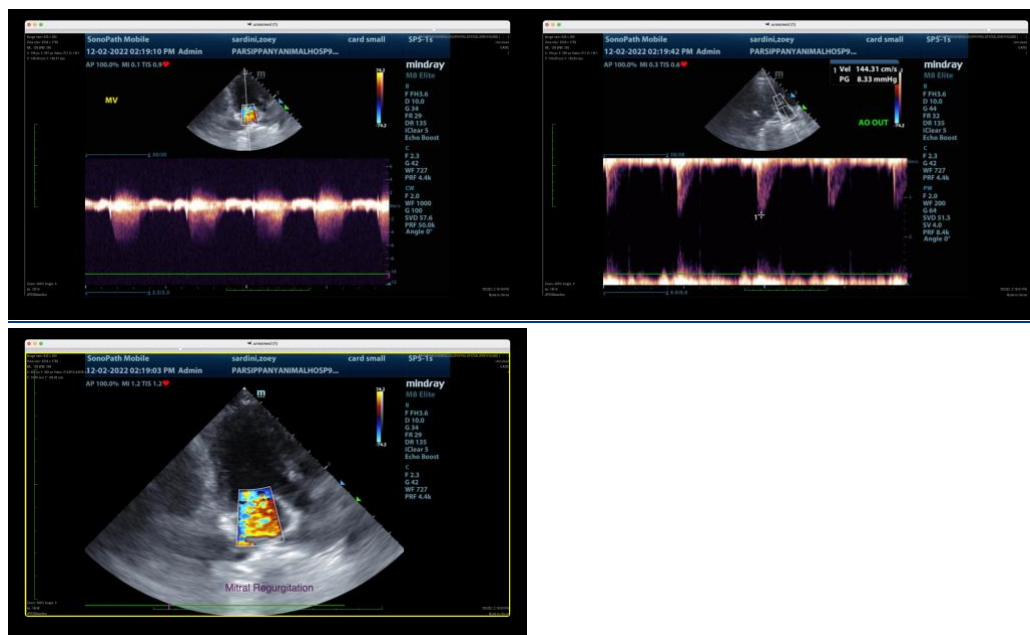
Dr. Linda Dulude

## INVOICE

18949

## DATE

12/2/22



The information and recommendations provided are based on the images presented by the referring veterinarian/sonographer. No evaluation can be communicated regarding pathology that was not visible in the image/video clips provided.

Thank you for this referral. If the clinical or image interpretation does not parallel your findings or if I can be of any further assistance please contact me.

**Tam Mengine, DVM, DABVP (canine/feline practice)**

info@SonoPath.com