



PATIENT

Doc Stevens

SPECIES

Canine

BREED

Golden Retriever

SEX

Neutered Male

AGE

9.9 Years

WEIGHT

112 Pounds

INTERPRETED BY

Tam Mengine, DVM,
DABVP (canine/feline
practice)

**IMAGING
PERFORMED BY**

Dr. Tam Mengine

HOSPITAL NAME

Stoney Creek VH

REFERRING VET

Dr. Tam Mengine

INVOICE

41471

DATE

9/20/22

PRESENTING CLINICAL SIGNS

Patient has had tenesmus recently with small stools. On rads, there is a retroperitoneal soft tissue mass - concern for prostatic neoplasia with regional lymph nodes involvement. CBC / Chem unremarkable, U/A and chest rads pending

ULTRASONOGRAPHIC EXAMINATION OF THE ABDOMEN

Urinary System

The urinary bladder is moderately distended with anechoic urine, and no luminal sediment is present. The ureteral papillae, trigone and pelvic urethra (to 3.0 cm) are of normal appearance, and the ureters are not visible (normal). No masses, calculi or mucosal irregularities are noted.

The kidneys are of normal size and shape and exhibit appropriate corticomedullary differentiation with a normal 1:3 cortex to medulla ratio. There is no evidence of nephrolithiasis, mineralization, pyelectasia, cystic change or hydronephrosis. The proximal ureter is not visible (normal). The left kidney measures 7.1 cm. The right kidney measures 7.3 cm.

Adrenal Glands

The adrenal glands are both identified in their normal locations. They are normal in size and shape with appropriate parenchymal echogenicity and normal phrenic vasculature. The left adrenal gland measures 1.2 cm cranially and 7.7 mm caudally. The right adrenal gland measures 1.1 cm cranially and 7.1 mm caudally.

Spleen

A 7.9 cm x 4.2 cm hypoechoic mass is noted at the head of the spleen, which disrupts the splenic capsule. The surrounding omentum is normal. The splenic vasculature is normal with no evidence of congestion or thrombosis, and blood flow through the splenic hilus appears normal.

Liver

The liver is of appropriate size and shape, with sharp borders and a subtly heterochoic parenchymal echotexture that is hypoechoic to the spleen. The portal and hepatic vasculature are of normal size and appearance with no evidence of congestion or thrombosis.

The gallbladder is moderately distended with anechoic contents. The wall was thin and continuous with no focal lesions. The cystic and common bile ducts are normal / not visible.

Gastrointestinal

The stomach is empty. The gastric wall is normal in thickness (5.5 mm) with normal deviations due to rugal folds, and exhibits appropriate wall layering. The pylorus is of normal appearance.

The visualized portions of the duodenum, jejunum, and ileum are of normal thickness with intact wall layering that exhibits the appropriate 1:3 muscularis to mucosa ratio. Jejunum wall measures 4.4 mm. Duodenum wall measures 5.0 mm. Intestinal motility appears normal.

The visible portions of the colon are of normal thickness (1.6 mm) with intact wall layering. The ileocecal junction is visualized.



PATIENT

Pancreas

Doc Stevens

The areas of the limbs and body of the pancreas are isoechoic to the surrounding mesenteric fat, with normal capsular appearance. There is no evidence of peripancreatic inflammation. The pancreatic duct appears normal.

SPECIES

Canine

Free Abdomen

There is no evidence of free fluid within the peritoneal cavity. The omentum and intra-abdominal fat are of appropriate echogenicity. There are several markedly enlarged lymph nodes in the region of the caudal abdomen and pelvic canal, the largest measures up to 12 cm in length. The aortic trifurcation has normal blood flow with no evidence of thrombosis.

BREED

Golden Retriever

SEX

Neutered Male

- Splenic mass
- Marked lymphadenopathy in the caudal abdomen

SECONDARY FINDINGS

AGE

9.9 Years

- Mild heterochoic change to the splenic parenchyma

INTERPRETATION OF THE FINDINGS & FURTHER RECOMMENDATIONS

The changes to the caudal abdominal lymph nodes are concerning for multicentric disease such as lymphoma. Fine needle aspiration is recommended for definitive diagnosis.

WEIGHT

112 Pounds

The splenic mass may also represent the same infiltrative process, or may be a separate disease process. Fine needle aspirate of the spleen could also be attempted for definitive diagnosis.

INTERPRETED BY

3-view chest radiographs are also recommended.

Tam Mengine, DVM,
DABVP (canine/feline
practice)

IMAGING PERFORMED BY

Dr. Tam Mengine

HOSPITAL NAME

Stoney Creek VH

REFERRING VET

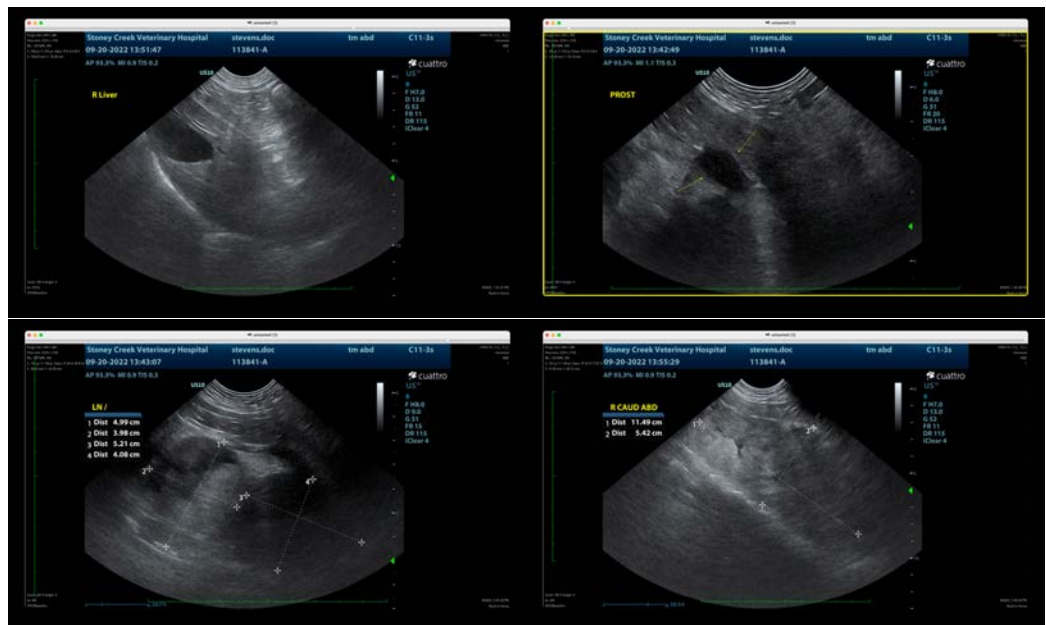
Dr. Tam Mengine

INVOICE

41471

DATE

9/20/22





PATIENT

Doc Stevens

SPECIES

Canine

BREED

Golden Retriever

SEX

Neutered Male

AGE

9.9 Years

WEIGHT

112 Pounds

INTERPRETED BY

Tam Mengine, DVM,
DABVP (canine/feline
practice)

**IMAGING
PERFORMED BY**

Dr. Tam Mengine

HOSPITAL NAME

Stoney Creek VH

REFERRING VET

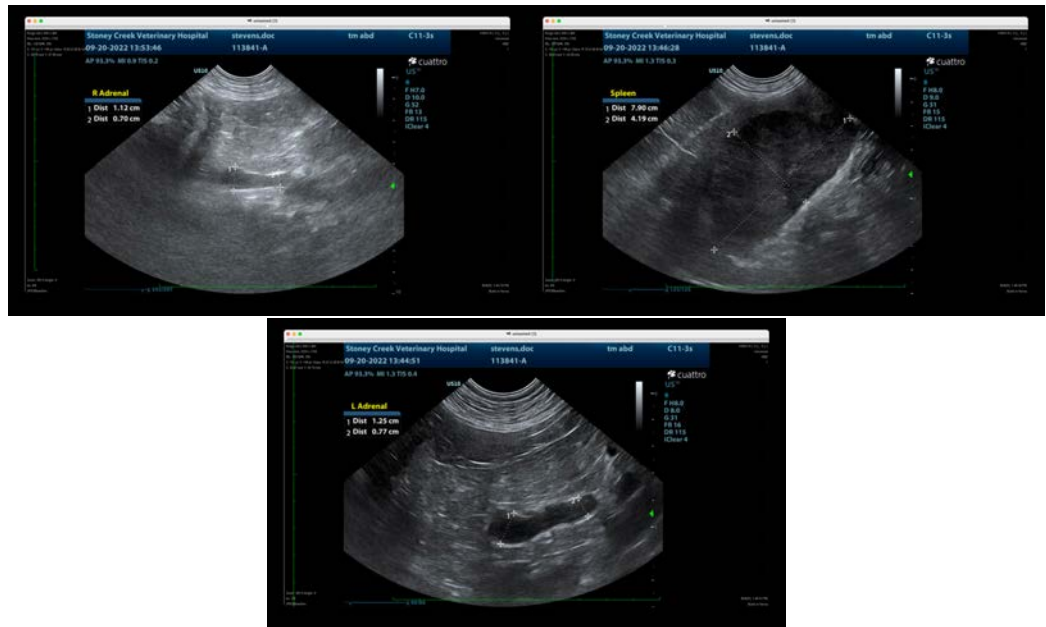
Dr. Tam Mengine

INVOICE

41471

DATE

9/20/22



The information and recommendations provided are based on the images presented by the referring veterinarian/sonographer. No evaluation can be communicated regarding pathology that was not visible in the image/video clips provided.

Thank you for this referral. If the clinical or image interpretation does not parallel your findings or if I can be of any further assistance please contact me.

Tam Mengine, DVM, DABVP (canine/feline practice)

info@SonoPath.com