



**PATIENT**

Lacey Howell

**SPECIES**

Canine

**BREED**

Coonhound

**SEX**

Spayed Female

**AGE**

11 Years

**WEIGHT**

63 Pounds

**PRESENTING CLINICAL SIGNS**

History: Prepping for anesthesia; murmur 4/6; On Amitriptylline, Vetmedin and Gabapentin  
 Abnormal PE/Chem/CBC/UA Results: EKG revealed ventricular arrhythmia

**ULTRASONOGRAPHIC EXAMINATION OF THE HEART**

CANINE CARDIAC PARAMETERS	MR VMAX (m/s)	TR VMAX (m/s)	LA/AO (Boon method)	LA/AO (Heart Base; Swe)	FS (%)	EF (%)	EPSS (cm)
NORMAL PARAMETER	4.5-5.5	<2.7	1.3	<1.3	28-40	40-100	<0.6
PATIENT	--	--	1.3	--	45%	--	NM
CANINE CARDIAC PARAMETERS	HR (BPM)	AV VMAX (m/s)	PV MAX (m/s)	BODY WEIGHT (kg)	LA 2D short axis Base view (cm)	LVIDd Avg; 2D and m-mode short axis (cm)	LVIDs Avg; 2D and m-mode short axis (cm)
NORMAL PARAMETER	50-100	0.7-1.7	0.7-1.6		1.9-3.1	34-50	20-36
PATIENT	60	--	--	28kg	2.3	4.68	2.81

**INTERPRETED BY**

Tam Mengine, DVM, DABVP (canine/feline practice)

**IMAGING PERFORMED BY**

Tasha

**HOSPITAL NAME**

Dillsburg VC

**REFERRING VET**

Dr. Crow

**INVOICE**

17358

**DATE**

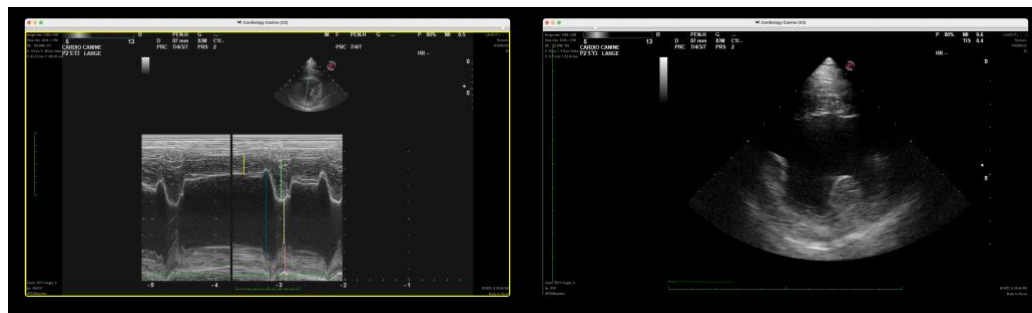
9/19/22

**Cardiac Presentation**

The left atrium has normal dimension with no evidence of smoke or thrombus formation. The left ventricle is normal in diameter with normal wall thickness. Left ventricular systolic function is adequate. Right atrial and right ventricular dimensions are subjectively normal. No pericardial/pleural effusion or cardiac masses are seen. There is evidence of an irregularly irregular arrhythmia.

**INTERPRETATION OF THE FINDINGS & FURTHER RECOMMENDATIONS**

The provided images demonstrate a heart of normal size, with adequate systolic function and no evidence of effusion, neoplasia or cardiomyopathy. Further information as to the cause of the murmur and arrhythmia may be obtained by interrogating each of the valves with color and continuous wave doppler.





**PATIENT**

Lacey Howell

**SPECIES**

Canine

**BREED**

Coonhound

**SEX**

Spayed Female

**AGE**

11 Years

**WEIGHT**

63 Pounds

**INTERPRETED BY**

Tam Mengine, DVM,  
DABVP (canine/feline  
practice)

**IMAGING  
PERFORMED BY**

Tasha

**HOSPITAL NAME**

Dillsburg VC

**REFERRING VET**

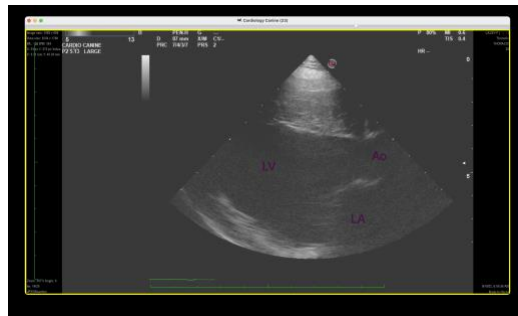Dr. Crow

**INVOICE**

17358

**DATE**

9/19/22



**The information and recommendations provided are based on the images presented by the referring veterinarian. No evaluation can be communicated regarding pathology that was not visible in the image/video clips provided.**

Thank you for this referral. If the clinical or image interpretation does not parallel your findings or if I can be of any further assistance please contact me.

**Tam Mengine, DVM, DABVP (canine/feline practice) info@SonoPath.com**