SonoPath

Clinical Sonography & Telecytology

EDUCATIONAL TELECONSULTATION SERVICES™

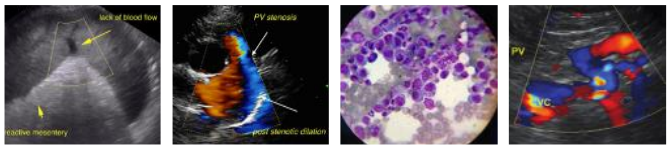

SonoPath.com™
1-800-838-4268 info@sonopath.com

PATIENT

Axel Zoldowski

SPECIES

Feline

BREED

DSH

SEX

Spayed Female

AGE

17 Years

WEIGHT

7.4 Pounds

INTERPRETED BY

Tam Mengine, DVM, DABVP (canine/feline practice)

IMAGING PERFORMED BY

Dr. Ebersole

HOSPITAL NAME

Scanvet

REFERRING VET

Dr. McGarvey

INVOICE

17330

DATE

9/16/22

PRESENTING CLINICAL SIGNS

History: Weight loss and abnormal abdominal palpation.

Abnormal PE/Chem/CBC/UA Results: RADS (attached): abnormal tissue opacity next to spleen, ground glass appearance to abdomen. CBC/Chem/T-4 (6/25/22): Monocytosis, all else WNL UA (6/25/22, free catch): SG 1.035, Bld 1+. Sed: WBC 50-75/HPF, RBC 20-30/HPF.

ULTRASONOGRAPHIC EXAMINATION OF THE ABDOMEN

Urinary System

The urinary bladder is moderately distended with anechoic urine, and no luminal sediment is present. The ureteral papillae, trigone and pelvic urethra are of normal appearance, and the ureters are not visible (normal). No masses, calculi or mucosal irregularities are noted. Urethra visualized to 2.0 cm.

Both kidneys are hyperechoic and exhibit mildly decreased cortico-medullary differentiation. There is no evidence of nephrolithiasis, mineralization, pyelectasia or hydronephrosis. The proximal ureter is not visible (normal). The left kidney is 3.8 cm in length. The right kidney is 3.5 cm in length.

Adrenal Glands

The left adrenal gland is identified in its normal locations. It is normal in size and shape with appropriate parenchymal echogenicity and normal phrenic vasculature. The left adrenal gland height is 4.8 mm.

The right adrenal gland is not distinctly visualized but the region appears within normal limits.

Spleen

The spleen is diffusely thickened, measuring 1.7 cm at the hilus. The capsular margins are irregular and scalloped and the parenchyma is mottled. The splenic vasculature is normal with no evidence of congestion or thrombosis, and blood flow through the splenic hilus appears normal.

Liver

The liver is diffusely hyperechoic, with rounded margins, and is subjectively enlarged. The portal and hepatic vasculature are of normal size and appearance with no evidence of congestion or thrombosis.

The gallbladder is moderately distended with anechoic contents. The wall was thin and continuous with no focal lesions. The cystic and common bile ducts are normal / not visible.

Gastrointestinal

The stomach is empty. The gastric wall is 2.2 mm with normal deviations due to rugal folds, and exhibits appropriate wall layering. The pylorus is of normal appearance.

The small bowel has focal changes to the normal 1:3 muscularis to mucosa ratio. Wall measurements are increased up to 3.6 mm. Overall wall layering is preserved.

The visible portions of the colon are of normal thickness, with intact wall layering. The ileocecal junction is visualized and normal.

Pancreas

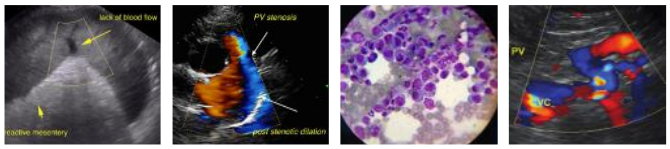

SonoPath.com
1-800-838-4268 info@sonopath.com

PATIENT

Axel Zoldowski

SPECIES

Feline

BREED

DSH

SEX

Spayed Female

AGE

17 Years

WEIGHT

7.4 Pounds

INTERPRETED BY

Tam Mengine, DVM, DABVP (canine/feline practice)

IMAGING PERFORMED BY

Dr. Ebersole

HOSPITAL NAME

Scanvet

REFERRING VET

Dr. McGarvey

INVOICE

17330

DATE

9/16/22

The areas of the limbs and body of the pancreas are isoechoic to the surrounding mesenteric fat, with normal capsular appearance. There is no evidence of peripancreatic inflammation. The pancreatic duct appears normal.

Free Abdomen

There is focal free fluid present with the abdomen. The omentum and intra-abdominal fat are hyperechoic. The hepatic and splenic lymph nodes were moderately enlarged, up to 1.3 cm, with normal short to long axis ratio and appropriate echogenicity. The aortic trifurcation has normal blood flow with no evidence of thrombosis.

ULTRASONOGRAPHIC FINDINGS

Primary Findings

- A diffusely enlarged and mottled spleen
- A diffusely enlarged liver
- A moderate amount of free fluid throughout the abdomen

Secondary Findings

- Chronic renal changes

INTERPRETATION OF THE FINDINGS & FURTHER RECOMMENDATIONS

The changes within the spleen and liver are consistent with infiltrative neoplasia, most likely lymphoma or possibly systemic mast cell disease. Ultrasound guided fine needle aspiration with a 25-gauge needle is recommended for a definitive diagnosis. The poor detail noted on the attached abdominal radiographs is due to the presence of the fluid throughout the abdomen.

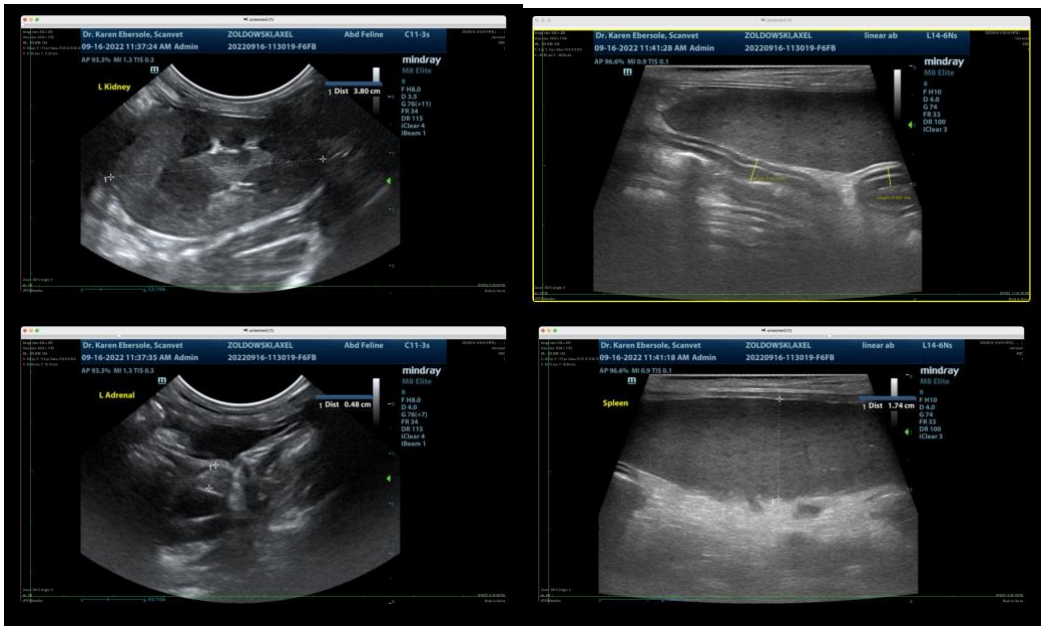

SonoPath

Clinical Sonography & Telecytology

EDUCATIONAL TELECONSULTATION SERVICES™

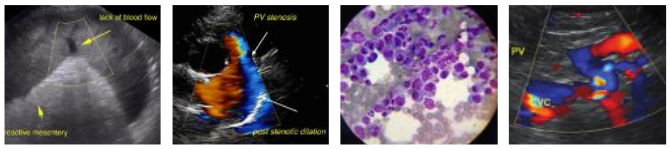

SonoPath.com
1-800-838-4268 info@sonopath.com

PATIENT

Axel Zoldowski

SPECIES

Feline

BREED

DSH

SEX

Spayed Female

AGE

17 Years

WEIGHT

7.4 Pounds

INTERPRETED BY

Tam Mengine, DVM, DABVP (canine/feline practice)

IMAGING PERFORMED BY

Dr. Ebersole

HOSPITAL NAME

Scanvet

REFERRING VET

Dr. McGarvey

INVOICE

17330

DATE

9/16/22

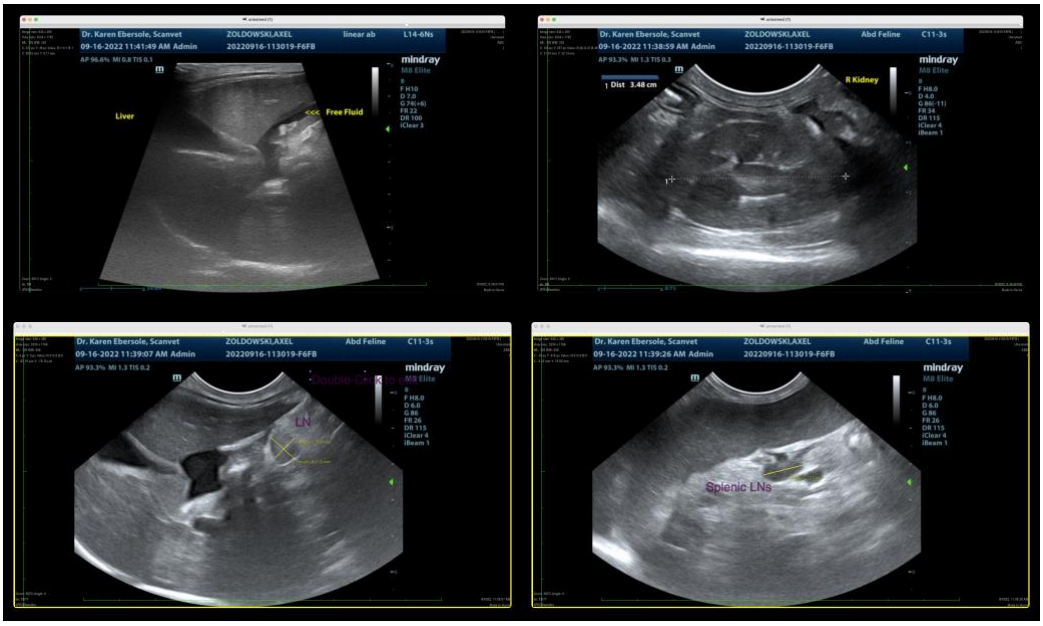

The information and recommendations provided are based on the images presented by the referring veterinarian. No evaluation can be communicated regarding pathology that was not visible in the image/video clips provided.

Thank you for this referral. If the clinical or image interpretation does not parallel your findings or if I can be of any further assistance please contact me.

Tam Mengine, DVM, DABVP (canine/feline practice) info@SonoPath.com