

PATIENT PRESENTING CLINICAL SIGNS

Hatty Webb

SPECIES

Canine

BREED

Lab

SEX

Spayed Female

AGE

1 Year

WEIGHT

21.6 kg

INTERPRETED BY

Tam Mengine, DVM,
DABVP (canine/feline
practice)

IMAGING PERFORMED BY

Kelly Reschny

HOSPITAL NAME

East Plains AH

REFERRING VET

Dr. Cumming

INVOICE

44798

DATE

8/18/23

Owner reports that Tuesday night Hatty was whining in her crate a lot but had been eating well all day with no v/d. Wednesday morning started with liquidy diarrhea at 3am - gravy like consistency. Thursday ate breakfast and lunch fine but still had watery brown diarrhea. Also found a very large pile of vomit that was mostly food but had an entire ear/antler of a moose stuffed toy in it! owners said it smelt very foul. Since finding the vomit she had 4-5 more episodes of projectile watery vomits and was retching - seemed to happen after food and water. Lethargic all afternoon, and owners did not offer her dinner. Went to emergency in kitchener last night - was found to be dull with a high normal temp at 39.5 - abdomen was soft with no obvious pain last night. Owners were offered rads and suggested ultrasound (however they could not get one at emerg last night). Owners declined rads - was given 500mls of sub q fluid and a dose of cerenia at 9pm last night. Also sent home with metronidazole which owners have not started, as she has not had any further diarrhea or a BM at all. comfortable for abdominal palpation today. No pain response or obvious palpable mass/FB or organ change noted. No palpable stool. 3 view abdominal radiographs taken today. Moderate amount of gas in the colon and similarly in distal small intestinal tract. Radiopaque material noted on V/D in distal colon at the exit point - rock? metallic material? No obvious foreign material noted on lateral or V/D rads otherwise, however gas in stomach and SI is difficult to interpret in light of history of dull clinical presentation.

Abnormal PE/Chem/CBC/UA Results: Moderate amount of gas in the colon and similarly in distal small intestinal tract. Radiopaque material noted on V/D in distal colon at the exit point - rock? metallic material? No obvious foreign material noted on lateral or V/D rads otherwise, however gas in stomach and SI is difficult to interpret in light of history of dull clinical presentation.

ULTRASONOGRAPHIC EXAMINATION OF THE ABDOMEN

Urinary System

The urinary bladder is moderately distended with anechoic urine, and no luminal sediment is present. The ureteral papillae, trigone and pelvic urethra (visible to 3.0 cm) are of normal appearance, and the ureters are not visible (normal). No masses, calculi or mucosal irregularities are noted.

The kidneys are of normal size and shape and exhibit appropriate corticomedullary differentiation with a normal 1:3 cortex to medulla ratio. There is no evidence of nephrolithiasis, mineralization, pyelectasia, cystic change or hydronephrosis. The proximal ureter is not visible (normal). The left kidney measured 5.9 cm. The right kidney measured 6.9 cm.

Adrenal Glands

The adrenal glands are both identified in their normal locations. They are normal in size and shape with appropriate parenchymal echogenicity and normal phrenic vasculature. The left adrenal gland measured 7.4 mm at the cranial pole and 6.4 mm at the caudal pole. The right adrenal gland measured 7.1 mm at the cranial pole and 7.2 mm at the caudal pole.

Spleen

The spleen is of appropriate size and has a normal, homogenous parenchyma with a smooth, continuous capsular surface. The splenic vasculature is normal with no evidence of congestion or thrombosis, and blood flow through the splenic hilus appears normal.



PATIENT *Liver*

Hatty Webb The liver is of appropriate size and shape, with sharp borders and a mildly coarse parenchymal echotexture that is hypoechoic to the spleen. The portal and hepatic vasculature are of normal size and appearance with no evidence of congestion or thrombosis.

SPECIES

Canine The gallbladder is moderately distended with anechoic contents. The wall was thin and continuous with no focal lesions. The cystic and common bile ducts are normal / not visible.

BREED

Lab

Gastrointestinal

SEX

The stomach is moderately distended with hypoechoic fluid and gas. The gastric wall is 4.7 mm in thickness with normal deviations due to rugal folds and exhibits appropriate wall layering. The pylorus is of normal appearance.

Spayed Female

AGE

The visualized portions of the duodenum, jejunum, and ileum are of normal thickness with intact wall layering that exhibits the appropriate 1:3 muscularis to mucosa ratio. There are focally distended loops of small bowel containing hypoechoic fluid, and no apparent foreign body nor evidence of obstruction. The jejunal wall measures up to 3.8 mm. Intestinal motility appears normal.

1 Year

WEIGHT

The visible portions of the colon are of normal thickness (1.6 mm) with intact wall layering. The ileocecal junction is visualized and normal.

21.6 kg

Pancreas

INTERPRETED BY

The areas of the limbs and body of the pancreas are isoechoic to the surrounding mesenteric fat, with normal capsular appearance. There is no evidence of peripancreatic inflammation. The pancreatic duct appears normal.

Tam Mengine, DVM,
DABVP (canine/feline
practice)

Free Abdomen

IMAGING PERFORMED BY

There is no evidence of free fluid within the peritoneal cavity. The mesenteric lymph nodes were moderately enlarged, up to 2.2 cm with normal short to long axis ratio and appropriate echogenicity. The aortic trifurcation has normal blood flow with no evidence of thrombosis.

Kelly Reschny

HOSPITAL NAME

PRIMARY FINDINGS

East Plains AH

- Focally fluid distended loops of bowel with no evidence of obstruction
- Reactive mesenteric lymph nodes

REFERRING VET

INTERPRETATION OF THE FINDINGS & FURTHER RECOMMENDATIONS

Dr. Cumming

The changes in the small intestinal tract are consistent with gastroenteritis. There is visible foreign body noted on today's ultrasound, nor evidence of intestinal obstruction. Additional recommendations include:

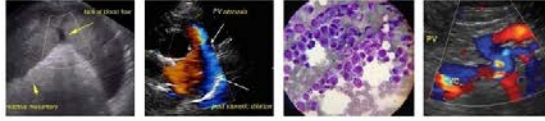
INVOICE

44798

- ❖ fecal parasite testing and empiric fenbendazole treatment
- ❖ probiotic therapy
- ❖ bland diet
- ❖ treatment with parenteral fluids, antiemetics, antacids and gastroprotectants as clinically indicated.

DATE

8/18/23



PATIENT

Hatty Webb

SPECIES

Canine

BREED

Lab

SEX

Spayed Female

AGE

1 Year

WEIGHT

21.6 kg

INTERPRETED BY

Tam Mengine, DVM,
DABVP (canine/feline
practice)

**IMAGING
PERFORMED BY**

Kelly Reschny

HOSPITAL NAME

East Plains AH

REFERRING VET

Dr. Cumming

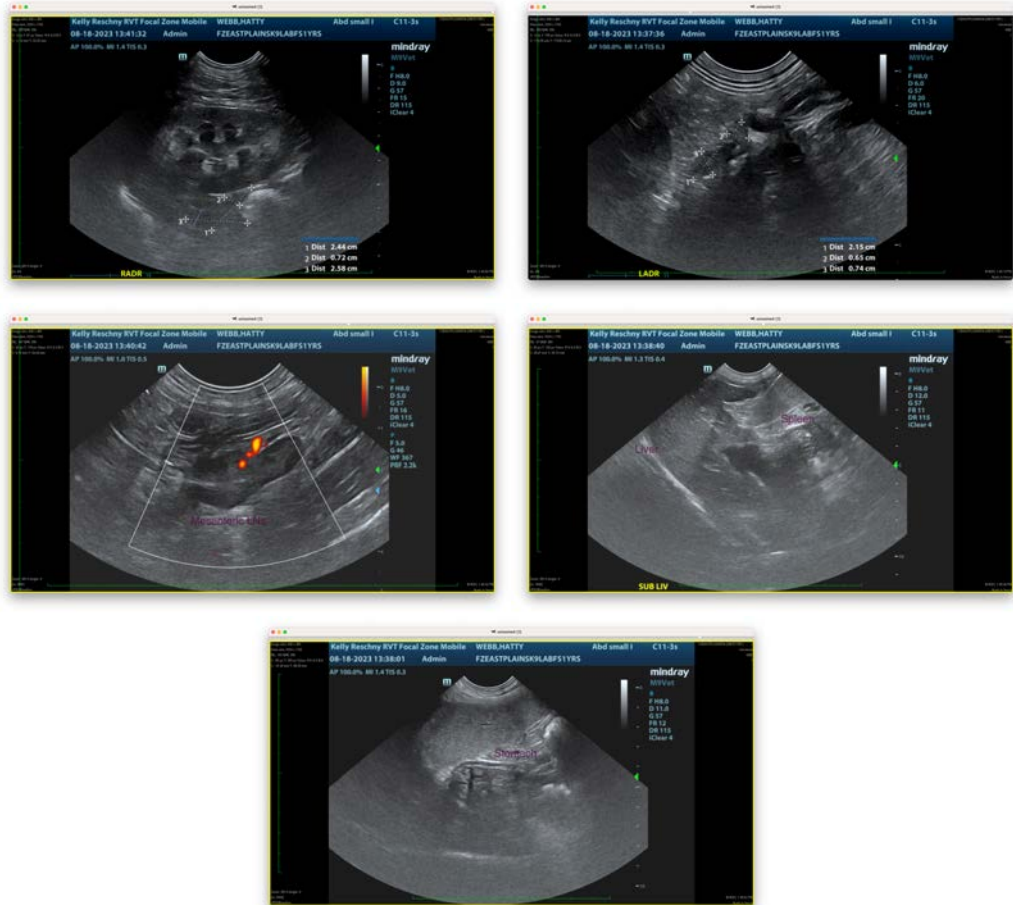
INVOICE

44798

DATE

8/18/23

- ❖ If signs persist, trials with a novel protein or hydrolyzed diet, a resting cortisol level and a GI panel could be considered.



The information and recommendations provided are based on the images presented by the referring veterinarian/sonographer. No evaluation can be communicated regarding pathology that was not visible in the image/video clips provided.

Thank you for this referral. If the clinical or image interpretation does not parallel your findings or if I can be of any further assistance please contact me.

Tam Mengine, DVM, DABVP (canine/feline practice)

info@SonoPath.com