SonoPath
Clinical Sonography & Telecytology

EDUCATIONAL TELECONSULTATION SERVICES™

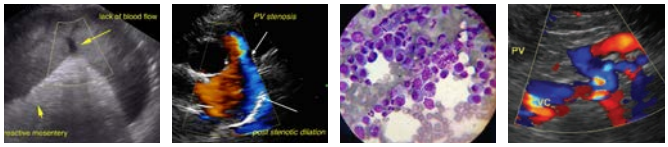

SonoPath.com™
1-800-838-4268 info@sonopath.com

PATIENT
Susy Caceres

SPECIES
Canine

BREED
Coton de Tulear

SEX
Female

AGE
3 Years

WEIGHT
17.6 Pounds

INTERPRETED BY
Tam Mengine, DVM, DABVP (canine/feline practice)

IMAGING PERFORMED BY
Dr. Rachel Wiley

HOSPITAL NAME
Petvacx AH

REFERRING VET
Dr. Rachel Wiley

INVOICE
39995

DATE
8/1/22

PRESENTING CLINICAL SIGNS

Whelped 6 months ago, retained placenta at that time, p had been ADR since then, on and off large bowel diarrhea and vomiting, lethargy.
Abnormal PE/Chem/CBC/UA Results: Current labs are Pending, 2 months ago all Within Normal Limits except mild Leukocytosis characterized by mature neutrophilia

ULTRASONOGRAPHIC EXAMINATION OF THE ABDOMEN

Urinary System

The urinary bladder is minimally distended with anechoic urine, and no luminal sediment is present. The ureteral papillae, trigone and pelvic urethra are of normal appearance, and the ureters are not visible (normal). No masses, calculi or mucosal irregularities are noted. The pelvic urethra is visualized to 1.0 cm.

The kidneys are of normal size and shape and exhibit appropriate corticomedullary differentiation with a normal 1:3 cortex to medulla ratio. There is no evidence of nephrolithiasis, mineralization, pyelectasia, cystic change or hydronephrosis. The proximal ureter is not visible (normal). The left kidney measures 4.5 cm. The right kidney measures 5.1 cm.

Adrenal Glands

The adrenal glands are both identified in their normal locations. They are normal in size and shape with appropriate parenchymal echogenicity and normal phrenic vasculature. The left adrenal gland measures 4.9 mm at the cranial pole and 3.5 mm at the caudal pole. The right adrenal gland measured 4.8 mm at the cranial pole and 3.1 mm at the caudal pole.

Spleen

The spleen is of appropriate size and has a normal, homogenous parenchyma with a smooth, continuous capsular surface. The splenic vasculature is normal with no evidence of congestion or thrombosis, and blood flow through the splenic hilus appears normal.

Liver

The liver is of appropriate size and shape, with sharp borders and a mildly coarse parenchymal echotexture that is hypoechoic to the spleen. The portal and hepatic vasculature are of normal size and appearance with no evidence of congestion or thrombosis.

The gallbladder is moderately distended with anechoic contents. The wall was thin and continuous with no focal lesions. The cystic and common bile ducts are normal / not visible.

Gastrointestinal

The stomach is empty. The gastric wall is normal (2.8 mm thick) with deviations due to rugal folds, and exhibits appropriate wall layering. The pylorus is of normal appearance.

The visualized portions of the duodenum, jejunum, and ileum are of normal thickness with intact wall layering that exhibits the appropriate 1:3 muscularis to mucosa ratio. Intestinal motility appears normal. The jejunum wall measures up to 2.9 mm. The duodenum wall measures up to 4.1 mm.

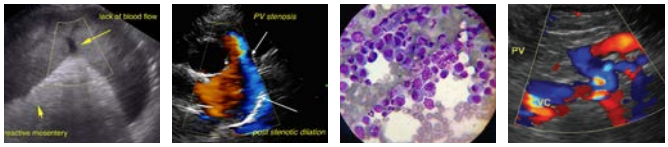

SonoPath.com
1-800-838-4268 info@sonopath.com

PATIENT

Susy Caceres

SPECIES

Canine

BREED

Coton de Tulear

SEX

Female

AGE

3 Years

WEIGHT

17.6 Pounds

INTERPRETED BY

Tam Mengine, DVM, DABVP (canine/feline practice)

IMAGING PERFORMED BY

Dr. Rachel Wiley

HOSPITAL NAME

Petvacx AH

REFERRING VET

Dr. Rachel Wiley

INVOICE

39995

DATE

8/1/22

The visible portions of the colon are of normal thickness (2.1 mm) with intact wall layering. The ileocecal junction is visualized and appears normal.

Pancreas

The areas of the limbs and body of the pancreas are isoechoic to the surrounding mesenteric fat, with normal capsular appearance. There is no evidence of peripancreatic inflammation. The pancreatic duct appears normal.

Free Abdomen

The uterus is visualized. Both the body and horns are devoid of free fluid or mucosal irregularities, consistent with a normal anestrus uterus.

There is no evidence of free fluid within the peritoneal cavity. The omentum and intra-abdominal fat are of appropriate echogenicity. Enlarged abdominal lymph nodes are not observed. The aortic trifurcation has normal blood flow with no evidence of thrombosis.

ULTRASONOGRAPHIC FINDINGS

- Normal abdomen and normal anestrus uterus

INTERPRETATION OF THE FINDINGS & FURTHER RECOMMENDATIONS

A definitive cause for the vomiting and diarrhea is not found. Additional diagnostic considerations include a fecal parasite check, gastrointestinal panel, and a resting cortisol level, should a cause for the symptoms not be found in the pending lab work. Empirical treatment could be attempted with either a bland or novel diet, such as a hydrolyzed protein diet, a Fenbendazole trial, and probiotic therapy. If available, my preference for probiotic is the Visbiome Vet High Potency probiotic.

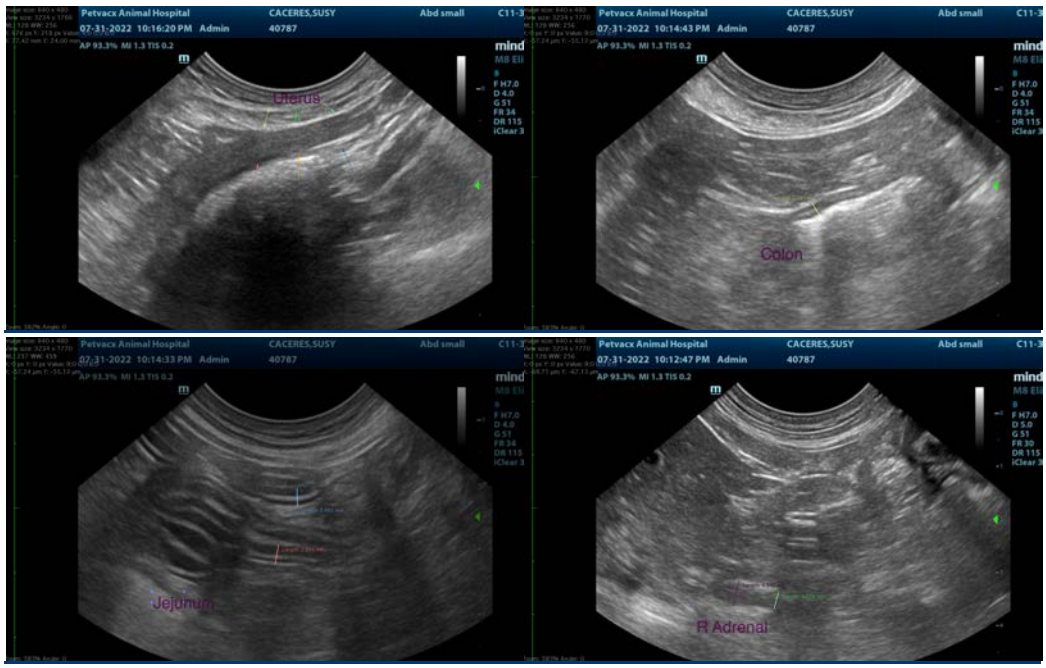

SonoPath

Clinical Sonography & Telecytology

EDUCATIONAL TELECONSULTATION SERVICES™

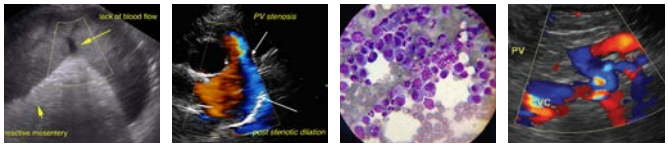

SonoPath.com™

1-800-838-4268 info@sonopath.com

PATIENT

Susy Caceres

SPECIES

Canine

BREED

Coton de Tulear

SEX

Female

AGE

3 Years

WEIGHT

17.6 Pounds

INTERPRETED BY

Tam Mengine, DVM, DABVP (canine/feline practice)

IMAGING PERFORMED BY

Dr. Rachel Wiley

HOSPITAL NAME

Petvacx AH

REFERRING VET

Dr. Rachel Wiley

INVOICE

39995

DATE

8/1/22

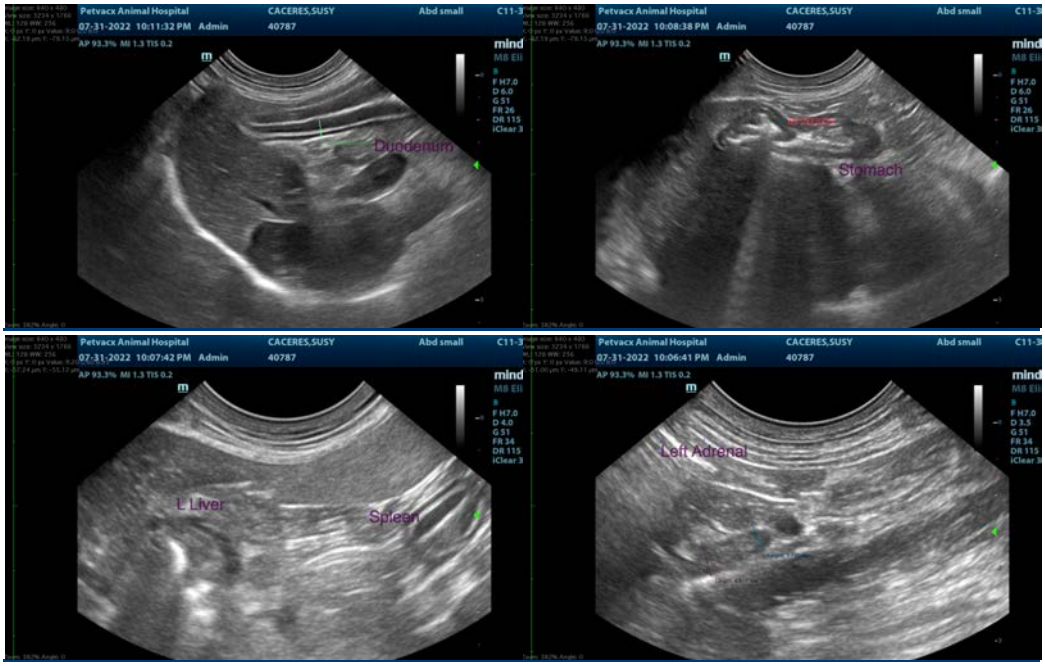

The information and recommendations provided are based on the images presented by the referring veterinarian/sonographer. No evaluation can be communicated regarding pathology that was not visible in the image/video clips provided.

Thank you for this referral. If the clinical or image interpretation does not parallel your findings or if I can be of any further assistance please contact me.

Tam Mengine, DVM, DABVP (canine/feline practice)

info@SonoPath.com