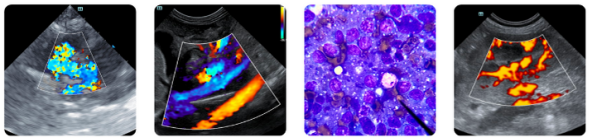

PATIENT
Silvia Cannici

SPECIES
Canine

BREED
Boxer x

SEX
Spayed Female

AGE
12 Years

WEIGHT
50 lbs

INTERPRETED BY
Tam Mengine, DVM, DABVP (canine/feline practice)

IMAGING PERFORMED BY
Claudia Hernandez

HOSPITAL NAME
All Creatures Great & Small (Denville)

REFERRING VET
Dr. Silas Ashmore

INVOICE
75186

DATE
5/16/26

PRESENTING CLINICAL SIGNS

Not eating, Bloated abdomen, lethargic, painful abdomen.
Abnormal PE/Chem/CBC/UA Results: Anemia non regenerative. Low PLT count

ULTRASONOGRAPHIC EXAMINATION OF THE ABDOMEN

Urinary System

The urinary bladder is moderately distended with anechoic urine, and no luminal sediment is present. The ureteral papillae and trigone are of normal appearance, and the ureters are not visible (normal). No masses, calculi or mucosal irregularities are noted. The urethra is not visualized, presumably due to a an intrapelvic location.

The left kidney is of normal size (5.3 cm) and shape and exhibits appropriate corticomedullary differentiation with a normal 1:3 cortex to medulla ratio. There is no evidence of nephrolithiasis, mineralization, pyelectasia, cystic change or hydronephrosis. The proximal ureter is not visible (normal).

The right kidney is not visualized in the image set provided.

Adrenal Glands

The adrenal glands are not distinctly visualized, but the regions appear unremarkable.

Spleen

There is a 3.6 cm x 2.2 cm heterogeneous mass located in the body of the spleen, which disrupts the splenic capsule. Surrounding omentum is hyperechoic.

Liver

The liver and gallbladder are not see in the image set provided.

Gastrointestinal

The stomach is mildly distended with ingesta. The gastric wall is 2.3 mm with normal deviations due to rugal folds, and exhibits appropriate wall layering. The pylorus is of normal appearance.

The visualized portions of the duodenum, jejunum, and ileum are of normal thickness with intact wall layering that exhibits the appropriate 1:3 muscularis to mucosa ratio. Intestinal motility appears normal.

The visible portions of the colon are of normal thickness (1.4 mm) with intact wall layering. The ileocecal junction is not seen.

Pancreas

The areas of the limbs and body of the pancreas are isoechoic to the surrounding mesenteric fat, with normal capsular appearance. There is no evidence of peripancreatic inflammation. The pancreatic duct appears normal.

Free Abdomen

There is focal free fluid present with the abdomen in the region of the spleen and caudal abdomen. The omentum and intra-abdominal fat are of appropriate echogenicity. Enlarged abdominal lymph nodes are not observed. The aortic trifurcation has normal blood flow with no evidence of thrombosis.

PATIENT
Silvia Cannici

SPECIES
Canine

BREED
Boxer x

SEX
Spayed Female

AGE
12 Years

WEIGHT
50 lbs

INTERPRETED BY
Tam Mengine, DVM, DABVP (canine/feline practice)

IMAGING PERFORMED BY
Claudia Hernandez

HOSPITAL NAME
All Creatures Great & Small (Denville)

REFERRING VET
Dr. Silas Ashmore

INVOICE
75186

DATE
5/16/26

PRIMARY FINDINGS

- Heterogeneous splenic mass, with inhomogeneous splenic parenchyma and irregular splenic margins
- Moderate amount of echogenic fluid, concerning for hemoabdomen.

INTERPRETATION OF THE FINDINGS & FURTHER RECOMMENDATIONS

The sonographic findings and clinical history are concerning for a hemoabdomen secondary to a splenic mass. Some portions of the abdomen (liver and right retroperitoneal region) were not available for review at the time of initial submission. The following next steps are recommended:

1. Abdominocentesis to determine whether the patient has a hemoabdomen, vs other type of effusion
2. 3-view chest radiographs
3. Ideally, we would assess the liver for evidence of metastasis - of note, however, a recent study of patients with splenic masses found that the sonographic presence of liver nodules correlated poorly with actual metastatic lesions.
4. If chest radiographs are clear, then abdominal exploratory would be the recommended next step, or alternatively, palliative care with Yunnan bai Yao, or euthanasia would be considerations.

Reference: **Ramirez, A. R., Stewart, S. D., & Khanna, C. (2024). Ultrasonographic liver nodules are more often benign lesions in dogs with hemoperitoneum secondary to splenic tumor rupture. *Journal of the American Veterinary Medical Association*, *262*(11), 1499-1503.**

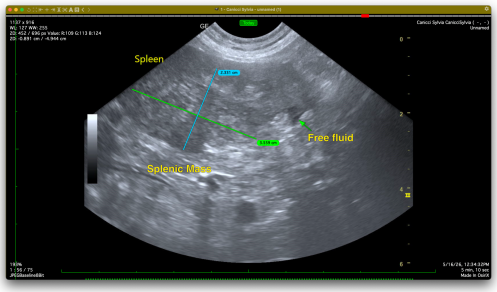

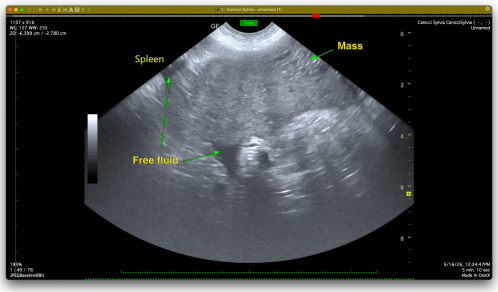

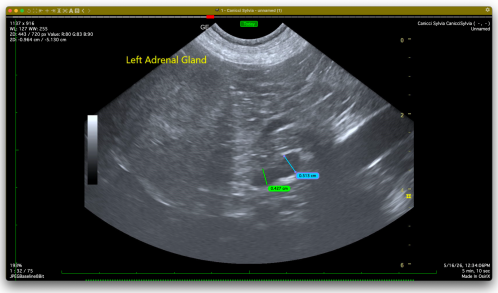

SonoPath
FOSTERING THE ART OF VETERINARY MEDICINE™

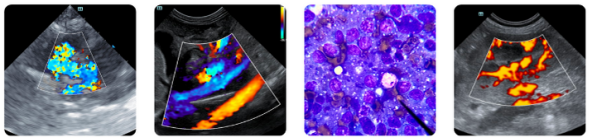

Clinical Sonography & Telecytology
Educational Teleconsultation Services™

SonoPath.com *info@sonopath.com* *1.800.838.4268*

PATIENT

Silvia Cannici

SPECIES

Canine

BREED

Boxer x

SEX

Spayed Female

AGE

12 Years

WEIGHT

50 lbs

INTERPRETED BY

Tam Mengine, DVM, DABVP (canine/feline practice)

IMAGING PERFORMED BY

Claudia Hernandez

HOSPITAL NAME

All Creatures Great & Small (Denville)

REFERRING VET

Dr. Silas Ashmore

INVOICE

75186

DATE

5/16/26

The information and recommendations provided are based on the images presented by the referring veterinarian/sonographer. No evaluation can be communicated regarding pathology that was not visible in the image/video clips provided.

Thank you for this referral. If the clinical or image interpretation does not parallel your findings or if I can be of any further assistance please contact me.

Tam Mengine, DVM, DABVP (canine/feline practice)

info@SonoPath.com