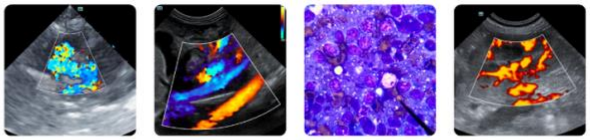

PATIENT
Rocky Laidler

SPECIES
Feline

BREED
DLH

SEX
Neutered Male

AGE
2 Years

WEIGHT
5.38 kg

INTERPRETED BY
Tam Mengine, DVM, DABVP (canine/feline practice)

IMAGING PERFORMED BY
Lindsay Powell CVT

HOSPITAL NAME
Hershey Animal Emergency Center

REFERRING VET
Dr. Brittany Lang

INVOICE
14861

DATE
04/04/26

PRESENTING CLINICAL SIGNS

Presented for acute onset vomiting 4/3 around 10:30am. Known to lick/chew on plastic bags but nothing noted missing from the home. Patient has been hospitalized since then. PE: 5-6% dehydrated, dull, tense/painful abdomen, hypersalivation. 4/3 Intake CBC - HGB 16.9 (H), RDW 27.4 (H), Neut 11.7 (H), Eos 0.01 (L) Invue - Neut 13.3 (H), Lymph 0.18 (L), Eos 0.06 (L) EPOC - BE -5.2 (L), K 3.0 (L), Ca 1.17 (L), Glu 260 (H), HCT 52 (H) PCV/TP - 51/7.2

Abnormal PE/Chem/CBC/UA Results: Abd rads - markedly distended SI tract with fluid-like material compatible with severe functional ileus-enteritis/gastroenteritis, aboral mechanical obstruction is also considered likely following the degree of intestinal distention [border effaced foreign material, intussusception]. Gastric content is nonspecific. It could represent normal ingesta or mixed foreign material without causing complete outflow obstruction. Mild right renal changes: Correlate with the renal blood parameters to assess significance. Rechk abd rads- no evidence of foreign material in the stomach. There is persistent mild dilation throughout the SI. As the patient is reportedly improving clinically, this is therefore most likely suggestive of an initial functional ileus/non-specific gastroenteropathy

ULTRASONOGRAPHIC EXAMINATION OF THE ABDOMEN

Urinary System

The urinary bladder is mildly distended with anechoic urine, and no luminal sediment is present. The ureteral papillae, trigone and pelvic urethra (visible to 2.0 cm) are of normal appearance, and the ureters are not visible (normal). No masses, calculi or mucosal irregularities are noted.

The kidneys are of normal size and shape and exhibit appropriate corticomedullary differentiation with a normal 1:3 cortex to medulla ratio. There is no evidence of nephrolithiasis, mineralization, pyelectasia, cystic change or hydronephrosis. The proximal ureter is not visible (normal). The left kidney measured 4.4 cm in length. The right kidney measured 4.5 cm in length.

Adrenal Glands

The adrenal glands are both identified in their normal locations. They are normal in size and shape with appropriate parenchymal echogenicity and normal phrenic vasculature. The left adrenal gland measured 4.7 mm. The right adrenal gland measured 4.2 mm.

Spleen

The spleen is of appropriate size and has a normal, homogenous parenchyma with a smooth, continuous capsular surface. The splenic vasculature is normal with no evidence of congestion or thrombosis, and blood flow through the splenic hilus appears normal. Thickness at the splenic hilus is normal. The spleen measured 8.0 mm.

Liver

The liver is of appropriate size and shape, with sharp borders and a mildly coarse parenchymal echotexture that is hypoechoic to the spleen. The portal and hepatic vasculature are of normal size and appearance with no evidence of congestion or thrombosis.

PATIENT
Rocky Laidler

SPECIES
Feline

BREED
DLH

SEX
Neutered Male

AGE
2 Years

WEIGHT
5.38 kg

INTERPRETED BY
Tam Mengine, DVM, DABVP (canine/feline practice)

IMAGING PERFORMED BY
Lindsay Powell CVT

HOSPITAL NAME
Hershey Animal Emergency Center

REFERRING VET
Dr. Brittany Lang

INVOICE
14861

DATE
04/04/26

The gallbladder is moderately distended with anechoic contents. The wall was thin and continuous with no focal lesions. The cystic and common bile ducts are normal / not visible.

Gastrointestinal

The stomach is markedly distended with ingesta. The gastric wall measures 2.3 mm with normal deviations due to rugal folds and exhibits appropriate wall layering. The pylorus is of normal appearance.

The visualized portions of the duodenum, jejunum, and ileum are of normal thickness with intact wall layering that exhibits the appropriate 1:3 muscularis to mucosa ratio. There is a large amount of linear corrugated material noted within the lumen of fluid dilated segments of bowel. The bowel itself does not appear corrugated. There are also empty bowel loops with no luminal material seen. The surrounding mesentery is hyperechoic.

The visible portions of the colon are of normal thickness with intact wall layering measuring 1.6 mm. The ileocecal junction was not seen.

Pancreas

The areas of the limbs and body of the pancreas are isoechoic to the surrounding mesenteric fat, with normal capsular appearance. There is no evidence of peripancreatic inflammation. The pancreatic duct appears normal.

Free Abdomen

There is focal free fluid present throughout the abdomen. The associated omentum and intra-abdominal fat are hyperechoic. Enlarged abdominal lymph nodes are not observed. The aortic trifurcation has normal blood flow with no evidence of thrombosis.

PRIMARY FINDINGS

- Large amount of linear material seen within the dilated loops of small bowel as well as a population of empty bowel strongly supportive of an obstructive linear foreign body.
- Free fluid and steatitis throughout the abdomen consistent with peritonitis.

INTERPRETATION OF THE FINDINGS & FURTHER RECOMMENDATIONS

The sonographic findings are concerning for an obstructive linear foreign body. Abdominal exploratory would be recommended, and the possibility of a perforation should be investigated given the amount of free fluid present. Alternatively, sampling of free fluid could be attempted, and if there is evidence of a septic abdomen, this could be taken into consideration in terms of prognosis with surgical management.

SonoPath
FOSTERING THE ART OF VETERINARY MEDICINE™

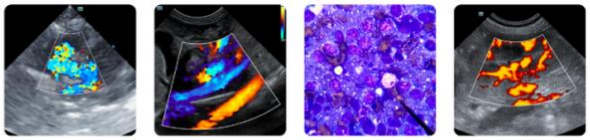

Clinical Sonography & Telecytology
Educational Teleconsultation Services™

SonoPath.com info@sonopath.com 1.800.838.4268

PATIENT

Rocky Laidler

SPECIES

Feline

BREED

DLH

SEX

Neutered Male

AGE

2 Years

WEIGHT

5.38 kg

INTERPRETED BY

Tam Mengine, DVM, DABVP (canine/feline practice)

IMAGING PERFORMED BY

Lindsay Powell CVT

HOSPITAL NAME

Hershey Animal Emergency Center

REFERRING VET

Dr. Brittany Lang

INVOICE

14861

DATE

04/04/26

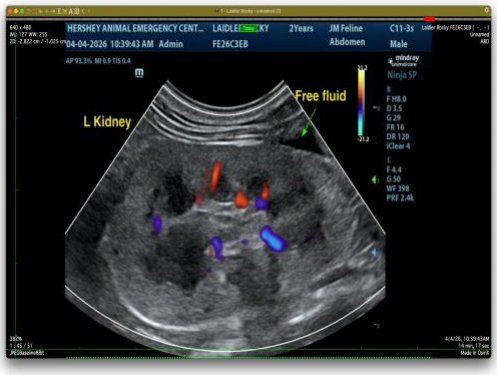

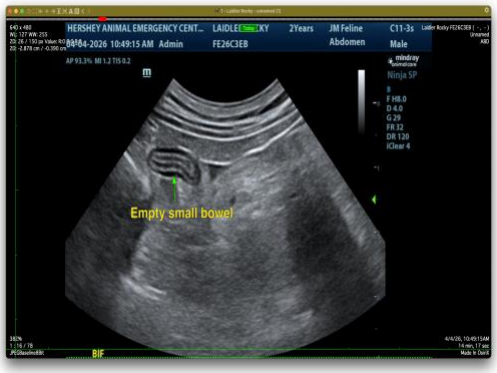

The information and recommendations provided are based on the images presented by the referring veterinarian/sonographer. No evaluation can be communicated regarding pathology that was not visible in the image/video clips provided.

Thank you for this referral. If the clinical or image interpretation does not parallel your findings or if I can be of any further assistance, please contact me.

Tam Mengine, DVM, DABVP (canine/feline practice)

info@SonoPath.com