



PATIENT

Luna Quick

PRESENTING CLINICAL SIGNS

Follow up HGE dx at ER. Sludging of GB (dx on recent U/S)

SPECIES

Canine

ULTRASONOGRAPHIC EXAMINATION OF THE ABDOMEN

Urinary System

BREED

Mixed

The urinary bladder is moderately distended with anechoic urine, and no luminal sediment is present. The ureteral papillae, trigone and pelvic urethra (visible to 3.0 cm) are of normal appearance, and the ureters are not visible (normal). No masses, calculi or mucosal irregularities are noted.

SEX

Spayed Female

The kidneys are of normal size and shape and exhibit appropriate corticomedullary differentiation with a normal 1:3 cortex to medulla ratio. There is no evidence of nephrolithiasis, mineralization, pyelectasia, cystic change or hydronephrosis. The proximal ureter is not visible (normal). The left kidney measured 6.6 cm in length. The right kidney measured 6.6 cm in length.

AGE

4 Years

Adrenal Glands

WEIGHT

77 pounds

The adrenal glands are both identified in their normal locations. They are normal in size and shape with appropriate parenchymal echogenicity and normal phrenic vasculature. The left adrenal gland measured 5.6 mm at the cranial pole and 5.2 mm at the caudal pole. The right adrenal gland measured 7.1 mm at the cranial pole and 8.6 mm at the caudal pole.

INTERPRETED BY

Tam Mengine, DVM,
DABVP (canine/feline
practice)

Spleen

The spleen is of appropriate size and has a normal, homogenous parenchyma with a smooth, continuous capsular surface. The splenic vasculature is normal with no evidence of congestion or thrombosis, and blood flow through the splenic hilus appears normal.

IMAGING PERFORMED BY

Meghan Morse LVT
CVT

Liver

The liver is of appropriate size and shape, with sharp borders and a mildly coarse parenchymal echotexture that is hypoechoic to the spleen. The portal and hepatic vasculature are of normal size and appearance with no evidence of congestion or thrombosis.

HOSPITAL NAME

Narrowsburg
Veterinary

The gallbladder is moderately distended with anechoic contents. The wall was thin and continuous with no focal lesions. The cystic and common bile ducts are normal / not visible.

REFERRING VET

Dr. Hess

Gastrointestinal

The stomach is mildly distended with gas. The gastric wall is 5.3 mm with normal deviations due to rugal folds, and exhibits appropriate wall layering. The pylorus is of normal appearance.

INVOICE

14848

The visualized portions of the duodenum, jejunum, and ileum are of normal thickness with intact wall layering that exhibits the appropriate 1:3 muscularis to mucosa ratio. Intestinal motility appears normal.

DATE

04/03/26

The visible portions of the colon are of normal thickness with intact wall layering measuring 1.6 mm. The ileocecal junction was not seen.

Pancreas



PATIENT

Luna Quick

SPECIES

Canine

BREED

Mixed

SEX

Spayed Female

AGE

4 Years

WEIGHT

77 pounds

INTERPRETED BY

Tam Mengine, DVM,
DABVP (canine/feline
practice)

**IMAGING
PERFORMED BY**

Meghan Morse LVT
CVT

HOSPITAL NAME

Narrowsburg
Veterinary

REFERRING VET

Dr. Hess

INVOICE

14848

DATE

04/03/26

The pancreas is isoechoic to the surrounding mesenteric fat, with normal capsular appearance. There is no evidence of peripancreatic inflammation. The pancreatic duct appears normal.

Free Abdomen

There is no evidence of free fluid within the peritoneal cavity. The omentum and intra-abdominal fat are of appropriate echogenicity. Enlarged abdominal lymph nodes are not observed. The aortic trifurcation has normal blood flow with no evidence of thrombosis.

PRIMARY FINDINGS

- Unremarkable canine abdomen.

INTERPRETATION OF THE FINDINGS & FURTHER RECOMMENDATIONS

There is no apparent cause for the reported gastrointestinal signs on today's ultrasound. Additional recommendations, if not already performed, would include:

- ❖ If there is significant hemorrhagic component to the patient's gastrointestinal signs, checking coagulation parameters would be recommended if not already performed.
- ❖ fecal parasite testing and empiric fenbendazole treatment
- ❖ probiotic therapy
- ❖ bland diet
- ❖ treatment with parenteral fluids, antiemetics, antacids and gastroprotectants as clinically indicated.
- ❖ While the pancreas appears normal, serum markers can be more sensitive than ultrasound in the detection of pancreatitis, thus a PLI or other serum marker to screen for pancreatitis is recommended.
- ❖ If signs persist, trials with a novel protein or hydrolyzed diet, a resting cortisol level and a GI panel could be considered.
- ❖ It is possible for occult intestinal disease to present with normal ultrasound findings; thus endoscopic or surgical GI biopsies would be indicated if symptoms persist and another cause cannot be found.



PATIENT

Luna Quick

SPECIES

Canine

BREED

Mixed

SEX

Spayed Female

AGE

4 Years

WEIGHT

77 pounds

INTERPRETED BY

Tam Mengine, DVM,
 DABVP (canine/feline
 practice)

**IMAGING
 PERFORMED BY**

Meghan Morse LVT
 CVT

HOSPITAL NAME

Narrowsburg
 Veterinary

REFERRING VET

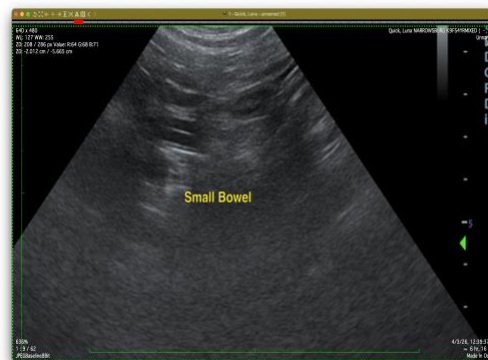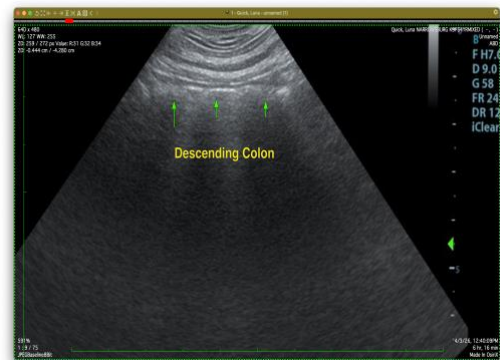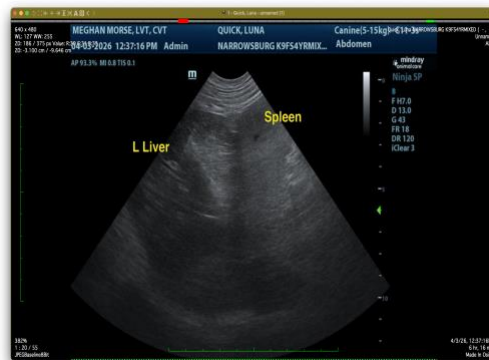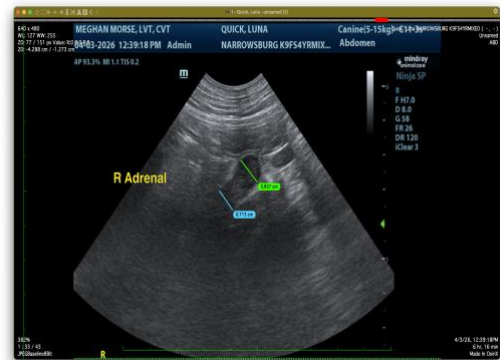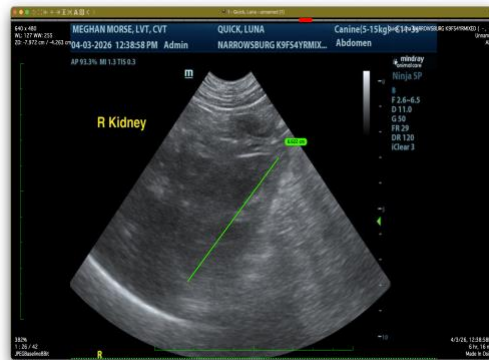
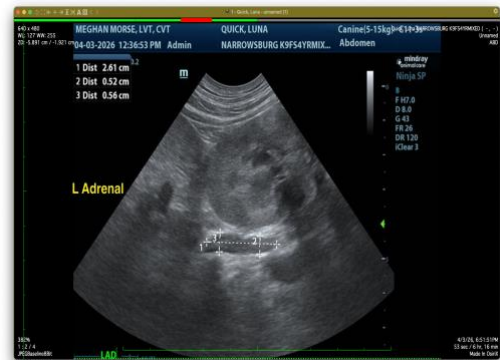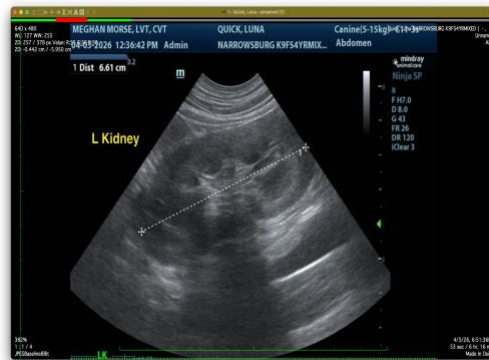Dr. Hess

INVOICE

14848

DATE

04/03/26





PATIENT

Luna Quick

SPECIES

Canine

BREED

Mixed

SEX

Spayed Female

AGE

4 Years

WEIGHT

77 pounds

INTERPRETED BY

Tam Mengine, DVM,
DABVP (canine/feline
practice)

**IMAGING
PERFORMED BY**

Meghan Morse LVT
CVT

HOSPITAL NAME

Narrowsburg
Veterinary

REFERRING VET

Dr. Hess

INVOICE

14848

DATE

04/03/26

The information and recommendations provided are based on the images presented by the referring veterinarian/sonographer. No evaluation can be communicated regarding pathology that was not visible in the image/video clips provided.

Thank you for this referral. If the clinical or image interpretation does not parallel your findings or if I can be of any further assistance, please contact me.

Tam Mengine, DVM, DABVP (canine/feline practice)

info@SonoPath.com