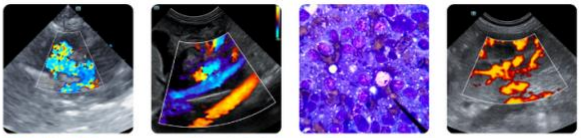

Clinical Sonography & Telecytology
Educational Teleconsultation Services™

PATIENT

Raven Day

SPECIES

Feline

BREED

DSH

SEX

Spayed Female

AGE

19 Years 1 Months

WEIGHT

9.11 pounds

INTERPRETED BY

Tam Mengine, DVM, DABVP (canine/feline practice)

IMAGING PERFORMED BY

Rebecca Hamilton

HOSPITAL NAME

Andover Animal Hospital

REFERRING VET

Dr. Lawlor

INVOICE

15207

DATE

04/17/26

PRESENTING CLINICAL SIGNS

Inappropriate urination, ADR, hyporexia, relatively unremarkable exam, mod. dental dz.

Abnormal PE/Chem/CBC/UA Results: Creat 1.7, SDMA 13.2, BUN 33, Amylase 1730 (H) Precision PSL 27 (H)

ULTRASONOGRAPHIC EXAMINATION OF THE ABDOMEN

Urinary System

The urinary bladder is moderately distended with anechoic urine, and no luminal sediment is present. The ureteral papillae, trigone and pelvic urethra (visible to 3.0 cm) are of normal appearance, and the ureters are not visible (normal). No masses, calculi or mucosal irregularities are noted.

Both kidneys are hyperechoic and exhibit mildly decreased cortico-medullary differentiation. There are small cortical cysts present within the left kidney. There is no evidence of nephrolithiasis, mineralization, pyelectasia or hydronephrosis. The proximal ureters are not visible (normal). The left kidney is 3.2 cm in length. The right kidney is 3.6 cm in length.

Adrenal Glands

The adrenal glands are both identified in their normal locations. They are normal in size and shape with appropriate parenchymal echogenicity and normal phrenic vasculature. The left adrenal gland measured 2.6 mm. The right adrenal gland measured 3.1 mm.

Spleen

The spleen is of appropriate size and has a normal, homogenous parenchyma with a smooth, continuous capsular surface. The splenic vasculature is normal with no evidence of congestion or thrombosis, and blood flow through the splenic hilus appears normal. Thickness at the splenic hilus is normal. The spleen measured 7.7 mm.

Liver

The liver is of appropriate size and shape, with sharp borders and a mildly coarse parenchymal echotexture that is hypoechoic to the spleen. The portal and hepatic vasculature are of normal size and appearance with no evidence of congestion or thrombosis.

The gallbladder is moderately distended with anechoic contents. The wall was thin and continuous with no focal lesions. The cystic and common bile ducts are normal / not visible.

Gastrointestinal

The stomach is empty. The gastric wall is normal deviations due to rugal folds and exhibits appropriate wall layering. The pylorus is of normal appearance.

The visualized portions of the duodenum, jejunum, and ileum are of normal thickness with intact wall layering that exhibits the appropriate 1:3 muscularis to mucosa ratio. Intestinal motility appears normal.

The visible portions of the colon (1.2 mm) are of normal thickness with intact wall layering. The ileocecal junction is normal.

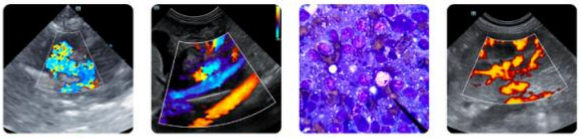

PATIENT

Raven Day

SPECIES

Feline

BREED

DSH

SEX

Spayed Female

AGE

19 Years 1 Months

WEIGHT

9.11 pounds

INTERPRETED BY

Tam Mengine, DVM, DABVP (canine/feline practice)

IMAGING PERFORMED BY

Rebecca Hamilton

HOSPITAL NAME

Andover Animal Hospital

REFERRING VET

Dr. Lawlor

INVOICE

15207

DATE

04/17/26

Pancreas

The left limb of the pancreas is swollen and hypoechoic, surrounded by hyperechoic mesenteric fat. The pancreatic duct appears normal.

Free Abdomen

There is no free fluid noted within the abdomen. There is hyperechoic, inflamed omental fat noted in the region of stomach and pancreas. Enlarged abdominal lymph nodes are not observed. The aortic trifurcation has normal blood flow with no evidence of thrombosis.

PRIMARY FINDINGS

- Hypoechoic left pancreas with steatitis, consistent with pancreatitis.
- Steatitis in the region of the stomach, which may be secondary to pancreatic inflammation or may represent primary gastritis.

SECONDARY FINDINGS

- Mild chronic renal changes.

INTERPRETATION OF THE FINDINGS & FURTHER RECOMMENDATIONS

The sonographic findings are consistent with mild pancreatitis, potentially with concurrent gastritis. Additional recommendations include:

- ❖ A full GI panel, are indicated for confirmation and to screen for concurrent intestinal disease, and hypocobalaminemia.
- ❖ supportive care including fluid therapy, antiemetics, analgesics, appetite stimulants (if needed) and cobalamin supplementation are warranted.
- ❖ a highly digestible intestinal diet is recommended.
- ❖ if the patient is not responding to medical management, fine needle aspiration with a 25G needle for cytology could be considered after first checking a coagulation profile.

The changes in the kidneys are consistent with chronic renal disease. Findings should be correlated with laboratory values, IRIS staging and clinical signs.

New Jersey Mobile
FUELED BY SONOPATH VETERINARY ULTRASOUND

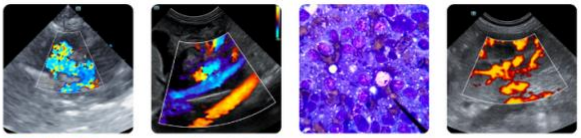

Clinical Sonography & Telecytology
Educational Teleconsultation Services™

SonoPath
FOSTERING THE ART OF VETERINARY MEDICINE™
www.SonoPath.com
info@sonopath.com 800.838.4268

PATIENT

Raven Day

SPECIES

Feline

BREED

DSH

SEX

Spayed Female

AGE

19 Years 1 Months

WEIGHT

9.11 pounds

INTERPRETED BY

Tam Mengine, DVM, DABVP (canine/feline practice)

IMAGING PERFORMED BY

Rebecca Hamilton

HOSPITAL NAME

Andover Animal Hospital

REFERRING VET

Dr. Lawlor

INVOICE

15207

DATE

04/17/26

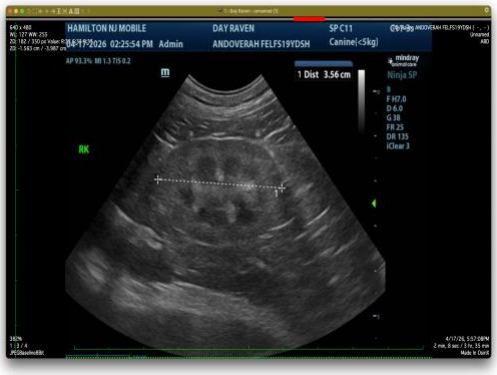

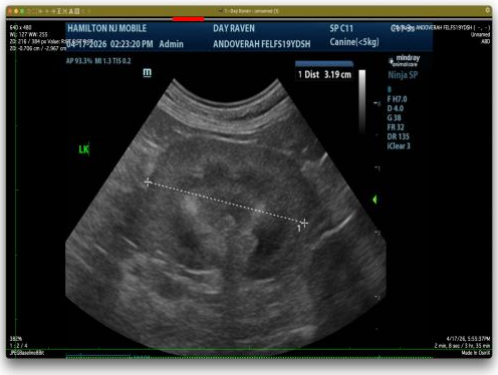

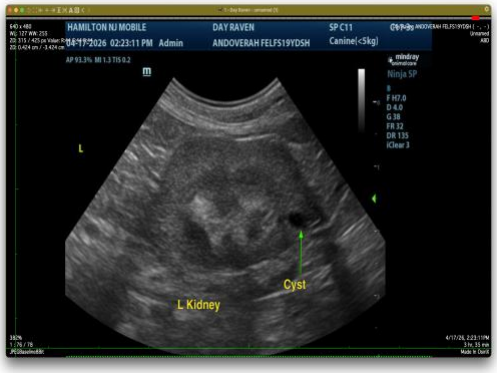

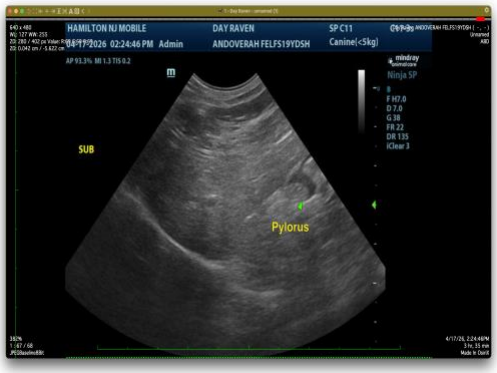

The information and recommendations provided are based on the images presented by the referring veterinarian/sonographer. No evaluation can be communicated regarding pathology that was not visible in the image/video clips provided.

Thank you for this referral. If the clinical or image interpretation does not parallel your findings or if I can be of any further assistance, please contact me.

Tam Mengine, DVM, DABVP (canine/feline practice)

info@SonoPath.com