

**PATIENT**

Coco Rohaly

**SPECIES**

Feline

**BREED**

DSH

**SEX**

Female Spayed

**AGE**

7 years

**WEIGHT**

6 kg

**INTERPRETED BY**

Tam Mengine, DVM,  
DABVP (canine/feline  
practice)

**IMAGING  
PERFORMED BY**

Kelly Reschny

**HOSPITAL NAME**

East Plains AH

**REFERRING VET**

Loh

**INVOICE**

12346

**DATE**

3.6.23

**PRESENTING CLINICAL SIGNS**

History: Intermittent inappetence and chronic soft stools/diarrhea. Since November 2022, Coco has had chronic soft stools or diarrhea despite treatment course and dietary changes. For the past 3 weeks, Coco has had weight loss and intermittent inappetence. Coco has lost weight since this started over the last 2 months. Examination on February 15/23 was unremarkable and vital signs were normal. Client thought Coco might have arthritic pain so requested Solensia and was given March 1/23. Current Medications Solensia

Abnormal PE/Chem/CBC/UA Results: Geriatric screen with Spec fPLI was performed February 15/23 and found to be unremarkable.

**ULTRASONOGRAPHIC EXAMINATION OF THE ABDOMEN**

**Urinary System**

The urinary bladder is moderately distended with anechoic urine, and no luminal sediment is present. The ureteral papillae, trigone and pelvic urethra are of normal appearance, and the ureters are not visible (normal). No masses, calculi or mucosal irregularities are noted. Urethra visualized to 3.0 cm.

The kidneys are of normal size and shape and exhibit appropriate corticomedullary differentiation with a normal 1:3 cortex to medulla ratio. There is trace pyelectasia in the right kidney. There is no evidence of nephrolithiasis, mineralization, cystic change or hydronephrosis. The proximal ureters are not visible (normal). The left kidney is 3.4 cm in length. The right kidney is 3.5 cm in length.

**Adrenal Glands**

The adrenal glands are both identified in their normal locations. They are normal in size and shape with appropriate parenchymal echogenicity and normal phrenic vasculature. The left adrenal gland height is 3.2 mm at the caudal pole. The right adrenal gland height 3.8 mm at the caudal pole.

**Spleen**

The spleen is of appropriate size and has a normal, homogenous parenchyma with a smooth, continuous capsular surface. The splenic vasculature is normal with no evidence of congestion or thrombosis, and blood flow through the splenic hilus appears normal. Thickness at the splenic hilus is normal at 9.0 cm).

**Liver**

The liver is of appropriate size and shape, with sharp borders and a mildly coarse parenchymal echotexture that is hypoechoic to the spleen. There is a 2.9 x 4.9 cm hyperechoic mass with diffuse cystic change, arising from the caudal aspect of the liver. The portal and hepatic vasculature are of normal size and appearance with no evidence of congestion or thrombosis.

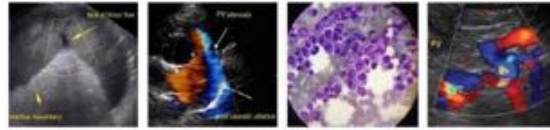
The gallbladder is moderately distended with anechoic contents. The wall was thin and continuous with no focal lesions. The cystic and common bile ducts are normal / not visible.

**Gastrointestinal**

The stomach is empty. The gastric wall is 2.5 mm with normal deviations due to rugal folds and exhibits appropriate wall layering. The pylorus is of normal appearance.

The small bowel has diffuse changes to the normal 1:3 muscularis to mucosa ratio. Wall measurements increased up to 2.3 mm for duodenum and 3.1 mm for jejunum. Overall wall layering is preserved. Intestinal motility appears normal.

The visible portions of the colon are of normal thickness, up to 1.8 mm, with intact wall layering. The ileocecal junction is visualized and appears normal.



**PATIENT**

Coco Rohaly

**Pancreas**

The areas of the limbs and body of the pancreas are isoechoic to the surrounding mesenteric fat, with normal capsular appearance. There is no evidence of peripancreatic inflammation. The pancreatic duct appears normal.

**SPECIES**

Feline

**Free Abdomen**

There is no evidence of free fluid within the peritoneal cavity. The omentum and intra-abdominal fat are of appropriate echogenicity. Enlarged abdominal lymph nodes are not observed. The aortic trifurcation has normal blood flow with no evidence of thrombosis.

**BREED**

DSH

**ULTRASONOGRAPHIC FINDINGS**

**Findings**

- Diffuse changes to the small bowel consistent with infiltrative bowel disease
- Hyperechoic cystic liver mass

**SEX**

Female Spayed

**AGE**

7 years

**INTERPRETATION OF THE FINDINGS & FURTHER RECOMMENDATIONS**

The mass on the liver may represent a benign adenoma, or less likely, a hepatic malignancy. Core biopsy is recommended for definitive diagnosis. CT would be appropriate for surgical planning, if a resection was intended. Three-view chest radiographs are also recommended.

**WEIGHT**

6 kg

The changes in the gastrointestinal tract are suggestive of infiltrative bowel disease, including both inflammatory bowel disease or low grade gastrointestinal lymphoma. It is suspected that this is the cause of the reported diarrhea and weight loss, as opposed to the hepatic mass. Recommendations include:

**INTERPRETED BY**

Tam Mengine, DVM,  
DABVP (canine/feline  
practice)

- Fecal parasite testing and empiric fenbendazole treatment
- Trials with a novel protein or hydrolyzed diet
- A complete GI panel, or empiric cobalamin supplementation
- Empiric therapy with prednisolone at 2-4mg / kg daily could be considered if a diet trial is unsuccessful.
- Definitive diagnosis would require biopsy of the affected tissue, ideally with intra-operative ultrasonographic guidance. If there is concurrent lymphadenopathy, ultrasound-guided sampling of the lymph node using a 25 or 22G needle could be considered.

**IMAGING PERFORMED BY**

Kelly Reschny

**HOSPITAL NAME**

East Plains AH

**REFERRING VET**

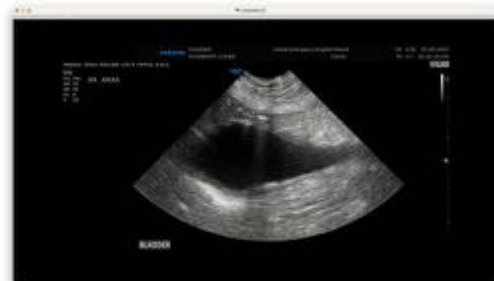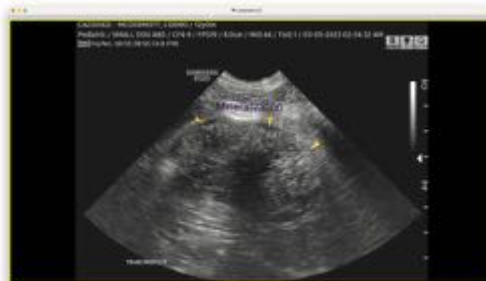Loh

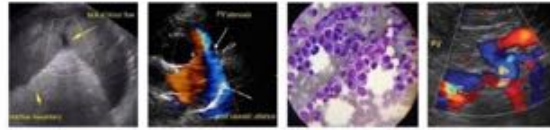
**INVOICE**

12346

**DATE**

3.6.23





**PATIENT**

Coco Rohaly

**SPECIES**

Feline

**BREED**

DSH

**SEX**

Female Spayed

**AGE**

7 years

**WEIGHT**

6 kg

**INTERPRETED BY**

Tam Mengine, DVM,  
DABVP (canine/feline  
practice)

**IMAGING  
PERFORMED BY**

Kelly Reschny

**HOSPITAL NAME**

East Plains AH

**REFERRING VET**

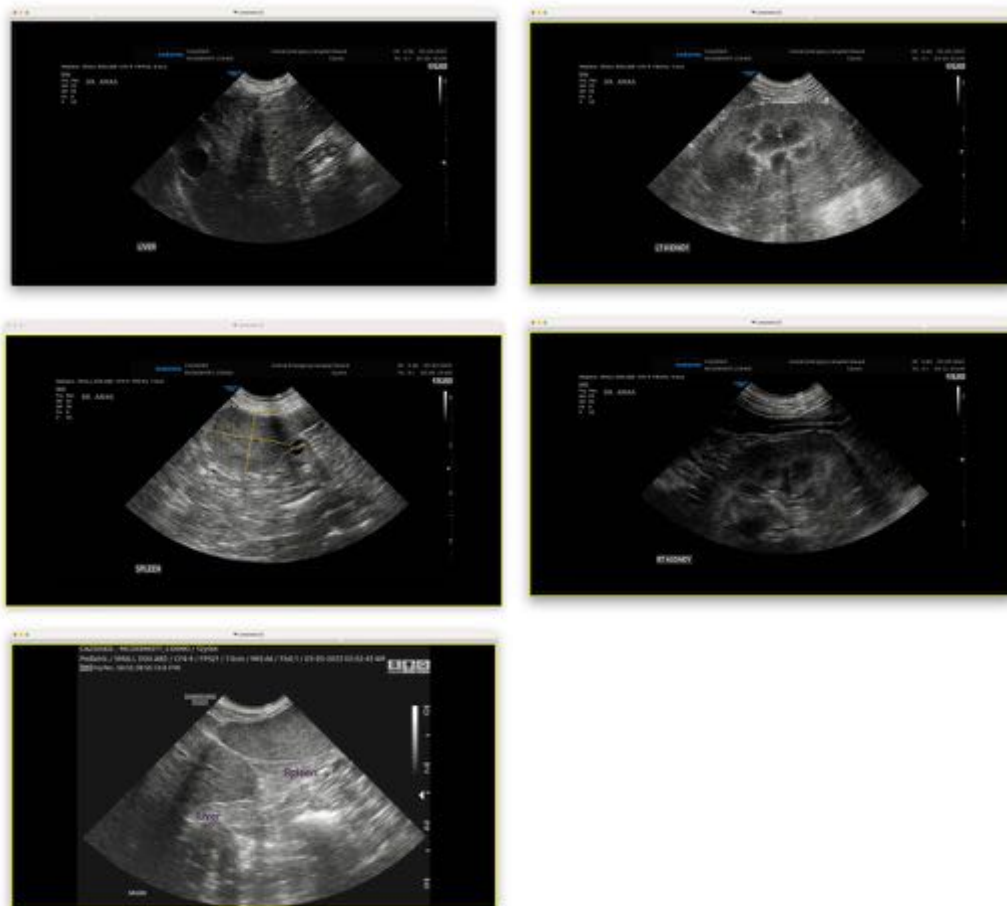
Loh

**INVOICE**

12346

**DATE**

3.6.23



The information and recommendations provided are based on the images presented by the referring veterinarian. No evaluation can be communicated regarding pathology that was not visible in the image/video clips provided.

Thank you for this referral. If the clinical or image interpretation does not parallel your findings or if I can be of any further assistance, please contact me.

Tam Mengine, DVM, DABVP (canine/feline practice) info@SonoPath.com