

PATIENT

Dexter Greenberg

SPECIES

Canine

BREED

Coonhound

SEX

Neutered Male

AGE

5 Years

WEIGHT

19.4 kg

INTERPRETED BY

Tam Mengine DVM,
DABVP
(Canine/Feline
Practice)

IMAGING PERFORMED BY

Lindsay Powell, CVT

HOSPITAL NAME

Hershey AEC

REFERRING VET

Dr. Sarah Moser

INVOICE

36394

DATE

3/28/26

PRESENTING CLINICAL SIGNS

Transfer from Valley Green (rDVM)

Pancreatitis and low platelets

decreased appetite, soft stool with bloody mucous

Abnormal PE/Chem/CBC/UA Results: Abdominal: Reactive upon deep palpation but otherwise compliant with no abnormalities or pain on palpation No obvious ecchymosis, petechia or other bruising noted 4dx snap - Negative x4 CBC - Unremarkable PT/aPTT - 15.4 (n)/ 108.9 (n)

ULTRASONOGRAPHIC EXAMINATION OF THE ABDOMEN

Urinary System

The urinary bladder is moderately distended with anechoic urine, and no luminal sediment is present. The ureteral papillae, trigone and pelvic urethra are of normal appearance, and the ureters are not visible (normal). No masses, calculi or mucosal irregularities are noted. Urethra visualized to 4.0 cm.

The kidneys are of normal size and shape and exhibit appropriate corticomedullary differentiation with a normal 1:3 cortex to medulla ratio. There is no evidence of nephrolithiasis, mineralization, pyelectasia, cystic change or hydronephrosis. The proximal ureter is not visible (normal). The left kidney is 6.0 cm in length. The right kidney is 6.2 cm in length.

Adrenal Glands

The adrenal glands are both identified in their normal locations. They are normal in size and shape with appropriate parenchymal echogenicity and normal phrenic vasculature. The left adrenal gland height is 5.3 mm at the cranial pole and 5.8 mm at the caudal pole. The right adrenal gland height is 7.7 mm at the cranial pole and 5.1 mm at the caudal pole.

Spleen

The spleen is of appropriate size and has a normal, homogenous parenchyma with a smooth, continuous capsular surface. The splenic vasculature is normal with no evidence of congestion or thrombosis, and blood flow through the splenic hilus appears normal.

Liver

The liver is of appropriate size and shape, with sharp borders and a mildly coarse parenchymal echotexture that is hypoechoic to the spleen. The portal and hepatic vasculature are of normal size and appearance with no evidence of congestion or thrombosis.

The gallbladder is moderately distended with anechoic contents and a small amount of freely moveable echogenic sludge. The wall was thin and continuous with no focal lesions. The cystic and common bile ducts are normal / not visible.

Gastrointestinal

The stomach is mildly distended with ingesta. The gastric wall is 3.2 mm with normal deviations due to rugal folds and exhibits appropriate wall layering. The pylorus is of normal appearance.



PATIENT

Dexter Greenberg

SPECIES

Canine

BREED

Coonhound

SEX

Neutered Male

AGE

5 Years

WEIGHT

19.4 kg

INTERPRETED BY

Tam Mengine DVM,
DABVP
(Canine/Feline
Practice)

IMAGING PERFORMED BY

Lindsay Powell, CVT

HOSPITAL NAME

Hershey AEC

REFERRING VET

Dr. Sarah Moser

INVOICE

36394

DATE

3/28/26

The visualized portions of the duodenum, jejunum, and ileum are of normal thickness with intact wall layering that exhibits the appropriate 1:3 muscularis to mucosa ratio. Intestinal motility appears normal.

The visible portions of the colon are of normal thickness, up to 1.1 mm, with intact wall layering. The ileocecal junction is not visualized.

Pancreas

The areas of the limbs and body of the pancreas are isoechoic to the surrounding mesenteric fat, with normal capsular appearance. There is no evidence of peripancreatic inflammation. The pancreatic duct appears normal.

Free Abdomen

There is no evidence of free fluid within the peritoneal cavity. The omentum and intra-abdominal fat are of appropriate echogenicity. Enlarged abdominal lymph nodes are not observed. The aortic trifurcation has normal blood flow with no evidence of thrombosis.

ULTRASONOGRAPHIC FINDINGS

- Unremarkable canine abdomen

INTERPRETATION OF THE FINDINGS & FURTHER RECOMMENDATIONS

There is no apparent cause for the reported gastrointestinal signs on today's ultrasound. Additional recommendations, if not already performed, would include:

- fecal parasite testing and empiric fenbendazole treatment
- probiotic therapy
- bland diet
- treatment with parenteral fluids, antiemetics, antacids and gastroprotectants as clinically indicated.
- While the pancreas appears normal, serum markers can be more sensitive than ultrasound in the detection of pancreatitis, thus a PLI or other serum marker to screen for pancreatitis is recommended.
- If signs persist, trials with a novel protein or hydrolyzed diet, a resting cortisol level and a GI panel could be considered.
- It is possible for occult intestinal disease to present with normal ultrasound findings, thus endoscopic or surgical GI biopsies would be indicated, if symptoms persist and another cause cannot be found.



PATIENT

Dexter Greenberg

SPECIES

Canine

BREED

Coonhound

SEX

Neutered Male

AGE

5 Years

WEIGHT

19.4 kg

INTERPRETED BY

Tam Mengine DVM,
DABVP
(Canine/Feline
Practice)

**IMAGING
PERFORMED BY**

Lindsay Powell, CVT

HOSPITAL NAME

Hershey AEC

REFERRING VET

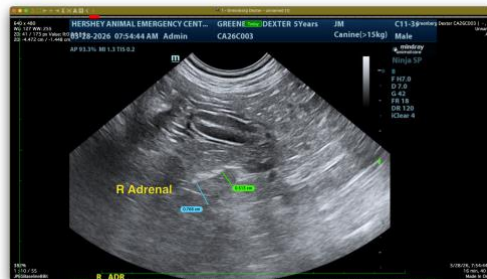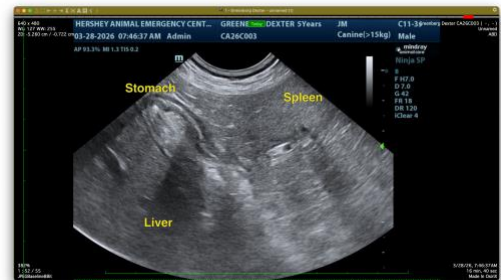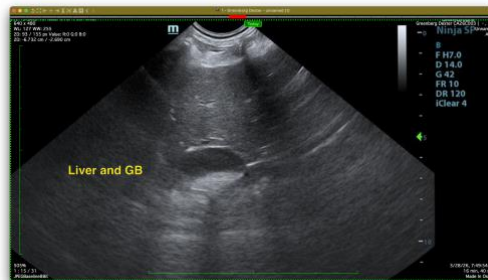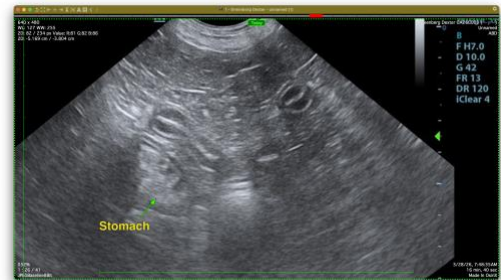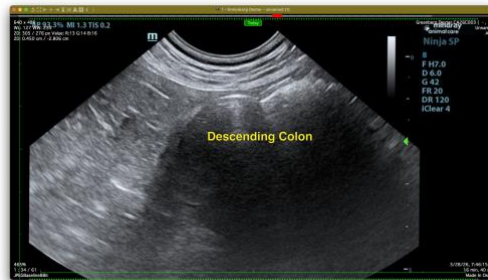
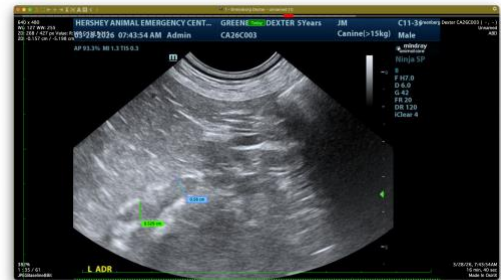
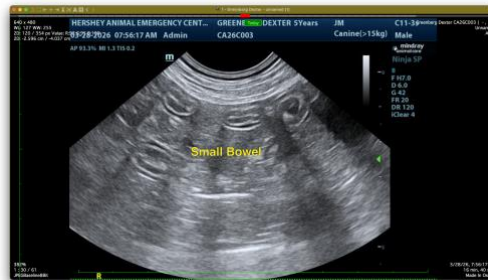Dr. Sarah Moser

INVOICE

36394

DATE

3/28/26



The information and recommendations provided are based on the images presented by the referring veterinarian. No evaluation can be communicated regarding pathology that was not visible in the image/video clips provided.

Thank you for this referral. If the clinical or image interpretation does not parallel your findings or if I can be of any further assistance please contact me.

Tam Mengine, DVM, DABVP (canine/feline practice)

info@SonoPath.com