

**PATIENT**

Leo Boerner

**SPECIES**

Canine

**BREED**

Chihuahua X

**SEX**

Neutered Male

**AGE**

13 years

**WEIGHT**

7.5 kg

**INTERPRETED BY**

Tam Mengine, DVM,  
DABVP (canine/feline  
practice)

**IMAGING  
PERFORMED BY**

Dr Sarah Barthelemy

**HOSPITAL NAME**

Signal Hill AC

**REFERRING VET**

Dr Cumyn

**INVOICE**

12397

**DATE**

3.10.23

**PRESENTING CLINICAL SIGNS**

History: Hx of pu/pd and elevated ALP chronically.

Abnormal PE/Chem/CBC/UA Results: USG 1.004. ALP 2000+

**ULTRASONOGRAPHIC EXAMINATION OF THE ABDOMEN**

**Urinary System**

The urinary bladder is moderately distended with anechoic urine, and no luminal sediment is present. The ureteral papillae, trigone and pelvic urethra are of normal appearance, and the ureters are not visible (normal). No masses, calculi or mucosal irregularities are noted. Urethra visualized to 3.0 cm.

The prostate is of appropriate size for patient age and neutering status, with a homogenous parenchyma and smooth capsule. The prostatic urethra is non-dilated with normal margins.

The kidneys are of normal size and shape and exhibit appropriate corticomedullary differentiation with a normal 1:3 cortex to medulla ratio. There is no evidence of nephrolithiasis, mineralization, pyelectasia, cystic change or hydronephrosis. The proximal ureter is not visible (normal). The left kidney is 3.9 cm in length. The right kidney is 4.7 cm in length.

**Adrenal Glands**

The left adrenal gland is mildly enlarged, with normal echotexture and phrenic vasculature. The right adrenal gland is of normal size and shape. Both are found in their normal locations. The left adrenal gland height is 5.3 mm at the cranial pole and 7.8 mm at the caudal pole. The right adrenal gland height is 6.3 mm at the cranial pole and 4.8 at the caudal pole.

**Spleen**

The splenic parenchyma is of appropriate size and has a normal homogenous parenchyma, interrupted by several small hypoechoic nodules (measuring up to 4.7 mm in diameter). There is a smooth capsular surface. The splenic vasculature is normal with no evidence of congestion or thrombosis, and blood flow through the splenic hilus appears normal.

**Liver**

The liver is diffusely hyperechoic and subjectively enlarged. There are hypoechoic nodules present throughout the parenchyma, measuring up to 1.1 cm. The portal and hepatic vasculature are of normal size and appearance with no evidence of congestion or thrombosis.

The gallbladder is moderately distended with anechoic contents and a small amount of freely-moveable echogenic sludge. The wall was thin and continuous with no focal lesions. The cystic and common bile ducts are normal / not visible.

**Gastrointestinal**

The stomach is moderately distended with normal ingesta. The gastric wall is 3.6 mm with normal deviations due to rugal folds, and exhibits appropriate wall layering. The pylorus is of normal appearance.

The visualized portions of the duodenum, jejunum, and ileum are of normal thickness with intact wall layering that exhibits the appropriate 1:3 muscularis to mucosa ratio. The duodenal wall measures 4.9 mm. The jejunal wall measures up to 3.6 mm. Intestinal motility appears normal.

The visible portions of the colon are of normal thickness, up to 1.3 mm, with intact wall layering. The ileocecal junction is visualized and appears normal.



## PATIENT

Leo Boerner

## SPECIES

Canine

## BREED

Chihuahua X

## SEX

Neutered Male

## AGE

13 years

## WEIGHT

7.5 kg

## INTERPRETED BY

Tam Mengine, DVM,  
DABVP (canine/feline  
practice)

## IMAGING PERFORMED BY

Dr Sarah Barthelemy

## HOSPITAL NAME

Signal Hill AC

## REFERRING VET

Dr Cumyn

## INVOICE

12397

## DATE

3.10.23

### **Pancreas**

The areas of the limbs and body of the pancreas are isoechoic to the surrounding mesenteric fat, with normal capsular appearance. There is no evidence of peripancreatic inflammation. The pancreatic duct appears normal.

### **Free Abdomen**

There is no evidence of free fluid within the peritoneal cavity. The omentum and intra-abdominal fat are of appropriate echogenicity. Enlarged abdominal lymph nodes are not observed. The aortic trifurcation has normal blood flow with no evidence of thrombosis.

## ULTRASONOGRAPHIC FINDINGS

### Findings

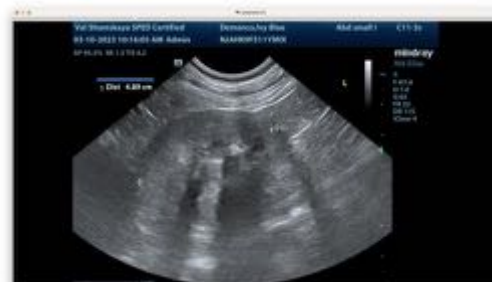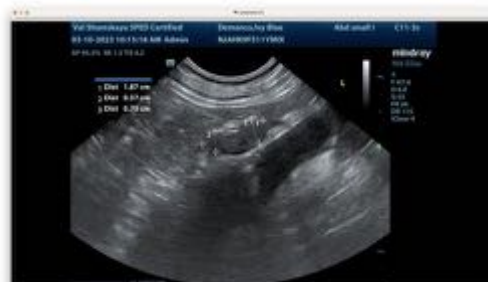- Hypoechoic liver and splenic nodules
- Borderline enlargement of the left adrenal gland

## INTERPRETATION OF THE FINDINGS & FURTHER RECOMMENDATIONS

The changes the adrenal glands are mild, and more likely represent benign hyperplasia, as opposed to active hyper adrenocortical change. If the hyposthenuria has been confirmed on a first-morning urine sample, then additional differential diagnoses would include diabetes insipidus. The presence of hypernatremia would further support the possibility of central diabetes insipidus.

Additional recommendations include:

- A urine culture, as an E. coli infection can cause transient nephrogenic diabetes insipidus
- Testing for Leptospirosis if exposure is possible
- If other causes for hyposthenuria have been ruled out, then screening for central diabetes insipidus with either a modified water deprivation test or a DDAVP trial would be indicated. Note that a DDAVP trial is contraindicated in patients with a low or low-normal sodium, due to the risk of water intoxication, and a modified water deprivation test is contraindicated in patients who are dehydrated, azotemic, or neurologically abnormal. The nodules in the spleen and liver may indicate benign regenerative change, extramedullary hematopoiesis, or less likely, a neoplastic process. Fine-needle aspiration would be needed for definitive diagnosis.





**PATIENT**

Leo Boerner

**SPECIES**

Canine

**BREED**

Chihuahua X

**SEX**

Neutered Male

**AGE**

13 years

**WEIGHT**

7.5 kg

**INTERPRETED BY**

Tam Mengine, DVM,  
DABVP (canine/feline  
practice)

**IMAGING  
PERFORMED BY**

Dr Sarah Barthelemy

**HOSPITAL NAME**

Signal Hill AC

**REFERRING VET**

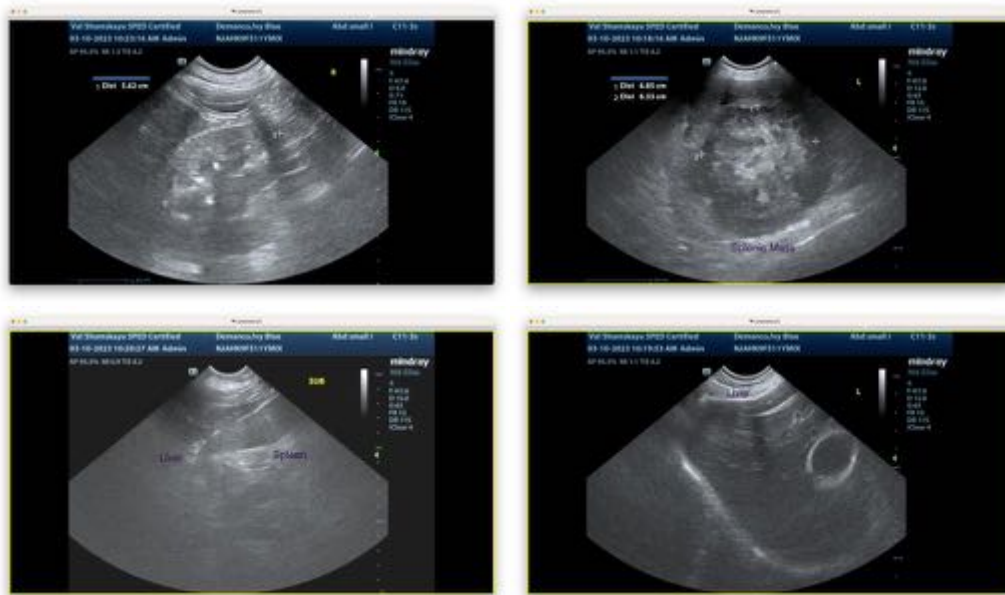
Dr Cumyn

**INVOICE**

12397

**DATE**

3.10.23



The information and recommendations provided are based on the images presented by the referring veterinarian. No evaluation can be communicated regarding pathology that was not visible in the image/video clips provided.

Thank you for this referral. If the clinical or image interpretation does not parallel your findings or if I can be of any further assistance, please contact me.

**Tam Mengine, DVM, DABVP (canine/feline practice) info@SonoPath.com**