

PATIENT

Dallas Ambrogi

PRESENTING CLINICAL SIGNS

History: Elevated ALT. Medication: Denamarin

SPECIES

Feline

ULTRASONOGRAPHIC EXAMINATION OF THE ABDOMEN

BREED

Pitbull Terrier

SEX

Female Spayed

AGE

2016

WEIGHT

55 lbs

INTERPRETED BY

Tam Mengine, DVM,
DABVP (canine/feline
practice)

**IMAGING
PERFORMED BY**

Rebekah Jakum,
CVT, ARDMS/RVT

HOSPITAL NAME

Conrad Weiser AH

REFERRING VET

Dr. Watzka

INVOICE

12399

DATE

3.10.23

Urinary System

The urinary bladder is moderately distended with anechoic urine, and no luminal sediment is present. The ureteral papillae, trigone and pelvic urethra are of normal appearance, and the ureters are not visible (normal). No masses, calculi or mucosal irregularities are noted. Urethra visualized to 3.0 cm.

The kidneys are of normal size and shape and exhibit appropriate corticomedullary differentiation with a normal 1:3 cortex to medulla ratio. There is no evidence of nephrolithiasis, mineralization, pyelectasia, cystic change or hydronephrosis. The proximal ureter is not visible (normal). The left kidney is 6.0 cm in length. The right kidney is 6.7 cm in length.

Adrenal Glands

The adrenal glands are both identified in their normal locations. They are normal in size and shape with appropriate parenchymal echogenicity and normal phrenic vasculature. The left adrenal gland height is 4.2 mm at the cranial pole and 4.2 mm at the caudal pole. The right adrenal gland height is 4.8 mm at the cranial pole and 4.3 mm at the caudal pole.

Spleen

The spleen is of appropriate size and has a normal, homogenous parenchyma with a smooth, continuous capsular surface. The splenic vasculature is normal with no evidence of congestion or thrombosis, and blood flow through the splenic hilus appears normal.

Liver

The liver is of appropriate size and shape, with sharp borders and a mildly coarse parenchymal echotexture that is hypoechoic to the spleen. The portal and hepatic vasculature are of normal size and appearance with no evidence of congestion or thrombosis.

The gallbladder is moderately distended with anechoic contents and a small amount of freely-moveable echogenic sludge. The wall was thin and continuous with no focal lesions. The cystic and common bile ducts are normal / not visible.

Gastrointestinal

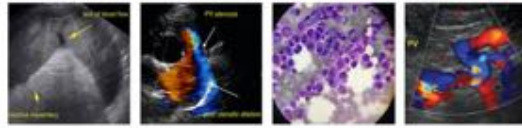
The stomach is empty. The gastric wall is 3.7 mm with normal deviations due to rugal folds and exhibits appropriate wall layering. The pylorus is of normal appearance.

The visualized portions of the duodenum, jejunum, and ileum are of normal thickness with intact wall layering that exhibits the appropriate 1:3 muscularis to mucosa ratio. The duodenal wall measures 4.2 mm. The jejunal wall measures up to 3.6 mm. Intestinal motility appears normal.

The visible portions of the colon are of normal thickness, up to 1.3 mm, with intact wall layering. The ileocecal junction is visualized and appears normal.

Pancreas

The areas of the limbs and body of the pancreas are isoechoic to the surrounding mesenteric fat, with normal capsular appearance. There is no evidence of peripancreatic inflammation. The pancreatic duct appears normal.



PATIENT

Dallas Ambrogi

Free Abdomen

There is no evidence of free fluid within the peritoneal cavity. The omentum and intra-abdominal fat are of appropriate echogenicity. Enlarged abdominal lymph nodes are not observed. The aortic trifurcation has normal blood flow with no evidence of thrombosis.

SPECIES

Feline

ULTRASONOGRAPHIC FINDINGS

Findings

- Unremarkable canine abdomen

BREED

Pitbull Terrier

INTERPRETATION OF THE FINDINGS & FURTHER RECOMMENDATIONS

SEX

Female Spayed

There are no changes on today's ultrasound to explain the elevation in ALT. Depending on the severity of the elevation, recommendations might include serial monitoring to assess response to the Denamarin therapy, or if a more severe elevation is present, additional diagnostic and treatment recommendations might include:

AGE

2016

- Bile acid testing to assess liver function
- Initiation of additional support therapy, such as vitamin E and Ursodiol
- Broad-spectrum antibiotic therapy, such as a combination of amoxicillin or amoxiclav in combination with a fluoroquinolone. If recheck lab values in one week show significant improvement, then a 4-6-week total course of antibiotics is recommended.
- Biopsy would be necessary for definitive diagnosis.

WEIGHT

55 lbs

INTERPRETED BY

Tam Mengine, DVM,
DABVP (canine/feline
practice)

IMAGING PERFORMED BY

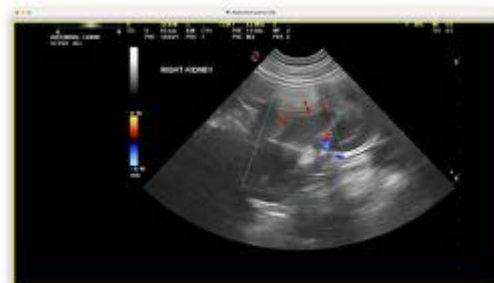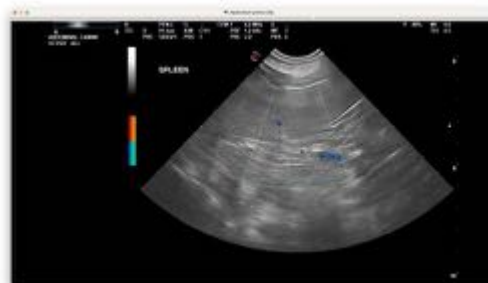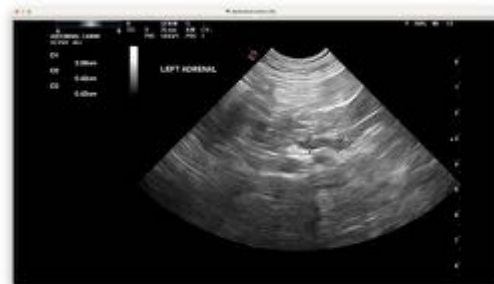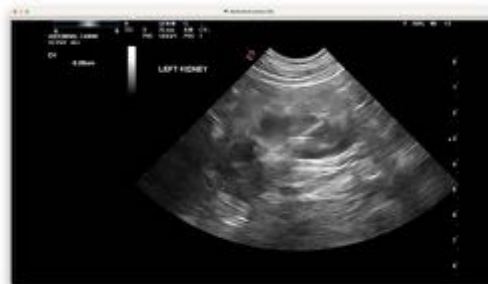Rebekah Jakum,
CVT, ARDMS/RVT

HOSPITAL NAME

Conrad Weiser AH

REFERRING VET

Dr. Watzka

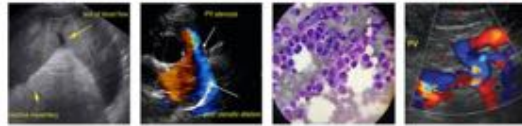


INVOICE

12399

DATE

3.10.23



PATIENT

Dallas Ambrogi

SPECIES

Feline

BREED

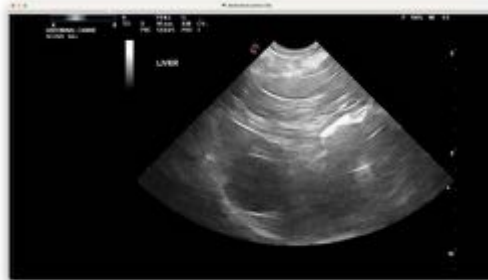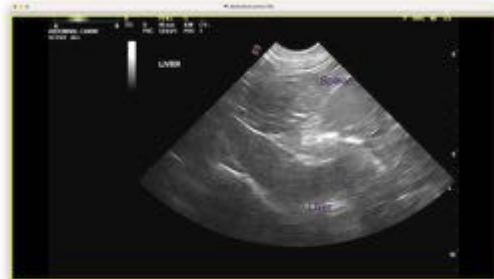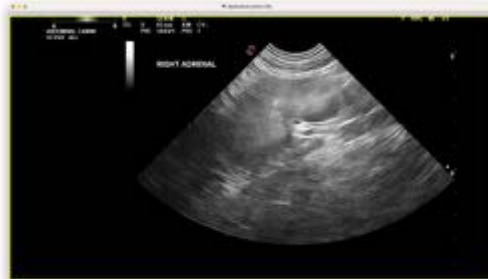Pitbull Terrier

SEX

Female Spayed

AGE

2016



WEIGHT

55 lbs

The information and recommendations provided are based on the images presented by the referring veterinarian. No evaluation can be communicated regarding pathology that was not visible in the image/video clips provided.

Thank you for this referral. If the clinical or image interpretation does not parallel your findings or if I can be of any further assistance, please contact me.

INTERPRETED BY

Tam Mengine, DVM,
DABVP (canine/feline
practice)

Tam Mengine, DVM, DABVP (canine/feline practice) info@SonoPath.com

IMAGING PERFORMED BY

Rebekah Jakum,
CVT, ARDMS/RVT

HOSPITAL NAME

Conrad Weiser AH

REFERRING VET

Dr. Watzka

INVOICE

12399

DATE

3.10.23