



**PATIENT PRESENTING CLINICAL SIGNS**

Sweet Pea Dawson

Bloated abd due to fluid buildup, please see attached histopathology report. Had FB surgery and liver biopsy at time of surgery.

**SPECIES**

Canine

**ULTRASONOGRAPHIC EXAMINATION OF THE ABDOMEN**

*Urinary System*

**BREED**

Pekingese X

The urinary bladder is moderately distended with anechoic urine, and no luminal sediment is present. The ureteral papillae, trigone and pelvic urethra (visible to 3.0 cm) are of normal appearance, and the ureters are not visible (normal). No masses, calculi or mucosal irregularities are noted.

**SEX**

Spayed Female

The kidneys are of normal size and shape and exhibit appropriate corticomedullary differentiation with a normal 1:3 cortex to medulla ratio. There is no evidence of nephrolithiasis, mineralization, pyelectasia, cystic change or hydronephrosis. The proximal ureter is not visible (normal). The left kidney measured 3.9 cm. The right kidney measured 4.1 cm.

**AGE**

11 Years

*Adrenal Glands*

**WEIGHT**

11 Pounds

The adrenal glands are both identified in their normal locations. They are normal in size and shape with appropriate parenchymal echogenicity and normal phrenic vasculature. The left adrenal gland measured 4.8 mm cranially and 4.8 mm caudally. The right adrenal gland measured 1.0 cm cranially and 4.4 mm caudally.

**INTERPRETED BY**

Tam Mengine, DVM,  
DABVP (canine/feline  
practice)

*Spleen*

The spleen is of appropriate size and has a normal, homogenous parenchyma with a smooth, continuous capsular surface. The splenic vasculature is normal with no evidence of congestion or thrombosis, and blood flow through the splenic hilus appears normal.

**IMAGING PERFORMED BY**

Kelly Reschny

*Liver*

The liver is diffusely hyperechoic and subjectively enlarged. The portal and hepatic vasculature are of normal size and appearance with no evidence of congestion or thrombosis.

**HOSPITAL NAME**

Smithville AH

The gallbladder is moderately distended with anechoic contents. The wall was thin and continuous with no focal lesions. The cystic and common bile ducts are normal / not visible.

*Gastrointestinal*

**REFERRING VET**

Dr. Hulzebosch

The stomach is empty. The gastric wall is normal in thickness (4.0 mm) with normal deviations due to rugal folds and exhibits appropriate wall layering. The pylorus is of normal appearance.

**INVOICE**

44779

The visualized portions of the duodenum, jejunum, and ileum are of normal thickness with intact wall layering that exhibits the appropriate 1:3 muscularis to mucosa ratio. Duodenum wall measures 4.1 mm. Jejunum wall measures 3.1 mm. Intestinal motility appears normal.

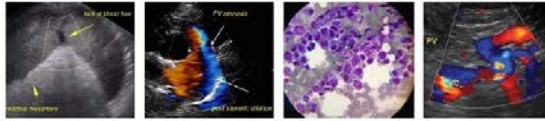
**DATE**

2/3/23

The visible portions of the colon are of normal thickness (1.4 mm) with intact wall layering. The ileocecal junction is not visualized.

*Pancreas*

The areas of the limbs and body of the pancreas are isoechoic to the surrounding mesenteric fat, with normal capsular appearance. There is no evidence of peripancreatic inflammation. The pancreatic duct appears normal.



**PATIENT** *Free Abdomen*

Sweet Pea Dawson

There is a large amount of hypoechoic free fluid present throughout the peritoneal cavity. The omentum and intra-abdominal fat are hyperechoic. Enlarged abdominal lymph nodes are not observed. The aortic trifurcation has normal blood flow with no evidence of thrombosis.

**SPECIES**

Canine

**Heart**

**BREED**

Pekingese X

The apex of the heart is captured in several images, and there appears to be a large amount of pericardial effusion present. It is possible for pleural effusion to be mistaken for pericardial effusion when the entire heart is not being imaged, so it is possible that only pleural effusion is present.

**SEX**

Spayed Female

**PRIMARY FINDINGS**

- Large amount of hypoechoic ascites
- Suspected pericardial or less likely pleural effusion

**AGE**

11 Years

**SECONDARY FINDINGS**

- Reactive hepatopathy

**WEIGHT**

11 Pounds

**INTERPRETATION OF THE FINDINGS & FURTHER RECOMMENDATIONS**

**INTERPRETED BY**

Tam Mengine, DVM,  
DABVP (canine/feline  
practice)

If the effusion in the thorax is indeed a pericardial effusion, this might explain the present of ascites. However, ascites that we would expect secondary to cardiac tamponade would typically be a pure transudate, not a modified transudate, as was identified in this dog. It is also possible that there could be bicavitary mesothelioma, especially given the possibility of an atypical cell on the abdominal fluid cytology. Additional recommendations include:

- Full thoracic and cardiac ultrasound
- Cytology of the fluid that is identified in the thorax
- CT scan of both the thorax and abdomen to further assess for the possibility of metastatic neoplasia, if a definitive diagnosis cannot be achieved via ultrasound and fluid cytology from the thorax.

**IMAGING PERFORMED BY**

Kelly Reschny

**HOSPITAL NAME**

Smithville AH

**REFERRING VET**

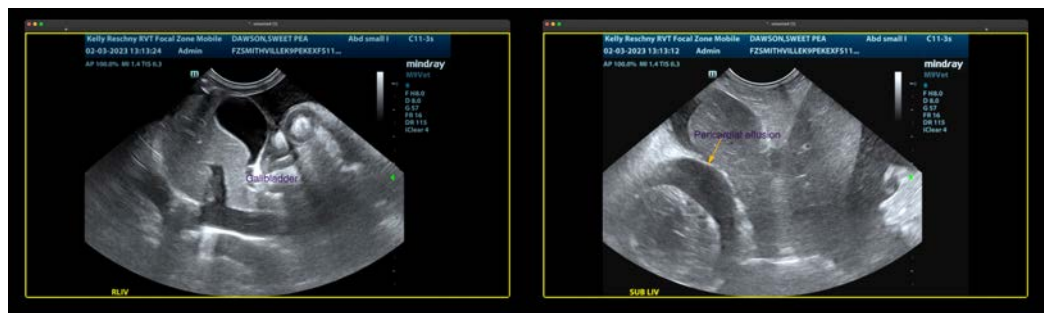
Dr. Hulzebosch

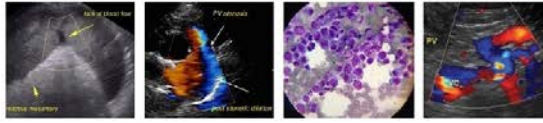
**INVOICE**

44779

**DATE**

2/3/23





**PATIENT**

Sweet Pea Dawson

**SPECIES**

Canine

**BREED**

Pekingese X

**SEX**

Spayed Female

**AGE**

11 Years

**WEIGHT**

11 Pounds

**INTERPRETED BY**

Tam Mengine, DVM,  
DABVP (canine/feline  
practice)

**IMAGING  
PERFORMED BY**

Kelly Reschny

**HOSPITAL NAME**

Smithville AH

**REFERRING VET**

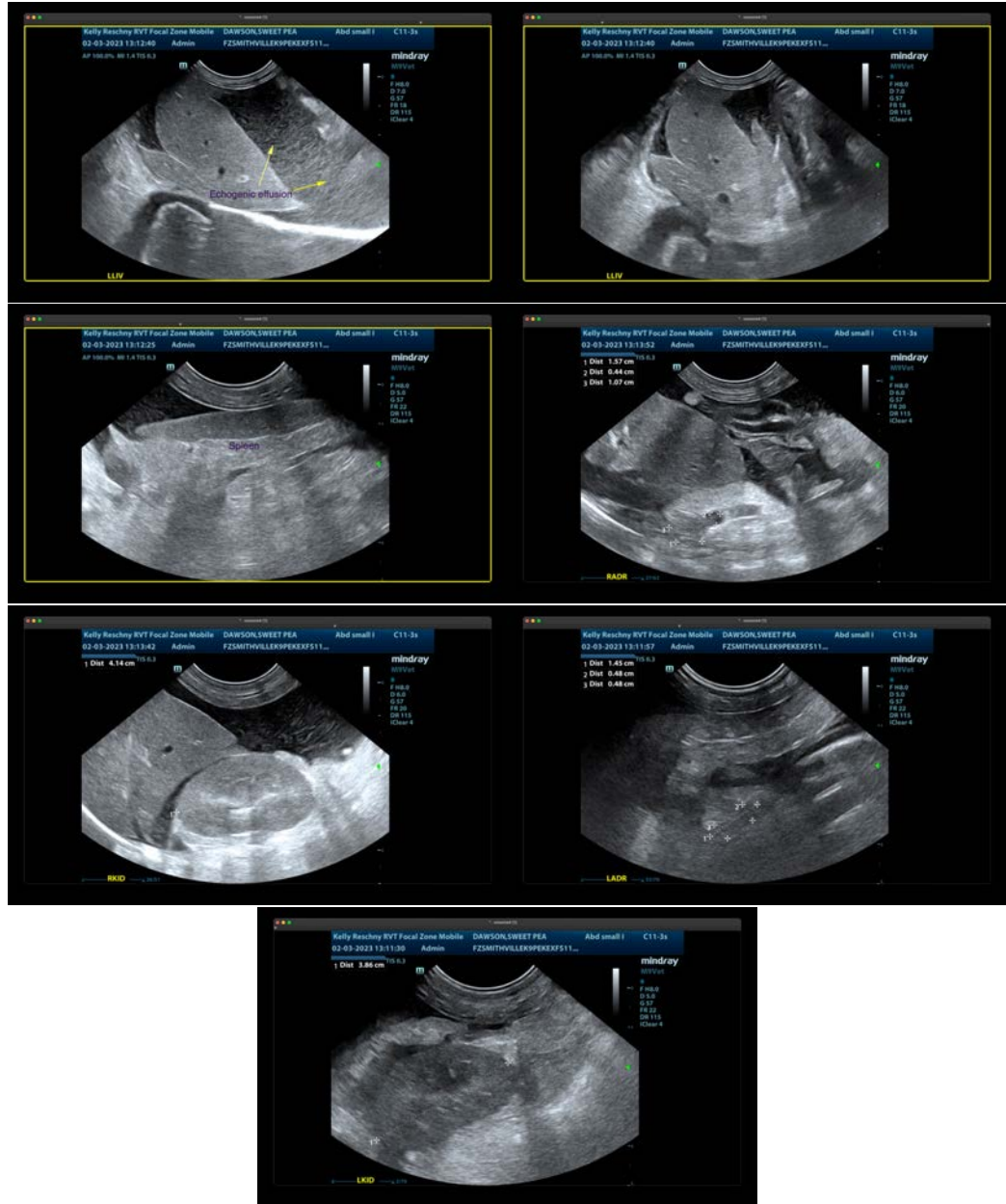
Dr. Hulzebosch

**INVOICE**

44779

**DATE**

2/3/23



The information and recommendations provided are based on the images presented by the referring veterinarian/sonographer. No evaluation can be communicated regarding pathology that was not visible in the image/video clips provided.

Thank you for this referral. If the clinical or image interpretation does not parallel your findings or if I can be of any further assistance please contact me.

**Tam Mengine, DVM, DABVP (canine/feline practice)**

info@SonoPath.com