

Clinical Sonography & Telecytology
Educational Teleconsultation Services™

PATIENT
Nacha Mankin

SPECIES
Canine

BREED
Mix

SEX
Spayed Female

AGE
14 Years

WEIGHT
54 lbs

INTERPRETED BY
Tam Mengine, DVM, DABVP (canine/feline practice)

IMAGING PERFORMED BY
Shari Reffi, CVT

HOSPITAL NAME
All Creatues Great & Small (Denville)

REFERRING VET
Dr. Ashmore

INVOICE
72965

DATE
2/13/26

PRESENTING CLINICAL SIGNS

BCS 4/9. Possible syncope vs seizure. Grade 2/6 heart murmur. No current medications.

Abnormal PE/Chem/CBC/UA Results: Normal

ULTRASONOGRAPHIC EXAMINATION OF THE HEART & ABDOMEN

CANINE CARDIAC PARAMETERS	MR VMAX (m/s)	TR VMAX (m/s)	LA/AO (m-mode long axis)	LA/AO (Heart Base; Swe)	FS (%)	EF (%)	EPSS (cm)
NORMAL PARAMETER	4.5-5.5	<2.7	1.3	Up to 1.6	28-40	40-100	<0.6
PATIENT	6.1	2.3	1.1	1.3	48	NM	0.2
CANINE CARDIAC PARAMETERS	**HR** (BPM)	**AV VMAX** (m/s)	**PV MAX** (m/s)	**BODY WEIGHT** (kg)	**LAD** LA MAX 4 Chamber	**LVIDd** Avg; 2D and m-mode short axis (cm)	**LVIDs** Avg; 2D and m-mode short axis (cm)
NORMAL PARAMETER	50-100	0.7-1.7	0.7-1.6				
PATIENT	NM	0.9	0.6	24.5	3.4	3.5	1.8

Cardiac Presentation

The **left atrium** is of normal size, with no evidence of spontaneous echo contrast or thrombus formation. The **left ventricle** is of normal size and exhibits appropriate systolic function. The **right atrium** is subjectively of normal size and **right ventricular** dimensions and systolic function are subjectively normal. The **mitral valve** exhibits trivial insufficiency of elevated velocity, as might be seen with systemic hypertension, and **the tricuspid valve** exhibits normal appearance and function, with trivial insufficiency noted of normal velocity. No vegetative lesions were seen. The **aortic and pulmonic valves** appear normal, and there is normal laminar flow in the left and right ventricular outflow tracts. The **main pulmonary artery** appears normal. There is no evidence of effusions and no cardiac masses are seen. There is no evidence of an arrhythmia.

Urinary System

The urinary bladder is moderately distended with anechoic urine, and no luminal sediment is present. The ureteral papillae, trigone and pelvic urethra (visible to 3.0 cm) are of normal appearance, and the ureters are not visible (normal). No masses, calculi or mucosal irregularities are noted.

The kidneys are of normal size and shape and exhibit appropriate corticomedullary differentiation with a normal 1:3 cortex to medulla ratio. There is no evidence of nephrolithiasis, mineralization, pyelectasia, cystic change or hydronephrosis. The proximal ureter is not visible (normal). Left kidney measures 6.0 cm. Right kidney measures 6.1 cm.



Clinical Sonography & Telecytology
Educational Teleconsultation Services™

PATIENT
Nacha Mankin

SPECIES
Canine

BREED
Mix

SEX
Spayed Female

AGE
14 Years

WEIGHT
54 lbs

INTERPRETED BY
Tam Mengine, DVM, DABVP (canine/feline practice)

IMAGING PERFORMED BY
Shari Reffi, CVT

HOSPITAL NAME
All Creatues Great & Small (Denville)

REFERRING VET
Dr. Ashmore

INVOICE
72965

DATE
2/13/26

Adrenal Glands

The adrenal glands are both identified in their normal locations. The left adrenal gland is mildly enlarged, measuring 6.8 mm at the cranial pole and 1.3 cm at the caudal pole. There is a heterogeneous mass arising from the caudal pole of the right adrenal gland, measuring 4.5 cm x 4.2 cm. Vascular invasion is not evident.

Spleen

The spleen is of appropriate size and has a normal, homogenous parenchyma with a smooth, continuous capsular surface. The splenic vasculature is normal with no evidence of congestion or thrombosis, and blood flow through the splenic hilus appears normal.

Liver

The liver is of appropriate size and shape, with sharp borders and a mildly coarse parenchymal echotexture that is hypoechoic to the spleen. The portal and hepatic vasculature are of normal size and appearance with no evidence of congestion or thrombosis.

The gallbladder is moderately distended with anechoic contents and a small amount of freely-moveable echogenic sludge. The wall was thin and continuous with no focal lesions. The cystic and common bile ducts are normal / not visible.

Gastrointestinal

The stomach is mildly distended with gas. The gastric wall is 4.8 mm with normal deviations due to rugal folds, and exhibits appropriate wall layering. The pylorus is of normal appearance.

The visualized portions of the duodenum, jejunum, and ileum are of normal thickness with intact wall layering that exhibits the appropriate 1:3 muscularis to mucosa ratio. Intestinal motility appears normal.

The visible portions of the colon are of normal thickness (1.5 mm) with intact wall layering. The ileocecal junction is not seen.

Pancreas

The areas of the limbs and body of the pancreas are isoechoic to the surrounding mesenteric fat, with normal capsular appearance. There is no evidence of peripancreatic inflammation. The pancreatic duct appears normal.

Free Abdomen

There is no evidence of free fluid within the peritoneal cavity. The omentum and intra-abdominal fat are of appropriate echogenicity. Enlarged abdominal lymph nodes are not observed. The aortic trifurcation has normal blood flow with no evidence of thrombosis.

PRIMARY FINDINGS

- Structurally and functionally normal canine heart
- Elevated mitral regurgitant velocity, which may indicate systemic hypertension
- Right mass
- Mildly enlarged left adrenal gland

PATIENT

Nacha Mankin

SPECIES

Canine

BREED

Mix

SEX

Spayed Female

AGE

14 Years

WEIGHT

54 lbs

INTERPRETED BY

Tam Mengine, DVM, DABVP (canine/feline practice)

IMAGING PERFORMED BY

Shari Reffi, CVT

HOSPITAL NAME

All Creatues Great & Small (Denville)

REFERRING VET

Dr. Ashmore

INVOICE

72965

DATE

2/13/26

INTERPRETATION OF THE FINDINGS & FURTHER RECOMMENDATIONS

If the right adrenal gland represents a pheochromocytoma, then this would be the likely cause of the patient's syncopal episode. Given that the left adrenal is also enlarged, the possibility of a pituitary macroadenoma leading to seizures would also be a consideration. Suggested next steps include:

- Obtaining a systemic blood pressure measurement when the patient is calm – providing pre-med sedation such as gabapentin may be helpful toward that end. Trazodone would be contraindicated if a seizure disorder is possible.
- An ECG (or possibly a Holter study) is recommended, as syncopal episodes associated with pheochromocytomas often occur secondary to arrhythmias.
- Three-view thoracic radiographs to screen for metastatic disease
- Urine catecholamine levels are indicated to further investigate the possibility of a pheochromocytoma
- Testing for Cushing's disease is recommended only if there are overy symptoms, such as polyuria and polydipsia, to support the diagnosis.
- No cardiac medications are indicated at this time. While this patient is not at increased risk for heart disease, they could develop acquired heart disease in the future just as any dog might. Thus, if the murmur increases in intensity, or symptoms of heart disease occur, a recheck echocardiogram would be recommended.

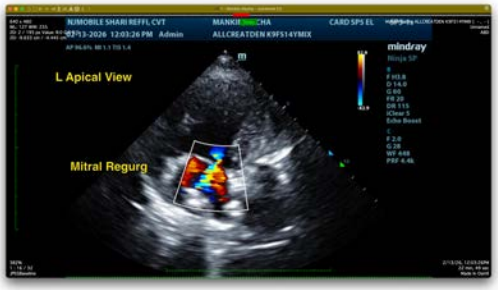

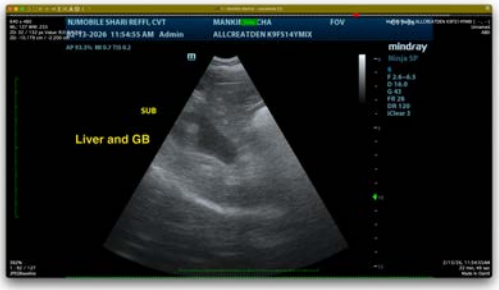

New Jersey Mobile
FUELED BY SONOPATH VETERINARY ULTRASOUND

SonoPath
www.SonoPath.com
info@sonopath.com 800.838.4268



Clinical Sonography & Telecytology
Educational Teleconsultation Services™

PATIENT

Nacha Mankin

SPECIES

Canine

BREED

Mix

SEX

Spayed Female

AGE

14 Years

WEIGHT

54 lbs

INTERPRETED BY

Tam Mengine, DVM, DABVP (canine/feline practice)

IMAGING PERFORMED BY

Shari Reffi, CVT

HOSPITAL NAME

All Creatues Great & Small (Denville)

REFERRING VET

Dr. Ashmore

INVOICE

72965

DATE

2/13/26

The information and recommendations provided are based on the images presented by the referring veterinarian/sonographer. No evaluation can be communicated regarding pathology that was not visible in the image/video clips provided.

Thank you for this referral. If the clinical or image interpretation does not parallel your findings or if I can be of any further assistance please contact me.

Tam Mengine, DVM, DABVP (canine/feline practice)

info@SonoPath.com