



PATIENT

Josie Sealy

PRESENTING CLINICAL SIGNS

Chronic wt loss, recent daily vomiting. CBC / Chem / T4 - slightly elevated total Ca⁺⁺, else unremarkable. U/A pending

SPECIES

Feline

ULTRASONOGRAPHIC EXAMINATION OF THE ABDOMEN

Urinary System

The urinary bladder is moderately distended with anechoic urine, and no luminal sediment is present. The ureteral papillae, trigone and pelvic urethra (visible to 3.0 cm) are of normal appearance, and the ureters are not visible (normal). No masses, calculi or mucosal irregularities are noted.

BREED

DSH

The kidneys are of normal size and shape and exhibit appropriate corticomedullary differentiation with a normal 1:3 cortex to medulla ratio. There is no evidence of nephrolithiasis, mineralization, pyelectasia, cystic change or hydronephrosis. The proximal ureter is not visible (normal). The left kidney measures 3.8 cm. The right kidney measures 3.6 cm.

SEX

Spayed Female

Adrenal Glands

AGE

15 Years

The adrenal glands are both identified in their normal locations. They are normal in size and shape with appropriate parenchymal echogenicity and normal phrenic vasculature. The adrenals measure 2.9 mm each.

WEIGHT

10.3 Pounds

Spleen

The spleen is of appropriate size (9.6 mm) and has a normal, homogenous parenchyma with a smooth, continuous capsular surface. The splenic vasculature is normal with no evidence of congestion or thrombosis, and blood flow through the splenic hilus appears normal. Thickness at the splenic hilus is normal.

INTERPRETED BY

Kathleen Sennello DVM,
MS, Diplomate ACVIM
(Small Animal Internal
Medicine)

Liver

The liver is of appropriate size and shape, with sharp borders and a mildly coarse parenchymal echotexture that is hypoechoic to the spleen. The portal and hepatic vasculature are of normal size and appearance with no evidence of congestion or thrombosis.

IMAGING PERFORMED BY

Dr. Tam Mengine

The gallbladder is moderately distended with anechoic contents. The wall was thin and continuous with no focal lesions. The cystic and common bile ducts are normal / not visible.

Gastrointestinal

HOSPITAL NAME

Stoney Creek VH

The stomach is empty. The gastric wall is normal in thickness (3.0 mm) with normal deviations due to rugal folds and exhibits appropriate wall layering. The pylorus is of normal appearance.

The small bowel has diffuse changes to the normal 1:3 muscularis to mucosa ratio. Wall measurements are increased up to 2.5 mm for duodenum and 3.9 mm for jejunum. Overall wall layering is preserved. Intestinal motility appears normal. The duodenum is diffusely corrugated.

REFERRING VET

Dr. Tam Mengine

The visible portions of the colon are of normal thickness (1.0 mm) with intact wall layering. The ileocecal junction is visualized and normal.

INVOICE

43608

Pancreas

The areas of the limbs and body of the pancreas are isoechoic to the surrounding mesenteric fat, with normal capsular appearance. There is no evidence of peripancreatic inflammation. The pancreatic duct appears normal.

DATE

12/20/22



PATIENT

Josie Sealy

Free Abdomen

There is no evidence of free fluid within the peritoneal cavity. The omentum and intra-abdominal fat are of appropriate echogenicity. Enlarged abdominal lymph nodes are not observed. The aortic trifurcation has normal blood flow with no evidence of thrombosis.

SPECIES

Feline

ULTRASONOGRAPHIC FINDINGS

- Diffusely thickened small intestines – consistent with infiltrative bowel disease.

BREED

DSH

INTERPRETATION OF THE FINDINGS & FURTHER RECOMMENDATIONS

The changes in the gastrointestinal tract are suggestive of infiltrative bowel disease, including both inflammatory bowel disease or low grade gastrointestinal lymphoma. Recommendations include:

SEX

Spayed Female

- ❖ fecal parasite testing and empiric fenbendazole treatment
- ❖ trials with a novel protein or hydrolyzed diet
- ❖ A complete GI panel, or empiric cobalamin supplementation
- ❖ Empiric therapy with prednisolone at 2-4mg / kg daily could be considered if a diet trial is unsuccessful.
- ❖ Definitive diagnosis would require biopsy of the affected tissue, ideally with intra-operative ultrasonographic guidance . If there is concurrent lymphadenopathy, ultrasound-guided sampling of the lymph node using a 25 or 22G needle could be considered.

AGE

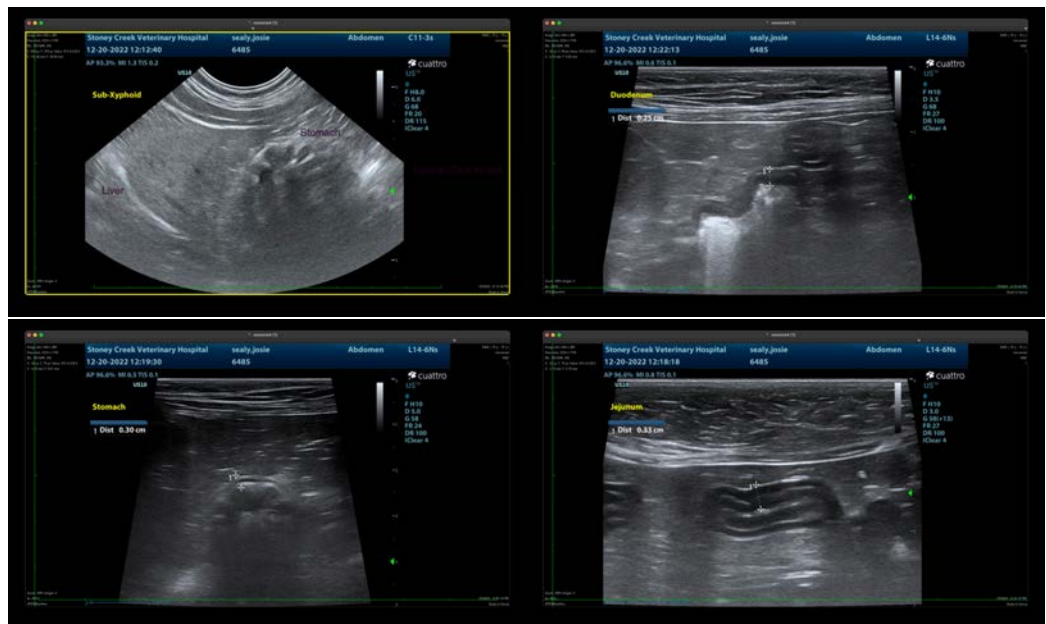
15 Years

WEIGHT

10.3 Pounds

INTERPRETED BY

Kathleen Sennello DVM,
MS, Diplomate ACVIM
(Small Animal Internal
Medicine)



IMAGING PERFORMED BY

Dr. Tam Mengine

HOSPITAL NAME

Stoney Creek VH

REFERRING VET

Dr. Tam Mengine

INVOICE

43608

DATE

12/20/22



PATIENT

Josie Sealy

SPECIES

Feline

BREED

DSH

SEX

Spayed Female

AGE

15 Years

WEIGHT

10.3 Pounds

INTERPRETED BY

Kathleen Sennello DVM,
MS, Diplomate ACVIM
(Small Animal Internal
Medicine)

**IMAGING
PERFORMED BY**

Dr. Tam Mengine

HOSPITAL NAME

Stoney Creek VH

REFERRING VET

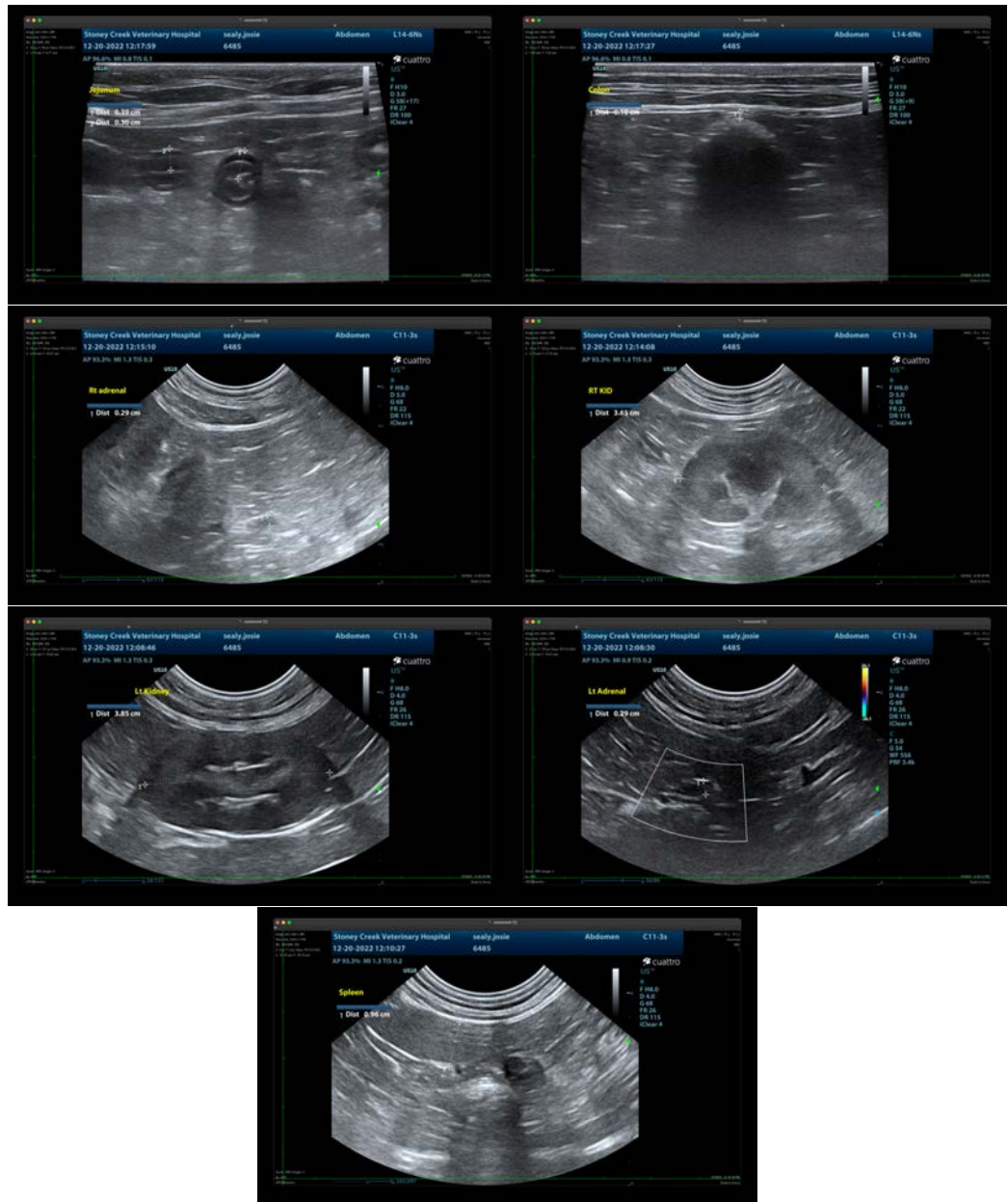
Dr. Tam Mengine

INVOICE

43608

DATE

12/20/22



The information and recommendations provided are based on the images presented by the referring veterinarian/sonographer. No evaluation can be communicated regarding pathology that was not visible in the image/video clips provided.

Thank you for this referral. If the clinical or image interpretation does not parallel your findings or if I can be of any further assistance please contact me.

Tam Mengine, DVM, DABVP (canine/feline practice)

info@SonoPath.com