



## PATIENT

Linus Wilkerson

## SPECIES

Feline

## BREED

DSH

## SEX

Neutered Male

## AGE

14 Years

## WEIGHT

10.6 Pounds

## INTERPRETED BY

Tam Mengine, DVM,  
DABVP (canine/feline  
practice)

## IMAGING PERFORMED BY

Nicole Hession

## HOSPITAL NAME

VEC Oakland

## REFERRING VET

Dr. Trewartha

## INVOICE

35577

## DATE

11/23/25

## PRESENTING CLINICAL SIGNS

History: Linus started becoming lethargic and had a decreased appetite which started 3 days ago. P has a heart murmur. P did eat in hospital yesterday.

Abnormal PE/Chem/CBC/UA Results: P went to his primary vet 3 days ago where full bloodwork, urinalysis, and thoracic radiographs were performed. Bloodwork was unremarkable. Urinalysis revealed a low USG 1.015 but was otherwise unremarkable. Pancreatic lipase elevated.

## ULTRASONOGRAPHIC EXAMINATION OF THE HEART & ABDOMEN

FELINE CARDIAC PARAMETERS	BODY WEIGHT (kg)	HR (BPM)	IVSd (cm)	LVIDd (cm)	LVWd (cm)	FS (%)	EF (%)
NORMAL PARAMETER	-----	150-240	0.3-0.6	1.0-2.1	0.25-0.6	35-67	80-100
PATIENT	4.8	216	0.4	1.6	0.5	67	NM
FELINE CARDIAC PARAMETERS	LA/AO (m-mode long axis)	LA/AO HEART BASE (Sisson)	LAD LA MAX 4 Chamber		LVOT VEL. (m/s)	RVOT VEL. (m/s)	IVRT (m/)
NORMAL PARAMETER	<1.5	1.6	0.7-1.7		<1.6	<1.3	40-60
PATIENT	NM	1.2	1.3		NM	0.8	NM
Adapted from June Boon, Veterinary Echocardiography, 1998 Sisson D et al. JVIM 1991; 5: 232, Jacobs et al. Am J Vet Res 1985; 46:1705							

## Cardiac Presentation

The **left atrium** is of normal size with no evidence of spontaneous echocardiographic contrast or thrombus formation. The **left ventricle** is normal in diameter, with focal thickening at the basilar interventricular septum (0.67 cm), with the walls of otherwise normal thickness in diastole, and demonstrates good systolic function. The **right atrium** is subjectively of normal size and **right ventricle** dimensions, and systolic function are subjectively normal. There was no evidence of chordae tendineae rupture or valvular prolapse in either valve, and no vegetative lesions were seen. There is mild **mitral** regurgitation identified (too small a quantity for accurate velocity measurement). The **tricuspid**, **aortic** and **pulmonary valves** all exhibit normal appearance and function. The **main pulmonary artery** appears normal. There is no evidence of pulmonary hypertension. There is no evidence of pericardial or pleural effusion, and no masses are seen.

## Urinary System

The urinary bladder is moderately distended with anechoic urine. A small amount of echogenic luminal material is present, typical of mucus. The ureteral papillae, trigone and pelvic urethra are of normal



## PATIENT

Linus Wilkerson

## SPECIES

Feline

## BREED

DSH

## SEX

Neutered Male

## AGE

14 Years

## WEIGHT

10.6 Pounds

## INTERPRETED BY

Tam Mengine, DVM,  
DABVP (canine/feline  
practice)

## IMAGING PERFORMED BY

Nicole Hession

## HOSPITAL NAME

VEC Oakland

## REFERRING VET

Dr. Trewartha

## INVOICE

35577

## DATE

11/23/25

appearance, and the ureters are not visible (normal). No masses, calculi or mucosal irregularities are noted. Urethra visualized to 1.0 cm.

Both kidneys are hyperechoic and exhibit mildly decreased cortico-medullary differentiation with a medullary rim sign. There is no evidence of nephrolithiasis, mineralization, pyelectasia or hydronephrosis. The proximal ureters are not visible (normal). The left kidney is 4.1 cm in length. The right kidney is 4.1 cm in length.

### **Adrenal Glands**

The adrenal glands are both identified in their normal locations. They are normal in size and shape with appropriate parenchymal echogenicity and normal phrenic vasculature. The left adrenal gland height is 4.1 mm at the caudal pole. The right adrenal gland height 3.2 mm at the caudal pole.

### **Spleen**

The spleen is of appropriate size and has a normal, homogenous parenchyma with a smooth, continuous capsular surface. The splenic vasculature is normal with no evidence of congestion or thrombosis, and blood flow through the splenic hilus appears normal. Thickness at the splenic hilus is normal at 8.6 cm.

### **Liver**

The liver is of appropriate size and shape, with sharp borders and a mildly coarse parenchymal echotexture that is hypoechoic to the spleen. There are two microcystic masses noted within the liver; a 1.2 cm x 7.4 mm mass in the left caudal liver, and a 2.8 cm x 2.3 cm mass in the cranial mid liver. The surrounding omentum is normal. The portal and hepatic vasculature are of normal size and appearance with no evidence of congestion or thrombosis.

The gallbladder is moderately distended with anechoic contents and a small amount of freely moveable echogenic sludge. The wall was thin and continuous with no focal lesions. The cystic and common bile ducts are normal / not visible.

### **Gastrointestinal**

The stomach is empty. The gastric wall is 2.6 mm with normal deviations due to rugal folds and exhibits appropriate wall layering. The pylorus is of normal appearance.

The small bowel has diffuse changes to the normal 1:3 muscularis to mucosa ratio. Wall measurements are increased up to 3.0 mm for duodenum and 3.7 mm for jejunum. Overall wall layering is preserved. Intestinal motility appears normal.

The visible portions of the colon are of normal thickness, up to 1.4 mm, with intact wall layering. The ileocecal junction is visualized and appears normal.

### **Pancreas**

Both limbs of the pancreas are swollen and hypoechoic, surrounded by hyperechoic mesenteric fat. The pancreatic ducts appear normal.

### **Free Abdomen**



## PATIENT

Linus Wilkerson

## SPECIES

Feline

## BREED

DSH

## SEX

Neutered Male

## AGE

14 Years

## WEIGHT

10.6 Pounds

## INTERPRETED BY

Tam Mengine, DVM,  
DABVP (canine/feline  
practice)

## IMAGING PERFORMED BY

Nicole Hession

## HOSPITAL NAME

VEC Oakland

## REFERRING VET

Dr. Trewartha

## INVOICE

35577

## DATE

11/23/25

There is no free fluid noted within the abdomen. There is hyperechoic, inflamed omental fat noted in the region of the pancreas. Enlarged abdominal lymph nodes are not observed. The aortic trifurcation has normal blood flow with no evidence of thrombosis.

## ULTRASONOGRAPHIC FINDINGS

- Diffusely thickened small bowel, typical of infiltrative bowel disease
- Hypoechoic pancreas with steatitis, typical of pancreatitis
- Multiple microcystic liver masses, which may represent benign cystadenomas or malignancy such as cystadenocarcinomas.
- Small amount of gallbladder sludge, which may be incidental but may also indicate cholecystitis in the cat
- Mild chronic renal changes with incidental medullary rim sign
- Heart - Discrete Upper Septal Thickening ("DUST")

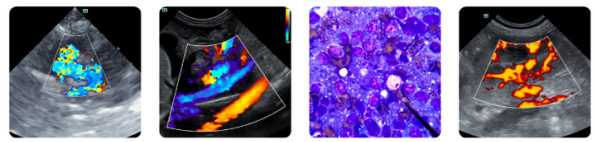
## INTERPRETATION OF THE FINDINGS & FURTHER RECOMMENDATIONS

Definitive diagnosis of the change in intestines, pancreas and liver would require biopsy of the affected tissues. The changes in the gastrointestinal tract are suggestive of infiltrative bowel disease, including both inflammatory bowel etiologies (food allergy, lymphoplasmacytic enteritis, eosinophilic enteritis) or low-grade gastrointestinal lymphoma. Given the appearance of the pancreas, there is likely concurrent pancreatitis, and the possibility of "triaditis" syndrome cannot be excluded, but hepatic involvement is deemed less likely with the normal cholestatic enzymes and lack of inflammation in the region. Additional recommendations include:

- Fecal parasite testing and empiric fenbendazole treatment
- Trials with a novel protein or hydrolyzed diet
- A complete GI panel, or empiric cobalamin supplementation
- Empiric therapy with prednisolone or budesonide could be considered if a diet trial is unsuccessful. Anti-inflammatory doses are suggested, at least initially, due to the small risk of emerging HCM.

The echocardiographic findings are consistent with a phenomenon known as "Isolated DUST," consisting of a focal thickening of the heart wall near where the aorta leaves the left ventricle. DUST is sometimes associated with hypertrophic cardiomyopathy, but may also occur as its own entity, and in the absence of cardiomyopathy, it does not affect longevity.

- There is no medication warranted at this time.
- Recheck echocardiogram is recommended in 6 -12 months time, to determine whether there has been progression to a hypertrophic cardiomyopathy phenotype.
- Corticosteroids should be used cautiously, with the client monitoring the patient's sleeping respiratory. The lowest effective dose needed to control clinical signs is recommended.
- Serial monitoring with proBNP may help provide evidence of disease progression in the absence of echocardiogram, and if there is significant progression of proBNP levels, then an urgent recheck echocardiogram would be indicated.
- If anesthesia is needed, then the following recommendations would apply:



**PATIENT**

Linus Wilkerson

**SPECIES**

Feline

**BREED**

DSH

**SEX**

Neutered Male

**AGE**

14 Years

**WEIGHT**

10.6 Pounds

**INTERPRETED BY**

Tam Mengine, DVM,  
DABVP (canine/feline  
practice)

**IMAGING  
PERFORMED BY**

Nicole Hession

**HOSPITAL NAME**

VEC Oakland

**REFERRING VET**

Dr. Trewartha

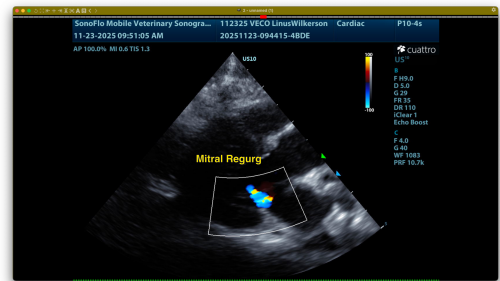
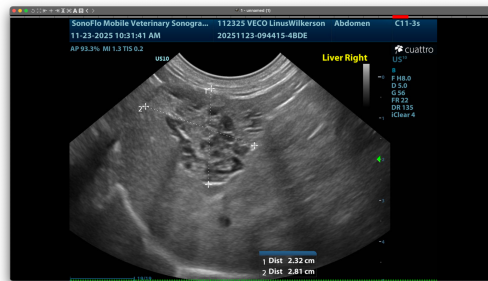
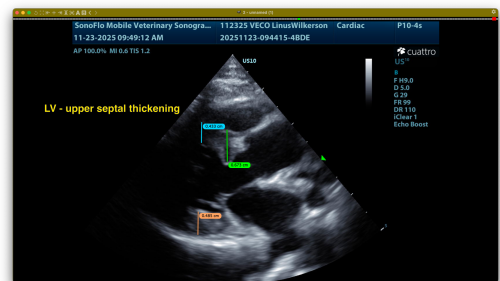
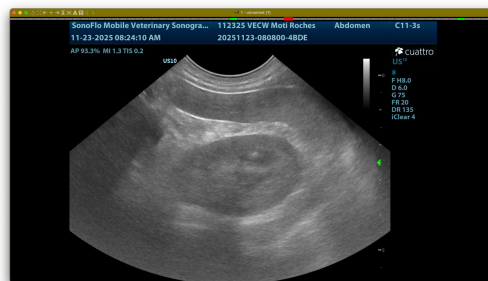
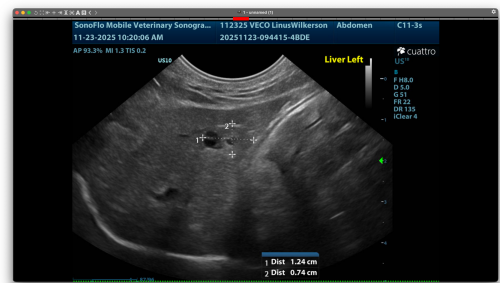
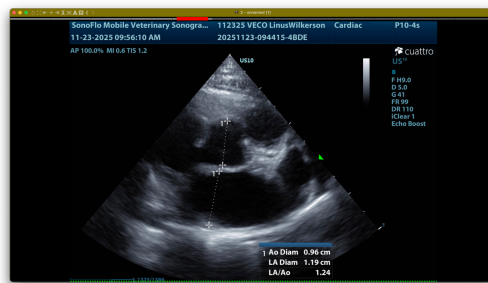
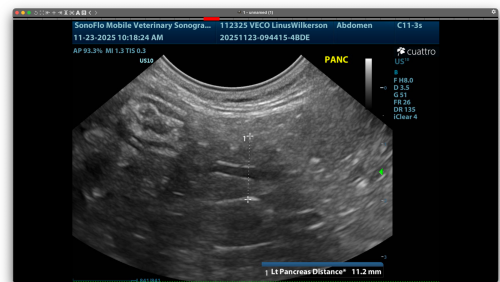
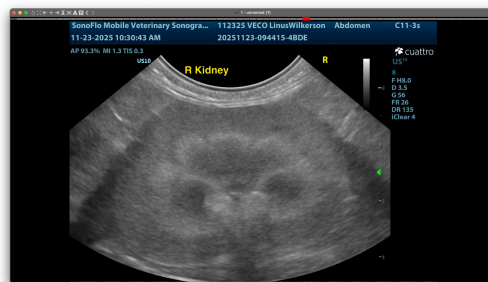
**INVOICE**

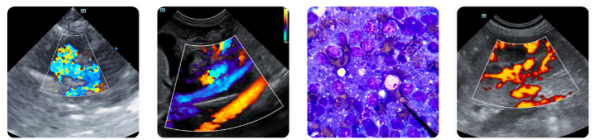
35577

**DATE**

11/23/25

1. Avoid drugs that may cause tachycardia, such as ketamine, xylazine, atropine and glycopyrrolate. Atropine or glycopyrrolate can be used if the HR falls below 130 and blood pressure is low during the procedure.
2. Pre-medicate with an opiate, and if needed a benzodiazepine. Oral gabapentin 2 hours prior to the procedure can also help lessen anesthetic needs.
3. Induction with propofol or alfaxalone
4. Maintenance anesthesia on isoflurane or sevoflurane
5. IV fluids should be used at modest doses, starting at 2ml/kg/hr.
6. Continuous monitoring of ECG, pulse ox and blood pressure is recommended.





## PATIENT

Linus Wilkerson

## SPECIES

Feline

## BREED

DSH

## SEX

Neutered Male

## AGE

14 Years

## WEIGHT

10.6 Pounds

## INTERPRETED BY

Tam Mengine, DVM,  
DABVP (canine/feline  
practice)

## IMAGING PERFORMED BY

Nicole Hession

## HOSPITAL NAME

VEC Oakland

## REFERRING VET

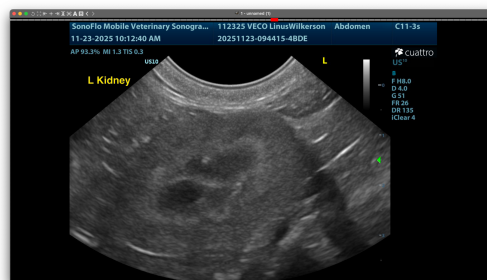
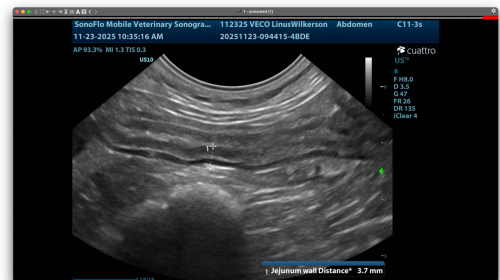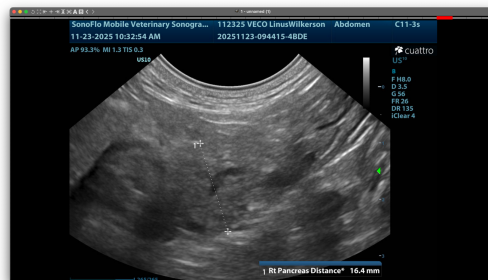
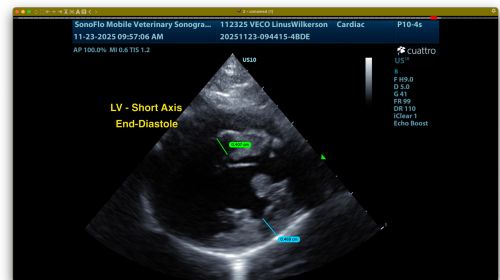
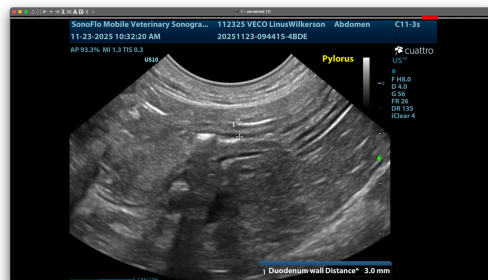
Dr. Trewartha

## INVOICE

35577

## DATE

11/23/25



The information and recommendations provided are based on the images presented by the referring veterinarian. No evaluation can be communicated regarding pathology that was not visible in the image/video clips provided.

Thank you for this referral. If the clinical or image interpretation does not parallel your findings or if I can be of any further assistance please contact me.

Tam Mengine, DVM, DABVP (canine/feline practice)

info@SonoPath.com