



**PATIENT**

Samira Vizcarrondo

**SPECIES**

Feline

**BREED**

Domestic Shorthair

**SEX**

Spayed female

**AGE**

9 years

**WEIGHT**

7.4 lbs

**INTERPRETED BY**

Tam Mengine, DVM,  
DABVP (canine/feline  
practice)

**IMAGING  
PERFORMED BY**

Dr. Hudgins

**HOSPITAL NAME**

Petvacx AH

**REFERRING VET**

Dr. Wiley

**INVOICE**

42075

**DATE**

10/24/22

**PRESENTING CLINICAL SIGNS**

History: Intermittent vomiting for many years, usually just after eating, sometimes hairballs  
Abnormal PE/Chem/CBC/UA Results: Bloodwork Within Normal Limits CBC, CHEM, T4, UA

**ULTRASONOGRAPHIC EXAMINATION OF THE ABDOMEN**

**Urinary System**

The urinary bladder is moderately distended with anechoic urine. A small amount of echogenic luminal sediment is present, which is freely movable. The ureteral papillae, trigone and pelvic urethra are of normal appearance, and the ureters are not visible (normal). No masses, calculi or mucosal irregularities are noted. Urethra visualized to (2.0) cm

The kidneys are of normal size and shape and exhibit appropriate corticomedullary differentiation with a normal 1:3 cortex to medulla ratio. There is no evidence of nephrolithiasis, mineralization, pyelectasia, cystic change or hydronephrosis. The proximal ureter is not visible (normal). The left kidney is (3.5) cm in length. The right kidney is (3.2) cm in length.

**Adrenal Glands**

The adrenal glands are both identified in their normal locations. They are normal in size and shape with appropriate parenchymal echogenicity and normal phrenic vasculature. The left adrenal gland height is (3.1) mm at the caudal pole. The right adrenal gland height (3.1) mm at the caudal pole.

**Spleen**

The spleen is of appropriate size and has a normal, homogenous parenchyma with a smooth, continuous capsular surface. The splenic vasculature is normal with no evidence of congestion or thrombosis, and blood flow through the splenic hilus appears normal. Thickness at the splenic hilus is normal at (9.1) cm).

**Liver**

The liver is of appropriate size and shape, with sharp borders and a mildly coarse parenchymal echotexture that is hypoechoic to the spleen. The portal and hepatic vasculature are of normal size and appearance with no evidence of congestion or thrombosis.

The gallbladder is minimally distended with anechoic contents and a small amount of freely-moveable echogenic sludge. The wall was thin and continuous with no focal lesions. The cystic and common bile ducts are normal / not visible.

**Gastrointestinal**

The stomach is mildly distended with anechoic fluid. The gastric wall is (2.2) mm with normal deviations due to rugal folds, and exhibits appropriate wall layering. The pylorus is of normal appearance.



|  |   |
|--|---|
| <b>PATIENT</b>   | The visualized portions of the duodenum, jejunum, and ileum are of normal thickness with intact wall layering that exhibits the appropriate 1:3 muscularis to mucosa ratio. The duodenal wall measures (2.4) mm. The jejunal wall measures up to (2.3) mm. Intestinal motility appears normal.  |
| Samira Vizcarrondo                                     |   |
| <b>SPECIES</b>   | The visible portions of the colon are of normal thickness, up to (1.2) mm, with intact wall layering. The ileocecal junction is visualized and appears normal.  |
| Feline   |   |
| <b>BREED</b>   | <b><i>Pancreas</i></b>  |
| Domestic Shorthair                                     | The pancreas is hypochoic, but of normal size and with no changes to the surrounding mesenteric fat. There is no evidence of peripancreatic inflammation. The pancreatic duct appears normal.   |
| <b>SEX</b>   | <b><i>Free Abdomen</i></b>  |
| Spayed female  | There is no evidence of free fluid within the peritoneal cavity. The omentum and intra-abdominal fat are of appropriate echogenicity. Enlarged abdominal lymph nodes are not observed. The aortic trifurcation has normal blood flow with no evidence of thrombosis.  |
| <b>AGE</b>   |   |
| 9 years  |   |
| <b>WEIGHT</b>  | <b>ULTRASONOGRAPHIC FINDINGS</b>  |
| 7.4 lbs  | <b>PRIMARY FINDINGS:</b>  |
| <b>INTERPRETED BY</b>                                  | <ul style="list-style-type: none"> <li>Hypochoic pancreas, which may indicate previous episodes of pancreatitis, but may also be a normal variant in a cat.</li> </ul>  |
| Tam Mengine, DVM,<br>DABVP (canine/feline<br>practice) | <b>SECONDARY FINDINGS:</b>  |
| <b>IMAGING<br/>PERFORMED BY</b>                        | <ul style="list-style-type: none"> <li>Small amount of gallbladder sludge.</li> </ul>   |
| Dr. Hudgins  | <b><u>INTERPRETATION OF THE FINDINGS &amp; FURTHER RECOMMENDATIONS</u></b>  |
| <b>HOSPITAL NAME</b>                                   | The changes in the pancreas are mild and may be a normal variation in this cat, but given the long history of intermittent vomiting chronic pancreatitis is also a consideration. Inflammatory bowel disease may also be present with a normal ultrasound, thus the following additional recommendations include:   |
| Petvacx AH   | The changes in the pancreas are consistent with acute pancreatitis. Concurrent pancreatic neoplasia, while less likely, cannot be ruled out. Recommendations include:   |
| <b>REFERRING VET</b>                                   | <ul style="list-style-type: none"> <li>❖ an fPLI, or preferably a full GI panel, are indicated for confirmation and to screen for concurrent intestinal disease.</li> <li>❖ supportive care including fluid therapy, antiemetics, analgesics, appetite stimulants (if needed) and cobalamin supplementation are warranted.</li> <li>❖ a highly digestible intestinal diet is recommended.</li> <li>❖ if the patient is not responding to medical management, fine needle aspiration with a 25G needle for cytology could be considered after first checking a coagulation profile.</li> </ul> |
| Dr. Wiley  |   |
| <b>INVOICE</b>   |   |
| 42075  |   |
| <b>DATE</b>  |   |
| 10/24/22   |   |



**PATIENT**

Samira Vizcarrondo

**SPECIES**

Feline

**BREED**

Domestic Shorthair

**SEX**

Spayed female

**AGE**

9 years

**WEIGHT**

7.4 lbs

**INTERPRETED BY**

Tam Mengine, DVM,  
DABVP (canine/feline  
practice)

**IMAGING  
PERFORMED BY**

Dr. Hudgins

**HOSPITAL NAME**

Petvax AH

**REFERRING VET**

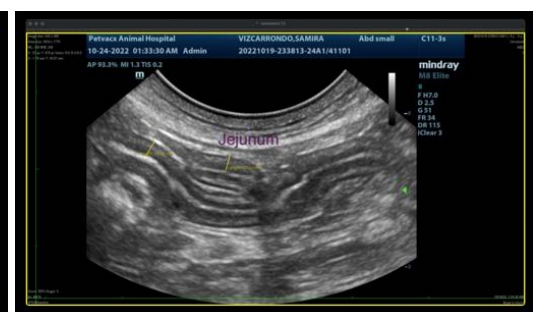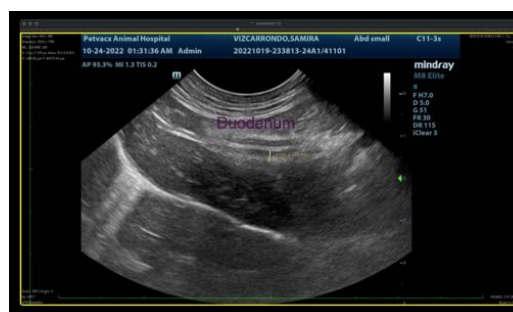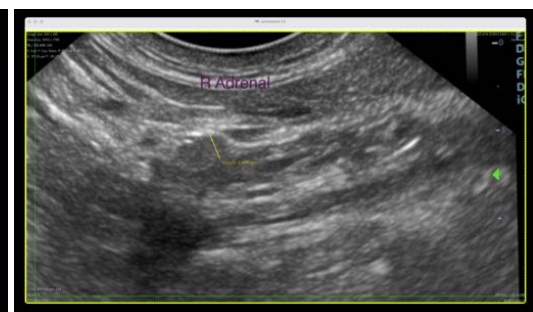
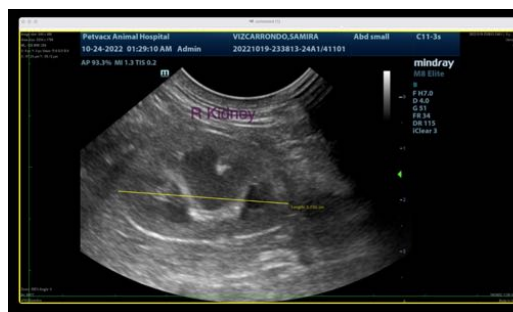
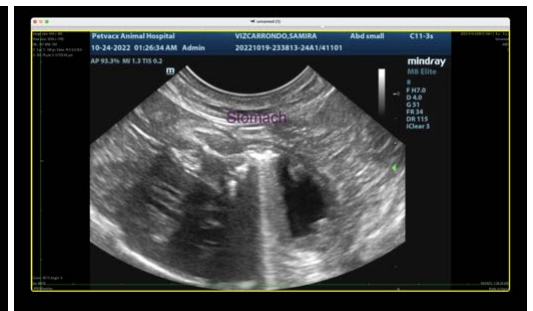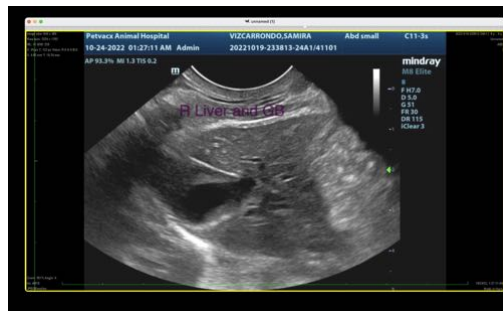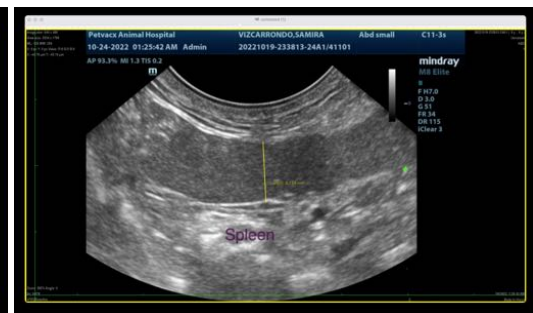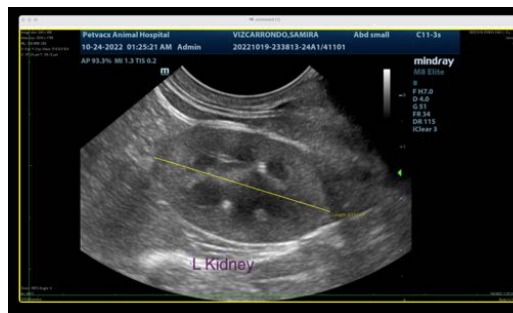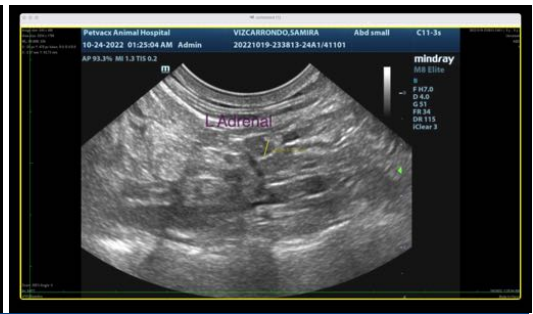
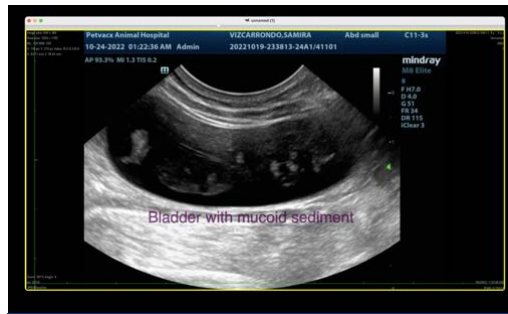Dr. Wiley

**INVOICE**

42075

**DATE**

10/24/22





**PATIENT**

Samira Vizcarrondo

**SPECIES**

Feline

**BREED**

Domestic Shorthair

**SEX**

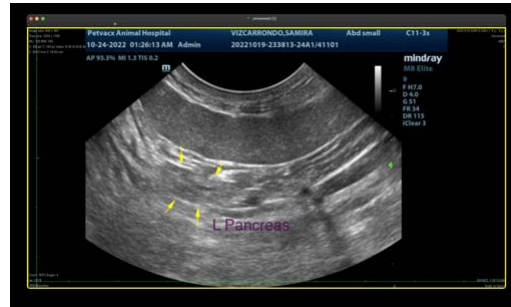Spayed female

**AGE**

9 years

**WEIGHT**

7.4 lbs



The information and recommendations provided are based on the images presented by the referring veterinarian/sonographer. No evaluation can be communicated regarding pathology that was not visible in the image/video clips provided.

Thank you for this referral. If the clinical or image interpretation does not parallel your findings or if I can be of any further assistance please contact me.

**Tam Mengine, DVM, DABVP (canine/feline practice)**

info@SonoPath.com

**INTERPRETED BY**

Tam Mengine, DVM,  
DABVP (canine/feline  
practice)

**IMAGING  
PERFORMED BY**

Dr. Hudgins

**HOSPITAL NAME**

Petvacc AH

**REFERRING VET**

Dr. Wiley

**INVOICE**

42075

**DATE**

10/24/22