



PATIENT

Luna Hebden

SPECIES

Canine

BREED

Dachshund

SEX

Spayed Female

AGE

5 Years

WEIGHT

5.07 kg

INTERPRETED BY

Tam Mengine, DVM,
DABVP (canine/feline
practice)

IMAGING PERFORMED BY

Dr. Meghan Myers

HOSPITAL NAME

Hershey Animal
Emergency Center

REFERRING VET

Dr. Victoria Orlando

INVOICE

12935

DATE

01/03/2026

PRESENTING CLINICAL SIGNS

Presented 1/2 as a transfer from rDVM for bicavitary effusion. P presented to rDVM for acute heavy/abdominal breathing since Wednesday. O has been out of the country for the last 3 weeks and P has been with pet sitter during that time, returning to the O's care on 12/31. Decreased appetite and difficulty ambulating since returning. P was hospitalized and thoracocentesis done - 150 ml removed Mild increased RE Bruising on right front cephalic and ventral abdomen (suspect from previous cystocentesis).

Abnormal PE/Chem/CBC/UA Results: 1/2 @ rDVM CBC: mild-moderate thrombocytopenia (105k) Chem: BG 72 (L), Glob 4.6 (N), Alb 2.8 (N) 1/2 @ HAEC POCUS: marked pleural effusion; mild abdominal effusion; no pericardial effusion. Pulse oximetry: SpO2 98% on room air (adequate oxygenation at presentation). EPOC: BUN 6 (L) Creatinine 0.31 (L) PT/PTT: PT error, PTT normal Pancreatic Lipase: WNL Conclusions: 1. Bicavitary effusion. 2. No evidence of cardiomegaly. 3. No mass effect is identified in the abdomen. No specific abnormalities are identified in the G.I. tract. 4. Multifocal in situ intervertebral disc mineralization. EPOC: BUN 4 (L), Crea 0.39 (L) PCV/TS: 38/7.8 BP: 172 (doppler) Thoracic fluid PCV/TS: 2.0/5.0 Cytology: Protein rich transudate suspected, no overt features of malignancy observed

ULTRASONOGRAPHIC EXAMINATION OF THE ABDOMEN

Urinary System

The urinary bladder is moderately distended with anechoic urine, and no luminal sediment is present. The ureteral papillae, trigone and pelvic urethra (visible to 2.0 cm) are of normal appearance, and the ureters are not visible (normal). No masses, calculi or mucosal irregularities are noted.

The kidneys are of normal size and shape and exhibit appropriate corticomedullary differentiation with a normal 1:3 cortex to medulla ratio. There is no evidence of nephrolithiasis, mineralization, pyelectasia, cystic change or hydronephrosis. The proximal ureter is not visible (normal). The left kidney measured 5.2 cm in length. The right kidney measured 5.2 cm in length.

Adrenal Glands

The adrenal glands are both identified in their normal locations. They are normal in size and shape with appropriate parenchymal echogenicity and normal phrenic vasculature. The left adrenal gland measured 4.3 mm width at the cranial pole and 6.0 mm width at the caudal pole. The right adrenal gland measured 6.9 mm width at the cranial pole and 6.3 mm width at the caudal pole.

Spleen

The spleen is of appropriate size and has a normal, homogenous parenchyma with a smooth, continuous capsular surface. The splenic vasculature is normal with no evidence of congestion or thrombosis, and blood flow through the splenic hilus appears normal.

Liver

The liver is diffusely heterogeneous and subjectively enlarged, with rounded margins and a homogenous echotexture. The portal and hepatic vasculature are of normal size and appearance with no evidence of congestion or thrombosis.

There is a fluid filled structure observed in the right cranial abdomen that is suspected to be the gallbladder, however, it cannot be confirmed due to the presence of a large amount of inflamed



PATIENT

Luna Hebden

SPECIES

Canine

BREED

Dachshund

SEX

Spayed Female

AGE

5 Years

WEIGHT

5.07 kg

INTERPRETED BY

Tam Mengine, DVM,
DABVP (canine/feline
practice)

IMAGING PERFORMED BY

Dr. Meghan Myers

HOSPITAL NAME

Hershey Animal
Emergency Center

REFERRING VET

Dr. Victoria Orlando

INVOICE

12935

DATE

01/03/2026

omental fat in the region partially obscuring this structure. The cystic and common bile ducts are identified and appear unremarkable.

Gastrointestinal

The stomach is moderately distended with ingesta. The gastric wall is 3.1 mm with normal deviations due to rugal folds and exhibits appropriate wall layering. The pylorus is of normal appearance.

The visualized portions of the duodenum, jejunum, and ileum are of normal thickness with intact wall layering that exhibits the appropriate 1:3 muscularis to mucosa ratio. Intestinal motility appears normal.

The visible portions of the colon are of normal thickness with intact wall layering. The ileocecal junction was not seen.

Pancreas

The left limb of the pancreas is swollen and hypoechoic, surrounded by hyperechoic mesenteric fat. The pancreatic duct appears normal.

Free Abdomen

There is a moderate amount of free fluid noted within the abdomen. There is hyperechoic, inflamed omental fat noted in the region of the left pancreas and the liver. Enlarged abdominal lymph nodes are not observed. The aortic trifurcation has normal blood flow with no evidence of thrombosis.

PRIMARY FINDINGS

- Moderate amount of echogenic effusion.
- Steatitis noted within the cranial abdomen particularly in the region of the liver.

SECONDARY FINDINGS

- Diffusely heterogeneous rounded liver consistent with nonspecific hepatopathy.

INTERPRETATION OF THE FINDINGS & FURTHER RECOMMENDATIONS

The appearance of steatitis in the cranial abdomen raises the possibility of pancreatitis which is one of the few remaining causes of bicavitary effusion in this dog that has not already been excluded by the prior diagnostic investigation. Thus, evaluation of a pancreatic marker would be recommended to further investigate this possibility. The pancreas itself appears only mildly inflamed. So, while this is deemed unlikely, there are a few remaining causes of this patient's effusions. The changes to the liver are nonspecific and likely incidental, however, sampling would be needed to definitively rule out the possibility of significant liver pathology. Coagulation parameters should be verified, and platelet levels rechecked to ensure they are not dropping prior to any sampling of the liver.

Other possible causes for a bicavitary effusion could include vasculitis, thus, infectious disease testing should be considered. Finally, neoplastic disease would be a potential cause, however, this would be unusual in this young patient, and no source of neoplasia has been identified. If empirical treatment for vasculitis is desired, then treatment with broad spectrum antibiotics such as enrofloxacin and doxycycline along with pentoxifylline could be attempted.



PATIENT

Luna Hebden

SPECIES

Canine

BREED

Dachshund

SEX

Spayed Female

AGE

5 Years

WEIGHT

5.07 kg

INTERPRETED BY

Tam Mengine, DVM,
DABVP (canine/feline
practice)

IMAGING PERFORMED BY

Dr. Meghan Myers

HOSPITAL NAME

Hershey Animal
Emergency Center

REFERRING VET

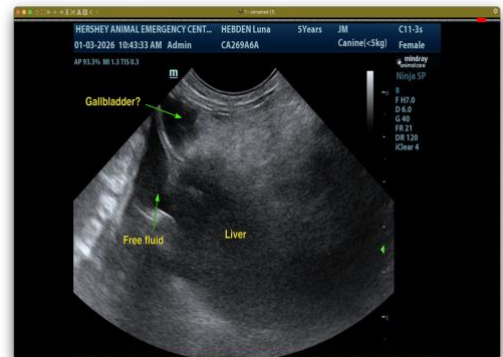
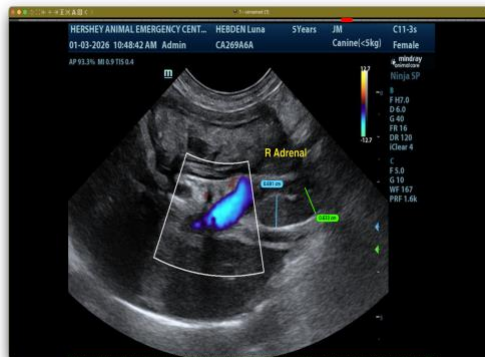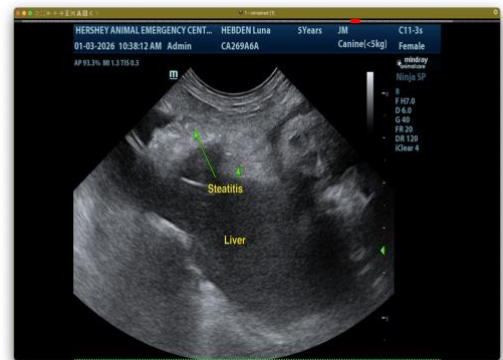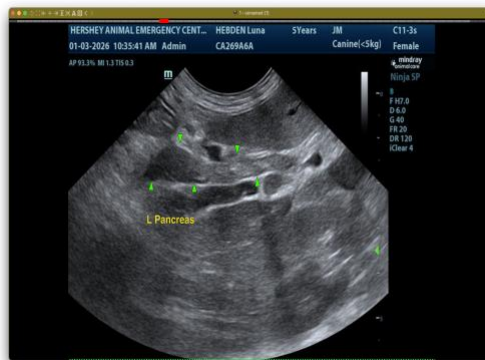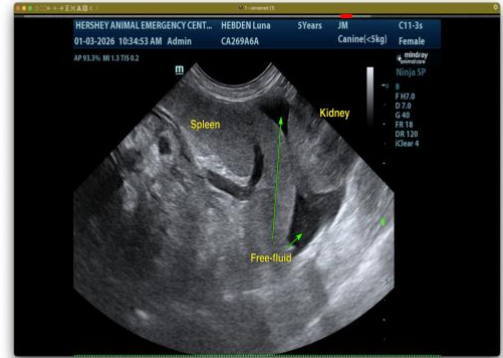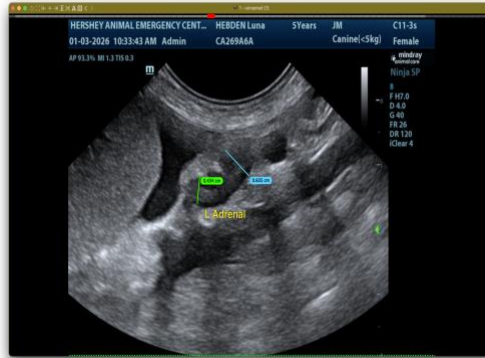
Dr. Victoria Orlando

INVOICE

12935

DATE

01/03/2026



The information and recommendations provided are based on the images presented by the referring veterinarian/sonographer. No evaluation can be communicated regarding pathology that was not visible in the image/video clips provided.

Thank you for this referral. If the clinical or image interpretation does not parallel your findings or if I can be of any further assistance, please contact me.

Tam Mengine, DVM, DABVP (canine/feline practice)

info@SonoPath.com



PATIENT

Luna Hebden

SPECIES

Canine

BREED

Dachshund

SEX

Spayed Female

AGE

5 Years

WEIGHT

5.07 kg

INTERPRETED BY

Tam Mengine, DVM,
DABVP (canine/feline
practice)

IMAGING PERFORMED BY

Dr. Meghan Myers

HOSPITAL NAME

Hershey Animal
Emergency Center

REFERRING VET

Dr. Victoria Orlando

INVOICE

12935

DATE

01/03/2026