



PATIENT

Dod Chen

SPECIES

Canine

BREED

DSH

SEX

Neutered Male

AGE

13 Years

WEIGHT

4.16 kg

INTERPRETED BY

Tam Mengine DVM,
DABVP (Canine/Feline
Practice)

IMAGING PERFORMED BY

Kerri Becker

HOSPITAL NAME

Banfield PH
Bridgewater

REFERRING VET

Dr. Verma

INVOICE

35551

DATE

1/23/26

PRESENTING CLINICAL SIGNS

Evidence of pathology involving the left caudal lung lobe a small neoplastic process including the left caudal lobe is likely rigid appearing loops of small intestine could indicate a focal area of either infiltrates of enteritis.

ULTRASONOGRAPHIC EXAMINATION OF THE ABDOMEN

Urinary System

The urinary bladder is moderately distended with anechoic urine. A small amount of echogenic luminal sediment is present, which is freely movable. The ureteral papillae, trigone and pelvic urethra are of normal appearance, and the ureters are not visible (normal). No masses, calculi or mucosal irregularities are noted. Urethra visualized to 2.0 cm

The kidneys are of normal size and shape and exhibit appropriate corticomedullary differentiation with a normal 1:3 cortex to medulla ratio. There is no evidence of nephrolithiasis, mineralization, pyelectasia, cystic change or hydronephrosis. The proximal ureter is not visible (normal). The left kidney is 4.3 cm in length. The right kidney is 4.5 cm in length.

Adrenal Glands

The adrenal glands are both identified in their normal locations. They are normal in size and shape with appropriate parenchymal echogenicity and normal phrenic vasculature. The left adrenal gland height is 3.8 mm at the caudal pole. The right adrenal gland height 4.4 mm at the caudal pole.

Spleen

The spleen is of appropriate size and has a normal, homogenous parenchyma with a smooth, continuous capsular surface. The splenic vasculature is normal with no evidence of congestion or thrombosis, and blood flow through the splenic hilus appears normal. Thickness at the splenic hilus is normal at 8.6 cm.

Liver

The liver is of appropriate size and shape, with sharp borders and a mildly coarse parenchymal echotexture that is hypoechoic to the spleen. The portal and hepatic vasculature are of normal size and appearance with no evidence of congestion or thrombosis.

The gallbladder is moderately distended with anechoic contents and a small amount of freely-moveable echogenic sludge. The wall was thin and continuous with no focal lesions. The cystic and common bile ducts are normal / not visible.

Gastrointestinal

The stomach is mildly distended with gas. The gastric wall is 2.1 mm with normal deviations due to rugal folds and exhibits appropriate wall layering. The pylorus is of normal appearance.

The small bowel has diffuse changes to the normal 1:3 muscularis to mucosa ratio. Wall measurements are increased up to 2.7 mm for duodenum and 2.9 mm for jejunum. Overall wall layering is preserved. Intestinal motility appears normal.



PATIENT

The visible portions of the colon are of normal thickness, up to 1.7 mm, with intact wall layering. The ileocecal junction is not visualized.

Dod Chen

Pancreas

SPECIES

The areas of the limbs and body of the pancreas are isoechoic to the surrounding mesenteric fat, with normal capsular appearance. There is no evidence of peripancreatic inflammation. The pancreatic duct appears normal.

Canine

BREED

Free Abdomen

DSH

There is no evidence of free fluid within the peritoneal cavity. The omentum and intra-abdominal fat are of appropriate echogenicity. Enlarged abdominal lymph nodes are not observed. The aortic trifurcation has normal blood flow with no evidence of thrombosis.

SEX

Neutered Male

ULTRASONOGRAPHIC FINDINGS

AGE

- Diffusely thickened small bowel, typical of infiltrative bowel disease.

13 Years

INTERPRETATION OF THE FINDINGS & FURTHER RECOMMENDATIONS

WEIGHT

The changes in the gastrointestinal tract are suggestive of infiltrative bowel disease, including both inflammatory bowel etiologies ((food allergy, lymphoplasmacytic enteritis, eosinophilic enteritis) or low-grade gastrointestinal lymphoma. Recommendations include:

4.16 kg

INTERPRETED BY

- Fecal parasite testing and empiric fenbendazole treatment
- Trials with a novel protein or hydrolyzed diet
- A complete GI panel, or empiric cobalamin supplementation
- Empiric therapy with prednisolone at 2-4mg / kg daily could be considered if a diet trial is unsuccessful.
- Definitive diagnosis would require biopsy of the affected tissue, ideally with intra-operative ultrasonographic guidance.

Tam Mengine DVM,
DABVP (Canine/Feline
Practice)

IMAGING PERFORMED BY

Kerri Becker

HOSPITAL NAME

Banfield PH
Bridgewater

REFERRING VET

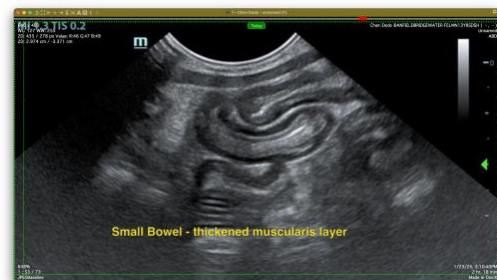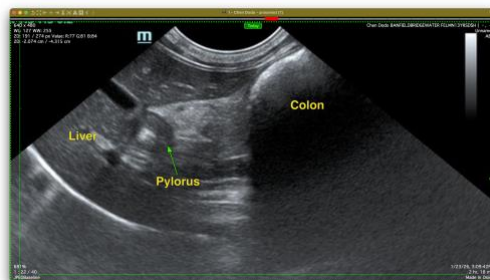
Dr. Verma

INVOICE

35551

DATE

1/23/26





PATIENT

Dod Chen

SPECIES

Canine

BREED

DSH

SEX

Neutered Male

AGE

13 Years

WEIGHT

4.16 kg

INTERPRETED BY

Tam Mengine DVM,
 DABVP (Canine/Feline
 Practice)

IMAGING PERFORMED BY

Kerri Becker

HOSPITAL NAME

Banfield PH
 Bridgewater

REFERRING VET

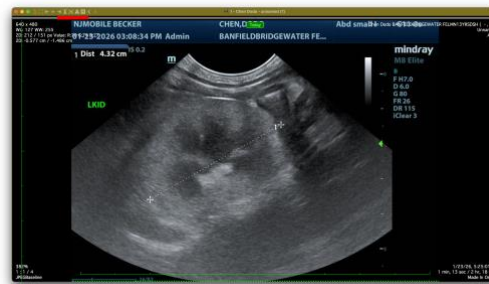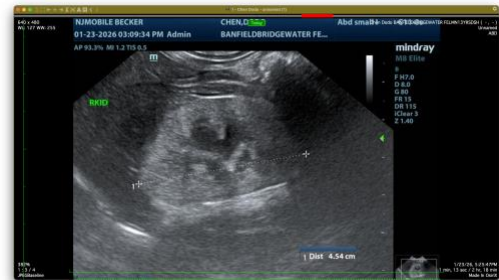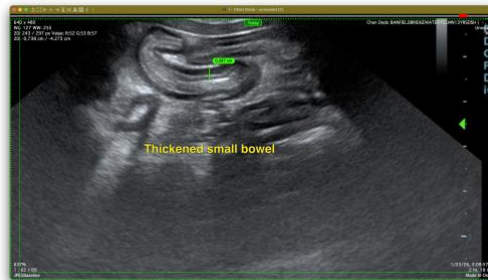Dr. Verma

INVOICE

35551

DATE

1/23/26



The information and recommendations provided are based on the images presented by the referring veterinarian. No evaluation can be communicated regarding pathology that was not visible in the image/video clips provided.

Thank you for this referral. If the clinical or image interpretation does not parallel your findings or if I can be of any further assistance please contact me.

Tam Mengine, DVM, DABVP (canine/feline practice)

info@SonoPath.com