



PATIENT

Albert Ivezic

SPECIES

Feline

BREED

DSH

SEX

Neutered Male

AGE

9 Years

WEIGHT

4.5 kg

INTERPRETED BY

Tam Mengine, DVM,
 DABVP (canine/feline
 practice)

IMAGING PERFORMED BY

Kelly Reschny

HOSPITAL NAME

Headon Forest Animal
 Hospital

REFERRING VET

Dr. Gibson

INVOICE

72932

DATE

1/2/26

PRESENTING CLINICAL SIGNS

Presented for ear infection (severe rod-shaped bacteria) and vomiting daily for the last week. Abdominal mass palpated on exam. Has been medically managed with cerenia and has not vomited since. Current Medications cerenia 16mg - 1/2 tablet SID, surolan - 6 drops BID, gabapentin 100mg given morning of ultrasound for PVP

Abnormal PE/Chem/CBC/UA Results: Bloodwork showed severe eosinophilia ($46.99 \times 10^9/L$), and mild lymphocytosis ($9.53 \times 10^9/L$) and monocytosis ($2.5 \times 10^9/L$). Iris stage 2 kidney disease, ALT 189U/L, and amylase 2742U/L, and fpli 45.0.

ULTRASONOGRAPHIC EXAMINATION OF THE ABDOMEN

Urinary System

The urinary bladder is moderately distended with anechoic urine. A large amount of echogenic luminal sediment is present, which is freely movable. The ureteral papillae, trigone and pelvic urethra (visible to 2.0 cm) are of normal appearance, and the ureters are not visible (normal). No masses, calculi or mucosal irregularities are noted.

The kidneys are hyperechoic, and exhibit moderately decreased cortico-medullary differentiation. There is no evidence of nephrolithiasis, mineralization, pyelectasia or hydronephrosis. The proximal ureters are not visible (normal). Left measures 3.0 cm. Right measures 3.2 cm.

Adrenal Glands

The adrenal glands are both identified in their normal locations. They are normal in size and shape with appropriate parenchymal echogenicity and normal phrenic vasculature. Left measures 3.0 mm. Right measures 3.3 mm.

Spleen

The spleen is of appropriate size and has a normal, homogenous parenchyma with a smooth, continuous capsular surface. The splenic vasculature is normal with no evidence of congestion or thrombosis, and blood flow through the splenic hilus appears normal. Thickness at the splenic hilus is normal (9.1 mm).

Liver

The liver is of appropriate size and shape, with sharp borders and a mildly coarse parenchymal echotexture that is hypoechoic to the spleen. The portal and hepatic vasculature are of normal size and appearance with no evidence of congestion or thrombosis.

The gallbladder is moderately distended with anechoic contents. The wall was thin and continuous with no focal lesions. The cystic and common bile ducts are normal / not visible.

Gastrointestinal

The stomach is empty. The gastric wall is subjectively normal in thickness, and exhibits appropriate wall layering, but cannot be accurately measured due to normal deviations of the rugal folds. The pylorus is of normal appearance.



PATIENT

Albert Ivezic

The visualized portions of the duodenum, jejunum, and ileum are of normal thickness with intact wall layering that exhibits the appropriate 1:3 muscularis to mucosa ratio. Intestinal motility appears normal.

SPECIES

Feline

The visible portions of the colon are of normal thickness (1.4 mm) with intact wall layering. The ileocecal junction is normal.

Pancreas

BREED

DSH

The right limb of the pancreas is swollen and mottled, surrounded by hyperechoic mesenteric fat. The pancreatic duct appears normal.

Free Abdomen

SEX

Neutered Male

There is no evidence of free fluid within the peritoneal cavity. The omentum and intrabdominal fat are hyperechoic. The mesenteric lymph nodes were moderately enlarged and hypoechoic with a rounded shape, measuring up to 3.5 cm, with focal mineralization. The aortic trifurcation has normal blood flow with no evidence of thrombosis.

AGE

9 Years

PRIMARY FINDINGS

- Hypoechoic, rounded mesenteric lymph nodes with associated steatitis.
- Mottled right pancreas with steatitis, consistent with pancreatitis.

WEIGHT

4.5 kg

SECONDARY FINDINGS

- Bilateral chronic renal changes.
- Large amount of bladder sediment, which may be incidental. However, urinalysis is recommended if not recently performed to rule out the possibility of inflammation.

INTERPRETED BY

Tam Mengine, DVM,
DABVP (canine/feline
practice)

INTERPRETATION OF THE FINDINGS & FURTHER RECOMMENDATIONS

The appearance of the mesenteric lymph nodes is concerning for infiltrative neoplasia such as lymphoma. Given the marked eosinophilia, mast cell disease would also be a consideration. Fine needle aspiration of these lymph nodes with a diphenhydramine pre-medication would be recommended for definitive diagnosis. If palliative care is desired, then Prednisolone at 2-4 mg/kg as well as supportive care such as antiemetics and analgesics could be considered.

IMAGING PERFORMED BY

Kelly Reschny

HOSPITAL NAME

Headon Forest Animal
Hospital

REFERRING VET

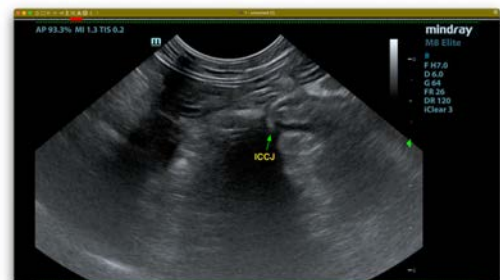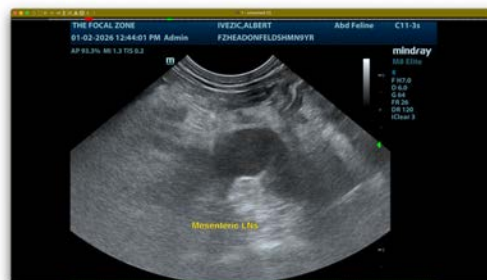Dr. Gibson

INVOICE

72932

DATE

1/2/26





PATIENT

Albert Ivezic

SPECIES

Feline

BREED

DSH

SEX

Neutered Male

AGE

9 Years

WEIGHT

4.5 kg

INTERPRETED BY

Tam Mengine, DVM,
 DABVP (canine/feline
 practice)

**IMAGING
 PERFORMED BY**

Kelly Reschny

HOSPITAL NAME

Headon Forest Animal
 Hospital

REFERRING VET

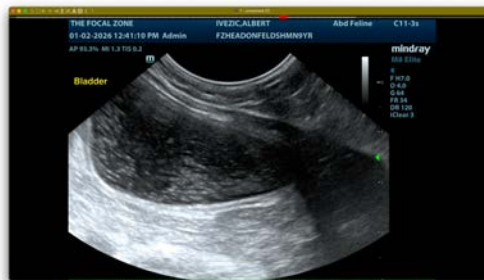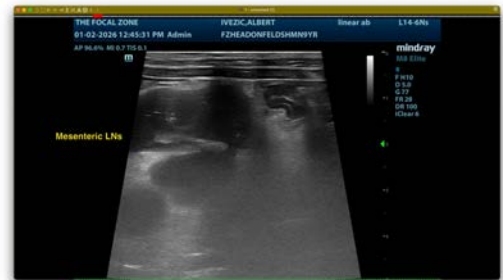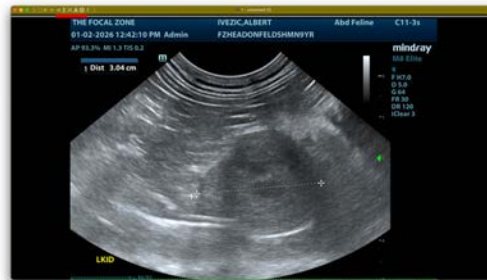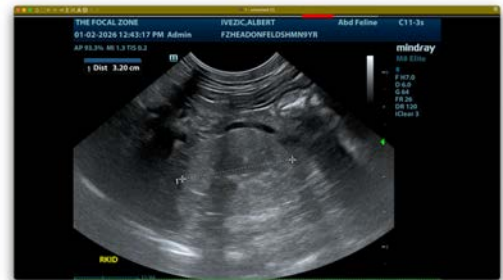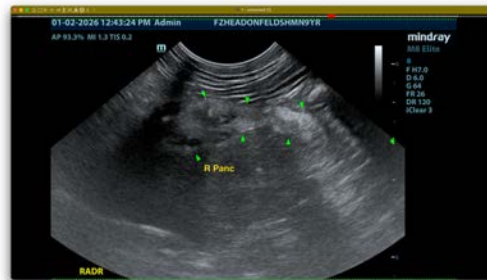
Dr. Gibson

INVOICE

72932

DATE

1/2/26



The information and recommendations provided are based on the images presented by the referring veterinarian/sonographer. No evaluation can be communicated regarding pathology that was not visible in the image/video clips provided.

Thank you for this referral. If the clinical or image interpretation does not parallel your findings or if I can be of any further assistance please contact me.

Tam Mengine, DVM, DABVP (canine/feline practice)

info@SonoPath.com