

**PATIENT**

Pippin Reed

SPECIES

Canine

BREED

Hound Mix

SEX

Neutered Male

AGE

10 Years

WEIGHT

28 kg

INTERPRETED BYTam Mengine DVM,
DABVP (Canine/Feline
Practice)**IMAGING
PERFORMED BY**Dr. Meghan Myers,
VMD**HOSPITAL NAME**

Hershey AEC

REFERRING VET

Dr. Brittany Lang

INVOICE

35335

DATE

1/10/26

PRESENTING CLINICAL SIGNS

History: P presents as transfer from rDVM for AUS. P has had ~15 day history of PU/PD with straining to urinate at the end of urination. Hx: anxiety (fluoxetine daily), cardiac arrhythmia (sotalol, procainamide daily).

Abnormal PE/Chem/CBC/UA Results: NS OU moderate tartar/gingival erythema Tense on abdominal palpation several round/soft SQ masses CBC: Neut 12.21K (H), Mono 1.27K (H) Chem: Gluc 195, ALP 252 (H) EPOC: Gluc 205 rDVM dx: - 12/30: CBC showed monocytosis, Chem WNL (ALP 158), T4 WNL, UA showed blood and protein. UPC 0.2 (borderline proteinuria) - 1/5: UA USG 1.015, trace blood, neg protein; radiographs showed mineralization at neck of urinary bladder.

ULTRASONOGRAPHIC EXAMINATION OF THE ABDOMEN**Urinary System**

The urinary bladder is moderately distended with anechoic urine, and no luminal sediment is present. There is mild thickening in the region of the right ureteral papilla, as well as a 1.0 cm projection of tissue arising from the region of the trigone without evident blood flow on doppler interrogation. No calculi are noted. The urethra was visualized to 4.0 cm.

The prostate is of appropriate size for patient age and neutering status, with a homogenous parenchyma and smooth capsule. The prostatic urethra is non-dilated with normal margins.

The kidneys are of normal size and shape and exhibit appropriate corticomedullary differentiation with a normal 1:3 cortex to medulla ratio. There is no evidence of nephrolithiasis, mineralization, pyelectasia, cystic change or hydronephrosis. The proximal ureter is not visible (normal). The left kidney is 7.0 cm in length. The right kidney is 7.6 cm in length.

Adrenal Glands

The adrenal glands are both identified in their normal locations. They are normal in size and shape with appropriate parenchymal echogenicity and normal phrenic vasculature. The left adrenal gland height is 4.4 mm at the cranial pole and 5.7 mm at the caudal pole. The right adrenal gland height is 5.9 mm at the cranial pole and 5.0 mm at the caudal pole.

Spleen

The spleen is of appropriate size and has a normal, homogenous parenchyma with a smooth, continuous capsular surface. The splenic vasculature is normal with no evidence of congestion or thrombosis, and blood flow through the splenic hilus appears normal.

Liver

The liver is of appropriate size and shape, with sharp borders and a mildly coarse parenchymal echotexture that is hypoechoic to the spleen. The portal and hepatic vasculature are of normal size and appearance with no evidence of congestion or thrombosis.

The gallbladder is moderately distended with anechoic contents and a small amount of freely moveable echogenic mineralized sludge. The wall was thin and continuous with no focal lesions. The cystic and common bile ducts are normal / not visible.

Gastrointestinal



PATIENT

Pippin Reed

SPECIES

Canine

BREED

Hound Mix

SEX

Neutered Male

AGE

10 Years

WEIGHT

28 kg

INTERPRETED BY

Tam Mengine DVM,
DABVP (Canine/Feline
Practice)

IMAGING PERFORMED BY

Dr. Meghan Myers,
VMD

HOSPITAL NAME

Hershey AEC

REFERRING VET

Dr. Brittany Lang

INVOICE

35335

DATE

1/10/26

The stomach is mildly distended with gas. The gastric wall is 4.9 mm with normal deviations due to rugal folds and exhibits appropriate wall layering. The pylorus is of normal appearance.

The visualized portions of the duodenum, jejunum, and ileum are of normal thickness with intact wall layering that exhibits the appropriate 1:3 muscularis to mucosa ratio. Intestinal motility appears normal.

The visible portions of the colon are of normal thickness, up to 1.2 mm, with intact wall layering. The ileocecal junction is not visualized.

Pancreas

The areas of the limbs and body of the pancreas are isoechoic to the surrounding mesenteric fat, with normal capsular appearance. There is no evidence of peripancreatic inflammation. The pancreatic duct appears normal.

Free Abdomen

There is no free fluid noted within the abdomen. There is hyperechoic, inflamed omental fat noted in the region of bladder. Enlarged abdominal lymph nodes are not observed. The aortic trifurcation has normal blood flow with no evidence of thrombosis.

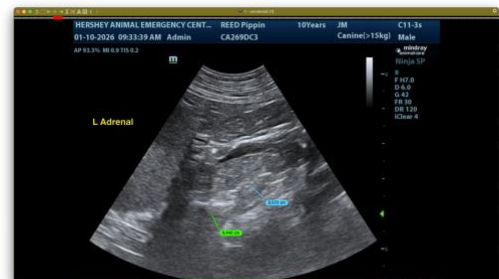
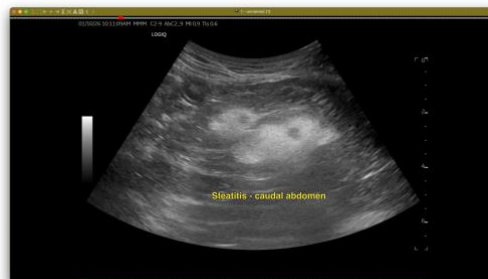ULTRASONOGRAPHIC FINDINGS

- Soft tissue proliferation within the region of the urinary bladder trigone, and associated prostatitis.

INTERPRETATION OF THE FINDINGS & FURTHER RECOMMENDATIONS

The appearance of the tissue in the bladder is unusual and might represent either an inflammatory or early neoplastic lesion. Additional steps to determine the underlying pathology might include:

- A urine culture if not already performed.
- Urine BRAF testing. Information on performing this urine test is available from Antech Diagnostics: <https://www.antechdiagnostics.com/cadet-braf-plus/>
- A urinalysis with cytology may be helpful for definitive diagnosis, especially with traumatic catheterization to collect. Cystocentesis should be avoided.
- Three view chest radiographs are recommended.
- If a palliative approach is desired, then NSAID therapy may provide relief of symptoms as well as some anti-tumor effects, in case the lesion is in fact neoplastic.





PATIENT

Pippin Reed

SPECIES

Canine

BREED

Hound Mix

SEX

Neutered Male

AGE

10 Years

WEIGHT

28 kg

INTERPRETED BY

Tam Mengine DVM,
DABVP (Canine/Feline
Practice)

IMAGING PERFORMED BY

Dr. Meghan Myers,
VMD

HOSPITAL NAME

Hershey AEC

REFERRING VET

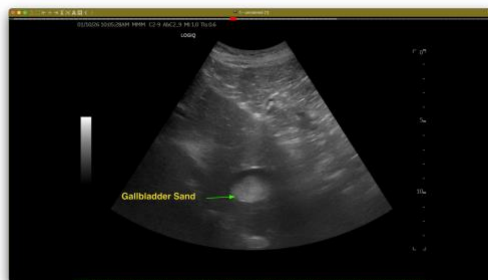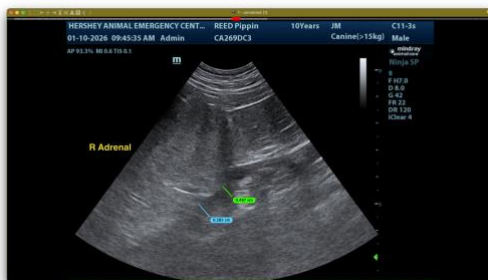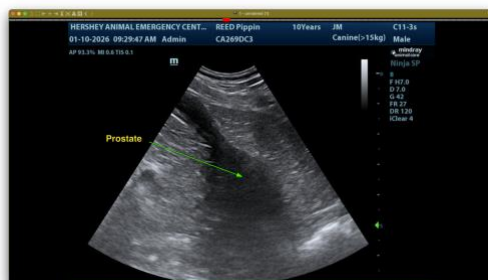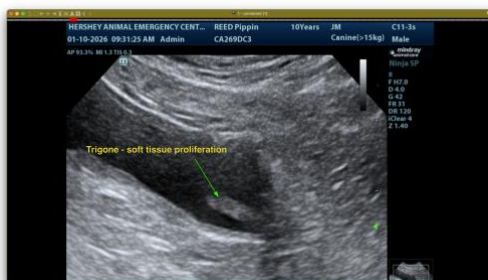Dr. Brittany Lang

INVOICE

35335

DATE

1/10/26



The information and recommendations provided are based on the images presented by the referring veterinarian. No evaluation can be communicated regarding pathology that was not visible in the image/video clips provided.

Thank you for this referral. If the clinical or image interpretation does not parallel your findings or if I can be of any further assistance please contact me.

Tam Mengine, DVM, DABVP (canine/feline practice)

info@SonoPath.com