



PATIENT

Tucker Vincent

SPECIES

Canine

BREED

Airedale Terrier

SEX

Male

AGE

7 Years

WEIGHT

63 lbs

INTERPRETED BY

Dr. Tais Guimarães,
MV

IMAGING PERFORMED BY

Dr. Cristy Fisher

HOSPITAL NAME

Pine Creek Veterinary
Hospital

REFERRING VET

Dr. Cristy Fisher

INVOICE

16443

DATE

06/05/26

PRESENTING CLINICAL SIGNS

Patient traveled to Arizona and spent 2-3 weeks near Tuscon, Arizona. Patient developed right sided epistaxis about 1 month after returning to Colorado. It has worsened significantly. 108 has open crown fracture. Current Ehrlichia titer pending however it was negative 3/2026. Coagulation panel is normal.

COMPUTED TOMOGRAPHIC STUDY OF THE HEAD

Post-contrast study provided for review.

COMPUTED TOMOGRAPHIC FINDINGS

The brain and pituitary gland are unremarkable with no evidence of intracranial mass, hemorrhage, or abnormal contrast enhancement.

Tympanic bullae air filled. No bulla wall lysis seen.

Orbits are symmetric. Eye globes are symmetric, normal size and shape. No retrobulbar masses seen.

There's soft tissue and fluid attenuating material filling the right nasal cavity, ill-defined margins, with small, mineralized component, associated with turbinate bone and nasal septum destruction on its rostral aspect. The lesion measures 5,5 cm on rostrocaudal axis. Frontal sinuses are air filled.

Both temporomandibular joints present congruent joint spaces.

No evidence of dental or periodontal disease.

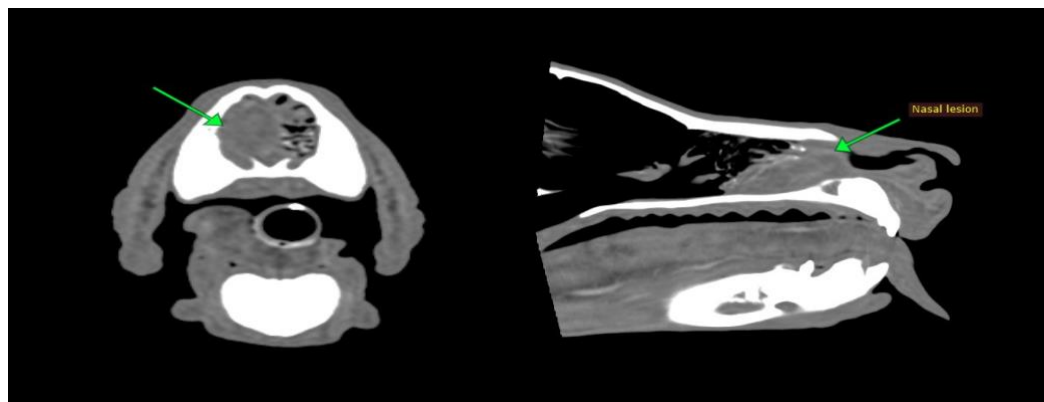
The salivary glands present within normal limits.

COMPUTED TOMOGRAPHIC DIAGNOSIS

- Right nasal cavity mass, no intracranial expansion seen.

INTERPRETATION OF FINDINGS & FURTHER RECOMMENDATIONS

The imaging findings are most consistent with nasal neoplasia, carcinoma most likely, lymphoma also possible. Infectious rhinopathy, such as fungal, secondary bacterial also possible. Rhinoscopy and nasal biopsies are recommended.



The information and recommendations provided are based on the images presented by the referring



PATIENT

Tucker Vincent

SPECIES

Canine

BREED

Airedale Terrier

SEX

Male

AGE

7 Years

WEIGHT

63 lbs

INTERPRETED BY

Dr. Tais Guimarães,
MV

IMAGING PERFORMED BY

Dr. Cristy Fisher

HOSPITAL NAME

Pine Creek Veterinary
Hospital

REFERRING VET

Dr. Cristy Fisher

INVOICE

16443

DATE

06/05/26

veterinarian. No evaluation can be communicated regarding pathology that was not visible in the image/video clips provided.

Thank you for this referral. If the clinical or image interpretation does not parallel your findings or if I can be of any further assistance please contact me.

Dr. Tais Guimarães, MV
info@sonopath.com