



PATIENT

Mikey Defazio

SPECIES

Canine

BREED

Chihuahua

SEX

M

AGE

7Y, 3M, 22D

WEIGHT

3.3kg

INTERPRETED BY

Dr. Tais Guimarães,
MV

IMAGING PERFORMED BY

AMC

HOSPITAL NAME

Green Dog Dental and
Wellness

REFERRING VET

Dr. Geist

INVOICE

75216

DATE

5-28-26

PRESENTING CLINICAL SIGNS

Left retrobulbar lesion, with primary differentials including retrobulbar abscess and retrobulbar neoplasia.

COMPUTED TOMOGRAPHIC STUDY OF THE HEAD

Plain series is available for reading.

COMPUTED TOMOGRAPHIC FINDINGS

There is a mildly heterogeneous, soft tissue attenuating/dense fluid mass with ill-defined margins centered within the left orbital cavity measuring approximately 1.7 x 1.8 cm. No significant zygomatic bone lysis seen. The mass causes compression and displacement of the left eye globe. Lesion margins and enhancement pattern are not accessed without use of contrast.

The brain and pituitary gland are unremarkable with no evidence of intracranial mass or hemorrhage.

Both temporomandibular joints present congruent joint spaces with even subchondral bone surfaces and are considered within normal limits.

Tympanic cavities are normal size and air filled with mild irregular mucosal thickening in the right tympanic bulla. No wall lysis or osseous abnormalities seen.

Small periodontal lysis seen at the level of 209 tooth root.

Right and left external ears have no wall abnormalities.

The mandibular and medial retropharyngeal lymph nodes are symmetric, small, and elongated with a normal short-to-long-axis-ratio is < 0.5, the attenuation pattern is uniform.

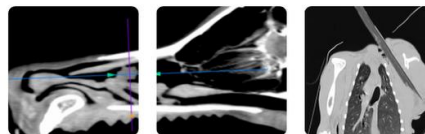
The salivary glands present within normal limits.

COMPUTED TOMOGRAPHIC DIAGNOSIS

- Left retrobulbar expansile lesion causing mild exophthalmos.
- 209 periodontal disease.

INTERPRETATION OF FINDINGS & FURTHER RECOMMENDATIONS

The findings are consistent with a retrobulbar expansile lesion. Considering the presence of periodontal lysis adjacent to 209 tooth root, abscess is a most likely diagnosis. Neoplasia cannot be ruled out. Dental consultation is advised and histopathology recommended for definitive diagnosis.



PATIENT

Mikey Defazio

SPECIES

Canine

BREED

Chihuahua

SEX

M

AGE

7Y, 3M, 22D

WEIGHT

3.3kg

INTERPRETED BY

Dr. Tais Guimarães,
MV

IMAGING PERFORMED BY

AMC

HOSPITAL NAME

Green Dog Dental and
Wellness

REFERRING VET

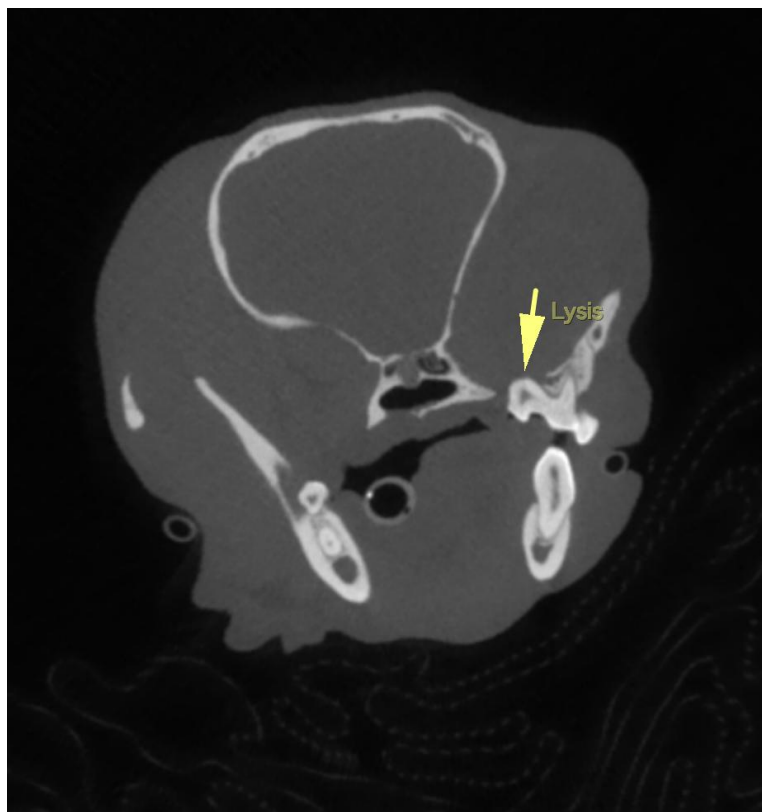
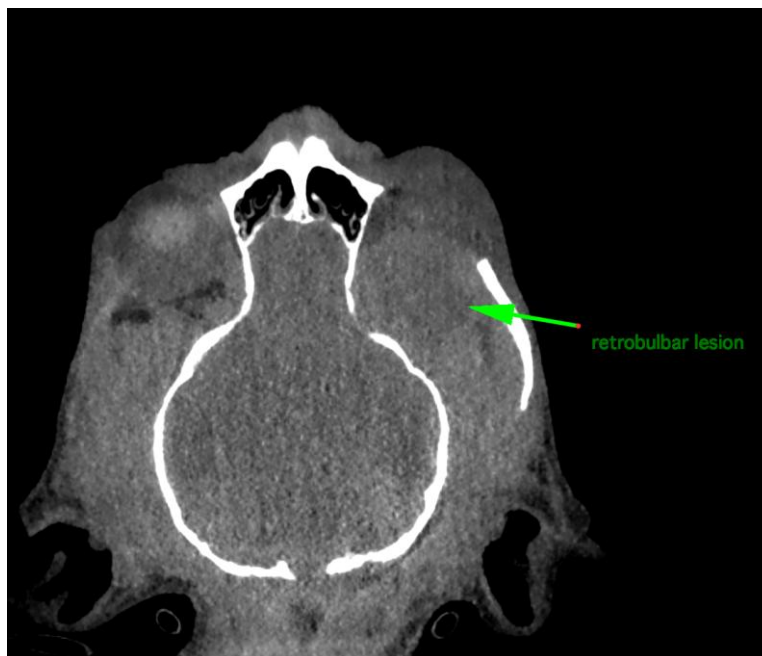
Dr. Geist

INVOICE

75216

DATE

5-28-26





PATIENT

Mikey Defazio

SPECIES

Canine

BREED

Chihuahua

SEX

M

AGE

7Y, 3M, 22D

WEIGHT

3.3kg

INTERPRETED BY

Dr. Tais Guimarães,
MV

IMAGING PERFORMED BY

AMC

HOSPITAL NAME

Green Dog Dental and
Wellness

REFERRING VET

Dr. Geist

INVOICE

75216

DATE

5-28-26

The information and recommendations provided are based on the images presented by the referring veterinarian. No evaluation can be communicated regarding pathology that was not visible in the image/video clips provided.

Thank you for this referral. If the clinical or image interpretation does not parallel your findings or if I can be of any further assistance please contact me.

Dr. Tais Guimarães, MV
info@sonopath.com