



PATIENT

Delta Simpson

SPECIES

Canine

BREED

Belgian Malinois Mix

SEX

FS

AGE

3Y

WEIGHT

110lbs

INTERPRETED BY

Dr. Tais Guimarães,
MV

IMAGING PERFORMED BY

Tina Lynn, CVT/George
Eales, DVM

HOSPITAL NAME

Green Prairie Animal
Hospital

REFERRING VET

Oakdale Veterinary
Center-Dr. Flessner

INVOICE

75143

DATE

5-26-26

PRESENTING CLINICAL SIGNS

3 month lameness and pain, rads show suspect OCD

COMPUTED TOMOGRAPHIC STUDY OF THE ELBOWS

Plain images provided for review.

COMPUTED TOMOGRAPHIC FINDINGS

Humeral metaphysis: No medullary sclerosis;

Humeral epicondyles: small osteophyte formation on medial side;

Humeral condyles: Normal. No OCD seen.

Radial head: small osteophyte seen on the cranial margin

Radial-ulnar joint space: normal;

Anconeal process: fused, small osteophyte on proximal surface

Medial coronoid: deformed shape, large osteophytes with fissure in the region of the medial coronoid;

Ulna: semilunar notch: moderate subchondral sclerosis

Radius and ulna: no medullary sclerosis

The regional lymph nodes present within normal limits.

COMPUTED TOMOGRAPHIC DIAGNOSIS

Right elbow:

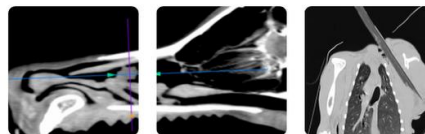
- Medial compartment disease with coronoid incomplete fragmentation.
- Secondary degenerative joint disease.

Left elbow:

- Normal.

INTERPRETATION OF FINDINGS & FURTHER RECOMMENDATIONS

The findings are consistent with elbow dysplasia with coronoid fragmentation and secondary osteoarthritis. The degree of periarticular remodeling and subchondral sclerosis suggests a chronic biomechanical disorder of the elbow joint. Orthopedic consultation and consideration for arthroscopic assessment are recommended. Long-term osteoarthritis management will likely be required.



PATIENT

Delta Simpson

SPECIES

Canine

BREED

Belgian Malinois Mix

SEX

FS

AGE

3Y

WEIGHT

110lbs

INTERPRETED BY

Dr. Tais Guimarães,
MV

IMAGING PERFORMED BY

Tina Lynn, CVT/George
Eales, DVM

HOSPITAL NAME

Green Prairie Animal
Hospital

REFERRING VET

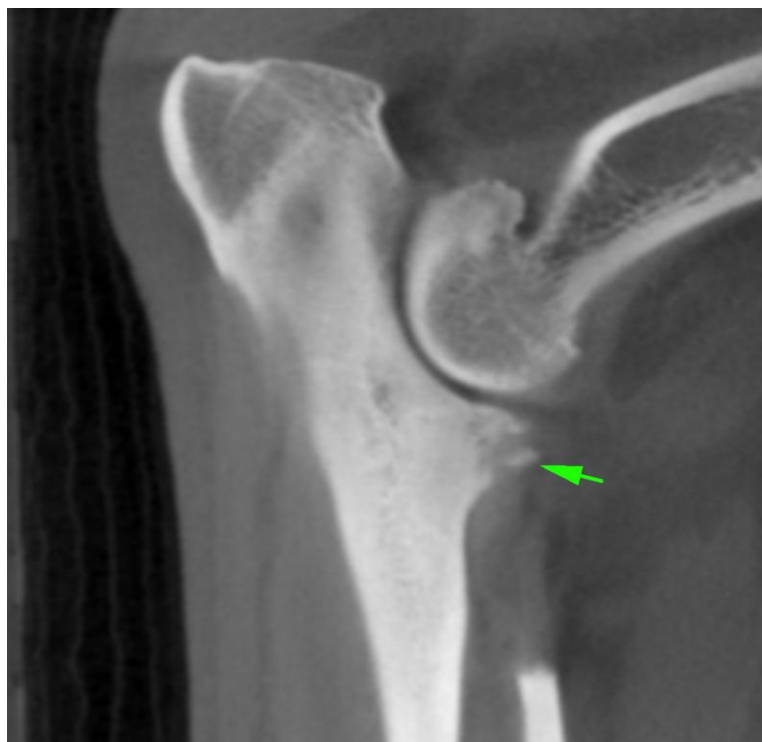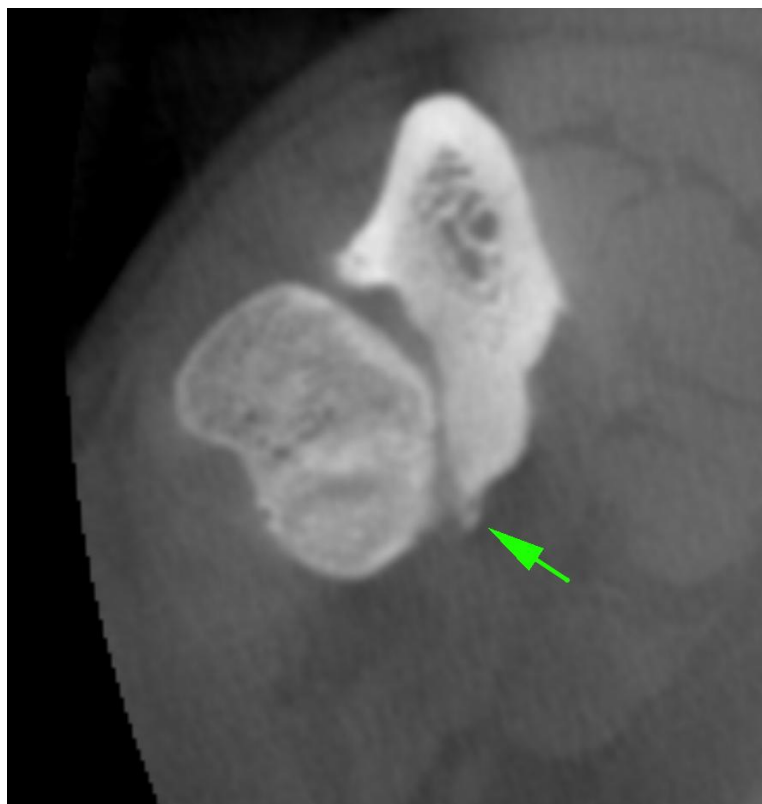
Oakdale Veterinary
Center-Dr. Flessner

INVOICE

75143

DATE

5-26-26





PATIENT

Delta Simpson

SPECIES

Canine

BREED

Belgian Malinois Mix

SEX

FS

AGE

3Y

WEIGHT

110lbs

INTERPRETED BY

Dr. Tais Guimarães,
MV

IMAGING PERFORMED BY

Tina Lynn, CVT/George
Eales, DVM

HOSPITAL NAME

Green Prairie Animal
Hospital

REFERRING VET

Oakdale Veterinary
Center-Dr. Flessner

INVOICE

75143

DATE

5-26-26

The information and recommendations provided are based on the images presented by the referring veterinarian. No evaluation can be communicated regarding pathology that was not visible in the image/video clips provided.

Thank you for this referral. If the clinical or image interpretation does not parallel your findings or if I can be of any further assistance please contact me.

Dr. Tais Guimarães, MV
info@sonopath.com