



PATIENT

Karley Melendez

SPECIES

Canine

BREED

Maltese

SEX

FS

AGE

16Y

WEIGHT

12lbs

INTERPRETED BY

Dr. Tais Guimarães,
MV

**IMAGING
PERFORMED BY**

Mobile Pet Imaging

HOSPITAL NAME

Mobile Pet Imaging

REFERRING VET

Armstrong

INVOICE

75061

DATE

5-19-26

PRESENTING CLINICAL SIGNS

Karley presented for anorexia, hematuria over the weekend, urinating a large amount of urine with frank blood.

COMPUTED TOMOGRAPHIC STUDY OF THE ABDOMEN

Survey and post contrast CT series are available.

COMPUTED TOMOGRAPHIC FINDINGS

Both kidneys are normally positioned, regular contours and normal volume, with multiple small cortical cysts. No stones seen.

Urinary bladder is normally distended, no stones seen, caudally positioned, with intrapelvic component. No urethral abnormality detected.

Mild hepatomegaly with homogeneous attenuation and enhancement pattern and within normal limits. Multiple small, rounded, uniformly enhancing splenic nodules are seen with the largest measuring 8mm.

The serosal fat presents normal attenuation behavior. There is no evidence of peritoneal effusion or peritonitis.

The pancreas is evenly contoured; the pancreatic parenchyma is homogeneous and presents uniform contrast enhancement.

Adrenal glands are normal.

The delineation, wall and content of the gastrointestinal tract are considered within normal limits throughout.

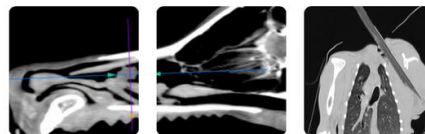
Lumbar spine appears normal.

COMPUTED TOMOGRAPHIC DIAGNOSIS

- Intra-pelvic urinary bladder: congenital, acquired.
- Splenic nodules: hyperplastic most likely.

INTERPRETATION OF FINDINGS & FURTHER RECOMMENDATIONS

Cystitis is a likely differential for adult dogs with hematuria in the absence of stones and masses. Urinalysis and culture are recommended. Cystoscopy may be indicated if clinical signs persist.



PATIENT

Karley Melendez

SPECIES

Canine

BREED

Maltese

SEX

FS

AGE

16Y

WEIGHT

12lbs

INTERPRETED BY

Dr. Tais Guimarães,
MV

IMAGING PERFORMED BY

Mobile Pet Imaging

HOSPITAL NAME

Mobile Pet Imaging

REFERRING VET

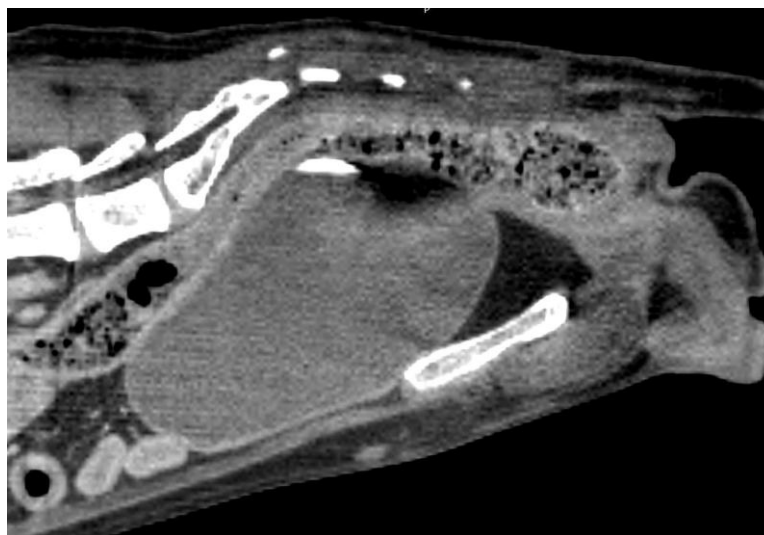
Armstrong

INVOICE

75061

DATE

5-19-26



The information and recommendations provided are based on the images presented by the referring veterinarian. No evaluation can be communicated regarding pathology that was not visible in the image/video clips provided.

Thank you for this referral. If the clinical or image interpretation does not parallel your findings or if I can be of any further assistance please contact me.

Dr. Tais Guimarães, MV
info@sonopath.com