



PATIENT

Charlie Wray

SPECIES

Feline

BREED

DSH

SEX

MC

AGE

3Y

WEIGHT

15.46

INTERPRETED BY

Dr. Tais Guimarães,
MV

IMAGING PERFORMED BY

Cynthia Maro

HOSPITAL NAME

Cranberry Holistic Pet
Care

REFERRING VET

Cynthia Maro

INVOICE

75032

DATE

5-18-26

PRESENTING CLINICAL SIGNS

Pet has a history of deviated septum, chronic sinusitis and rhinitis

COMPUTED TOMOGRAPHIC STUDY OF THE HEAD & THORAX

Plain and post-contrast studies provided for review.

COMPUTED TOMOGRAPHIC FINDINGS

Head

The brain and pituitary gland are unremarkable with no evidence of intracranial mass, hemorrhage, or abnormal contrast enhancement.

Orbits are symmetric. Eye globes are symmetric with normal size and shape. No retrobulbar masses seen.

Thin and smoothly folded conchae and turbinates with even smooth mucosal lining. Nasal septum is mildly undulating. The osseous lining of the nasal cavities is intact.

Both temporomandibular joints present congruent joint spaces with even subchondral bone surfaces and are considered within normal limits.

Tympanic bullae are air filled.

No periodontal disease seen.

The submandibular and medial retropharyngeal lymph nodes are small and elongated with a normal short-to-long-axis-ratio is < 0.5, the attenuation and contrast enhancement pattern is uniform.

The salivary glands present within normal limits.

Thorax

Thorax is partially included on the FOV.

There are areas of increased opacification in the left cranial and right middle lobes. No masses seen.

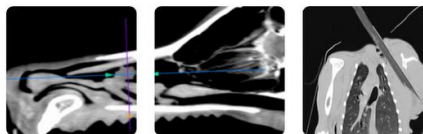
The mediastinum presents within normal limits.

COMPUTED TOMOGRAPHIC DIAGNOSIS

- No evidence of nasal masses or aggressive nasal disease.

INTERPRETATION OF FINDINGS & FURTHER RECOMMENDATIONS

No lesion is identified that correlates to the clinical signs are seen. Rhinoscopy and nasal biopsies are recommended.



PATIENT

Charlie Wray

SPECIES

Feline

BREED

DSH

SEX

MC

AGE

3Y

WEIGHT

15.46

INTERPRETED BY

Dr. Tais Guimarães,
MV

IMAGING PERFORMED BY

Cynthia Maro

HOSPITAL NAME

Cranberry Holistic Pet
Care

REFERRING VET

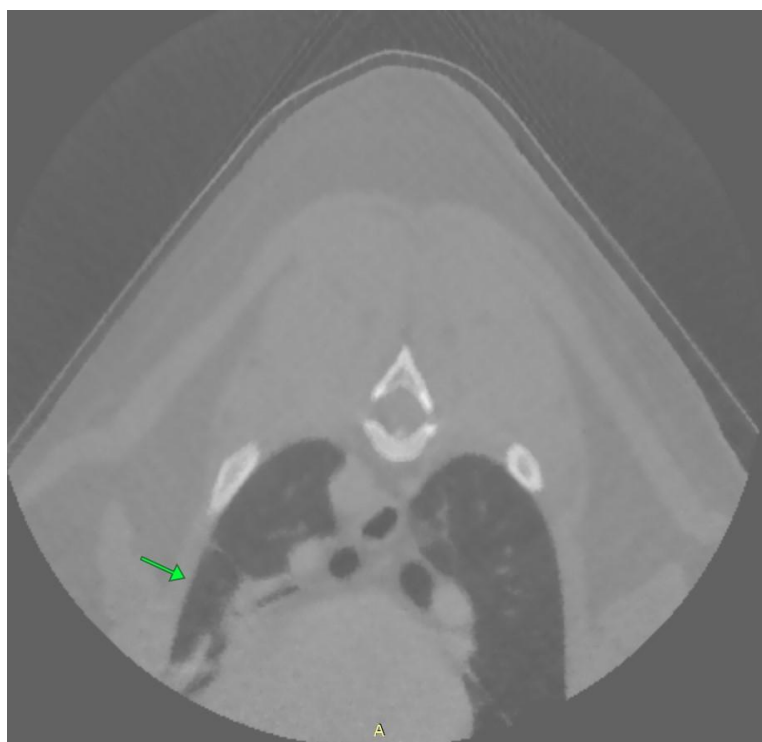
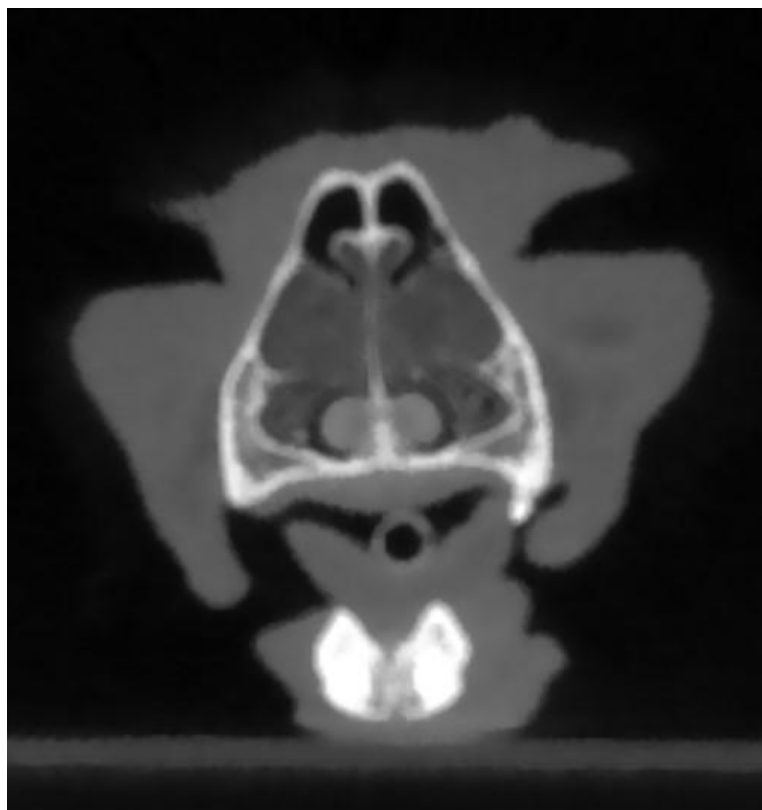
Cynthia Maro

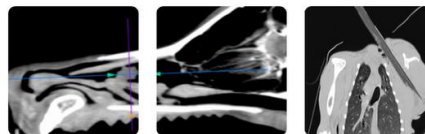
INVOICE

75032

DATE

5-18-26





PATIENT

Charlie Wray

SPECIES

Feline

BREED

DSH

SEX

MC

AGE

3Y

WEIGHT

15.46

INTERPRETED BY

Dr. Tais Guimarães,
MV

IMAGING PERFORMED BY

Cynthia Maro

HOSPITAL NAME

Cranberry Holistic Pet
Care

REFERRING VET

Cynthia Maro

INVOICE

75032

DATE

5-18-26

The information and recommendations provided are based on the images presented by the referring veterinarian. No evaluation can be communicated regarding pathology that was not visible in the image/video clips provided.

Thank you for this referral. If the clinical or image interpretation does not parallel your findings or if I can be of any further assistance please contact me.

Dr. Tais Guimarães, MV
info@sonopath.com