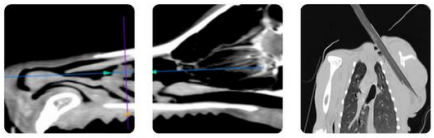

Teleradiology
Educational Teleconsultation Services™

PATIENT
Dani Elder

SPECIES
Canine

BREED
Golden Retriever

SEX
Female Spayed

AGE
8Y

WEIGHT
35kgs

INTERPRETED BY
Dr. Tais Guimarães, MV

IMAGING PERFORMED BY
John Davies

HOSPITAL NAME
Northstar Veterinary Surgery

REFERRING VET
John Davies

INVOICE
75030

DATE
5-15-26

PRESENTING CLINICAL SIGNS

Dani is a 8 yr F/S Golden Retriever who presents today for surgical consult. Owner states they first noticed OS swelling around 3 weeks ago. Owner took took to pDVM and patient was started on eye medications. Owner states it got better but as soon as they stopped the eye medication the swelling came back. Owner brought back to pDVM and patient had a dental procedure performed. NSF for oral exam but skull radiographs were taken and radiologist review saw possible mass effect and recommended a CT scan. Patient has been having a hard time chewing hard food and has been very lethargic and not herself. History of benign chin mass removal in 2023.
Meds: Prednisone and Clavamox

COMPUTED TOMOGRAPHIC STUDY OF THE HEAD

Plain and post-contrast studies in soft tissue, lung and bone windows provided for review.

COMPUTED TOMOGRAPHIC FINDINGS

The brain and pituitary gland are unremarkable with no evidence of intracranial mass, hemorrhage, or abnormal contrast enhancement.

Orbits are symmetric. Eye globes are symmetric with normal size and shape. No retrobulbar masses seen.

Thin and smoothly folded conchae and turbinates with even smooth mucosal lining. The osseous lining of the nasal cavities is intact.

Both temporomandibular joints present congruent joint spaces with even subchondral bone surfaces and are considered within normal limits.

No evidence of dental or periodontal disease.

The submandibular and medial retropharyngeal lymph nodes are small and elongated with a normal short-to-long-axis-ratio is < 0.5, the attenuation and contrast enhancement pattern is uniform.

The salivary glands present within normal limits.

COMPUTED TOMOGRAPHIC DIAGNOSIS

- Normal skull

INTERPRETATION OF FINDINGS & FURTHER RECOMMENDATIONS

No lesion was identified that explains the clinical signs. Skull MRI can be recommended for better assessment of soft tissue lesions.

SonoPath
FOSTERING THE ART OF VETERINARY MEDICINE™

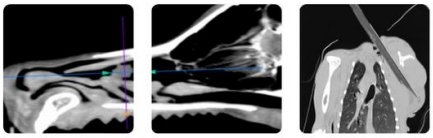

Teleradiology
Educational Teleconsultation Services™

SonoPath.com info@sonopath.com 1.800.838.4268

PATIENT

Dani Elder

SPECIES

Canine

BREED

Golden Retriever

SEX

Female Spayed

AGE

8Y

WEIGHT

35kgs

INTERPRETED BY

Dr. Tais Guimarães, MV

IMAGING PERFORMED BY

John Davies

HOSPITAL NAME

Northstar Veterinary Surgery

REFERRING VET

John Davies

INVOICE

75030

DATE

5-15-26

The information and recommendations provided are based on the images presented by the referring veterinarian. No evaluation can be communicated regarding pathology that was not visible in the image/video clips provided.

Thank you for this referral. If the clinical or image interpretation does not parallel your findings or if I can be of any further assistance please contact me.

Dr. Tais Guimarães, MV
info@sonopath.com