


PATIENT PRESENTING CLINICAL SIGNS

Buster Ball Swelling in the left mandible. It is possible to appreciate the enlarged left retromandibular lymph node.

SPECIES COMPUTED TOMOGRAPHIC STUDY OF THE HEAD AND NECK

Canine A pre- and post-contrast CT study of the head and neck are provided for review totaling 3 series. One pre-contrast series of the head and cervical soft tissue, soft tissue algorithm. Two post-contrast series of the head and cervical, soft tissue algorithm.

BREED COMPUTED TOMOGRAPHIC FINDINGS

Staffordshire Bull Terrier

CERVICAL SOFT TISSUE
SEX

Male

There is a large, rounded to multilobulated, mixed attenuating cervical mass effect with a thin enhanced border, localized ventrally in the mandibular and cervical region, adjacent to the right salivary gland and right thyroid gland*. The inner of the mass is predominantly hypoattenuating. The mass extends from the base of the right temporomandibular fossa caudally through the height of the C6 vertebral body. The right retropharyngeal lymph node is indistinct. The mass compresses and displaces the oropharynx and tracheal lumen to the left side; it is also contiguous with and changes the pathway of the common external jugular vein and right common carotid artery. The border/limits of the right common carotid artery are indistinct in some regions adjacent to the mass. The mass measures at least 14.0cm by 7.0cm by 6.9cm. A portion of the right thyroid gland is defined.

AGE

8 Years

INTERPRETED BY

Tilde Rodrigues Froes, DMV, MSc., Dr. Med Vet., Dipl. CBraRVet

The hyoid apparatus is displaced to the left, however, no evidence of osteolytic changes.

The right mandibular lymph nodes are moderately enlarged, homogeneously.

The left mandibular lymph nodes and medial retropharyngeal lymph node are unremarkable.

The left thyroid gland is unremarkable.

HOSPITAL NAME

Animal Trust - Ellesmere Port

The cervical spine is normal.

HEAD

The nasal cavities, turbinates and choana are normal.

REFERRING VET

Dr. Molly Ellson

The cribriform plate is intact.

The frontal sinuses are unremarkable.

INVOICE

44514

The bulla cavities and external auditory canals are normal.

No mass effect is seen in the brain, normal attenuation.

The temporomandibular joints are bilaterally congruent.

DATE

8/9/23



PATIENT The globes and retrobulbar spaces are unremarkable.

Buster Ball All teeth are present.

SPECIES

Canine

BREED

Staffordshire Bull Terrier

SEX

Male

AGE

8 Years

COMPUTED TOMOGRAPHIC DIAGNOSIS

- Large, rounded to multilobulated mixed attenuating ventral right* cervical mass, the differential diagnosis includes neoplasm process. The origin of the mass is not clearly defined due to the size and proximity with the adjacent structures, the possibilities are thyroid mass or less likely salivary mass.
- The right retropharyngeal is indistinct, and likely contiguous within the mass.
- The mass compresses externally and displaces the oropharynx/larynx and trachea to the left.

INTERPRETATION OF THE FINDINGS & FURTHER RECOMMENDATIONS

The cervical mass is located in the right side*, there is a possibility of swift lateral markers in the tomographic exam. Considering the origin of the mass to be the thyroid gland, the differential diagnosis includes thyroid carcinoma. Considering the origin of the mass to be the salivary gland, the differential diagnosis includes mandibular salivary adenocarcinoma. The mass has cystic components.

Cervical ultrasound and fine-needle aspiration are suggested for further evaluation. The right external jugular vein is contiguous to the external portion of the mass. The right common carotid artery is not clearly defined in some portions.

TECHNICAL FACTORS: *The cervical mass is detected in the right side, and does not correspond to the presented clinical description, consider the swift the lateral markers in the tomographic exam.

INTERPRETED BY

Tilde Rodrigues Froes, DMV, MSc., Dr. Med Vet., Dipl. CBraRVet

HOSPITAL NAME

Animal Trust - Ellesmere Port

REFERRING VET

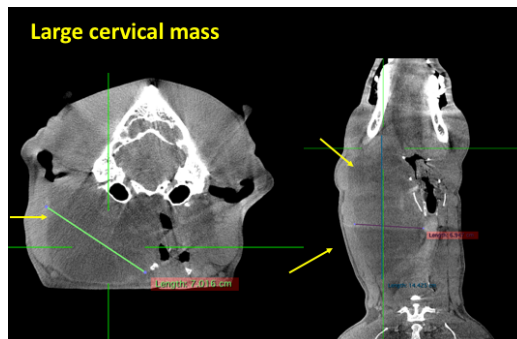
Dr. Molly Ellison

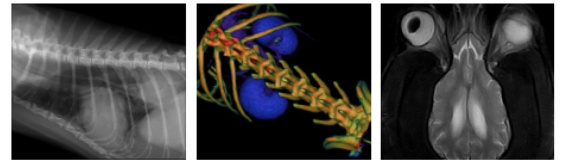
INVOICE

44514

DATE

8/9/23





PATIENT

Buster Ball

SPECIES

Canine

BREED

Staffordshire Bull Terrier

SEX

Male

AGE

8 Years

INTERPRETED BY

Tilde Rodrigues Froes, DMV, MSc., Dr. Med Vet., Dipl. CBraRVet

HOSPITAL NAME

Animal Trust - Ellesmere Port

REFERRING VET

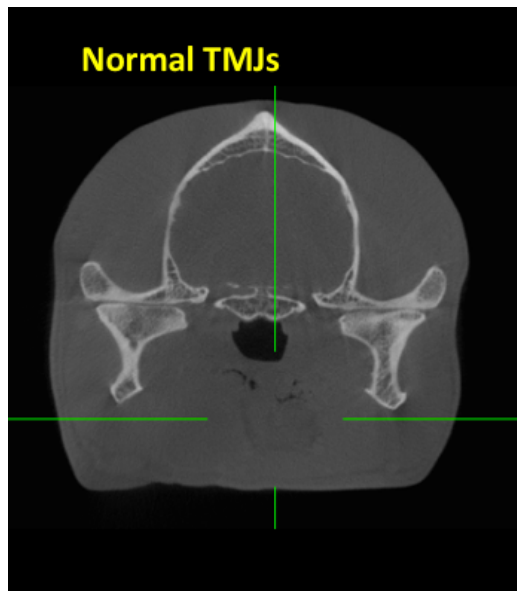
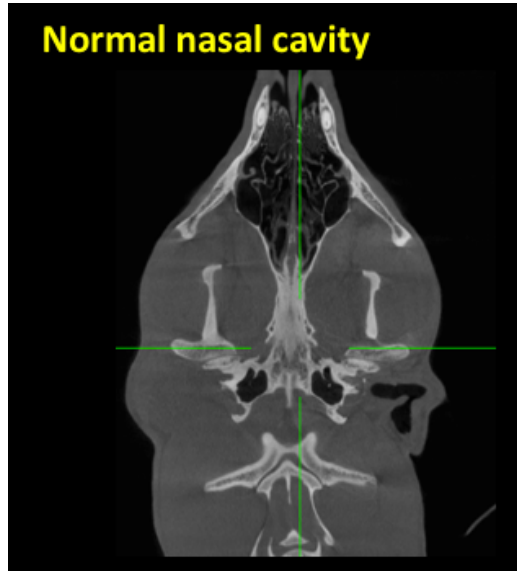
Dr. Molly Ellson

INVOICE

44514

DATE

8/9/23



The information and recommendations provided are based on the images presented by the referring veterinarian. No evaluation can be communicated regarding pathology that was not visible in the image/video clips provided.

Thank you for this referral. If the clinical or image interpretation does not parallel your findings or if I can be of any further assistance please contact me.

Tilde Rodrigues Froes, DMV, MSc., Dr. Med.Vet., Dipl.CBraRVet
info@sonopath.com