



PATIENT PRESENTING CLINICAL SIGNS

Bessie Ortolf Soft palate and nares correction sx in May. Had an episode on 7/16/23- will make choking noises, extend neck, wide eyes, falls over and completely stops breathing. Lasts short amount of time then seems okay after sudden deep relieving breath. Happened again yesterday 8/21/23. Was very calm before both episodes. Goes on walks and plays fine with no issues.

SPECIES

Canine

COMPUTED TOMOGRAPHIC STUDY OF THE HEAD & CERVICAL SOFT TISSUE

BREED

English Bulldog

A pre- and post-contrast CT study of the head are provided for review totaling 3 series. Two pre-contrast series of the head and cervical region, soft tissue algorithm. One post-contrast series of the head and cervical region, soft tissue algorithm.

COMPUTED TOMOGRAPHIC FINDINGS

SEX

The nasal cavities and turbinates are symmetrical and intact. No evidence of hypoattenuating fluid accumulation.

FS

Aberrant turbinates are seen within the choana/nasopharyngeal meatus, incidental for brachycephalic dogs.

AGE

11 Months

The soft palate is severely thickened causing almost 90% nasopharyngeal obstruction. The thickness measures approximately 1.5cm.

The cribriform plate is intact.

INTERPRETED BY

Tilde Rodrigues Froes, DMV, MSc., Dr. Med Vet., Dipl. CBraRVet

The frontal sinuses are unremarkable.

The bulla cavities and external auditory canals are normal, considering the smaller luminal height correlated to the brachycephalic breed characteristics.

No mass effect is seen in the brain, normal attenuation.

HOSPITAL NAME

Scottsdale Veterinary Clinic

The temporomandibular joints are bilaterally congruent.

The fascial, cervical, and head muscle mass is symmetrical, and unremarkable.

The globes and retrobulbar spaces are unremarkable.

REFERRING VET

Dr. Blackmon

All teeth are present.

The medial retropharyngeal lymph nodes (and accessory node) are asymmetrical. The left medial retropharyngeal lymph node is enlarged and more rounded shape in comparison with the right that is normal. The LRFLN is measuring 2.5cm by 1.3cm. The RRFLN is measuring 1.1cm by 0.59cm.

INVOICE

The mandibular lymph nodes are unremarkable.

59877

Subjective reduction of the cervical tracheal luminal height is seen.

DATE

8-22-23

The salivary, parotid, and thyroid glands are unremarkable.



PATIENT COMPUTED TOMOGRAPHIC DIAGNOSIS

- Bessie Ortolf**
- Abnormal thickening of the soft palate, the differential diagnosis includes hypertrophy that occurs in the brachycephalic breed, and concurrent pharyngitis. The consequence is an obstruction of the airway in the nasopharyngeal portion.
- SPECIES**
- Aberrant turbinates within the nasopharyngeal meatus, incidental and correlated to the brachycephalic breed.
- Canine**
- Tracheal hypoplasia.
 - Enlarged left retropharyngeal lymph node, reactive lymphadenitis.

BREED INTERPRETATION OF THE FINDINGS & FURTHER RECOMMENDATIONS

English Bulldog The detected tomographic findings are correlated to brachycephalic obstructive airway syndrome. Based on the reviewed literature, a positive correlation between the thickness of the soft palate and the severity of the clinical signs exists*.

SEX

FS *Grand, J.-G.R. and Bureau, S. (2011), Structural characteristics of the soft palate and meatus nasopharyngeus in brachycephalic and non-brachycephalic dogs analysed by CT. Journal of Small Animal Practice, 52: 232-239. <https://doi.org/10.1111/j.1748-5827.2011.01047.x>

AGE

11 Months

INTERPRETED BY

Tilde Rodrigues Froes, DMV, MSc., Dr. Med Vet., Dipl. CBraRVet

HOSPITAL NAME

Scottsdale Veterinary Clinic

REFERRING VET

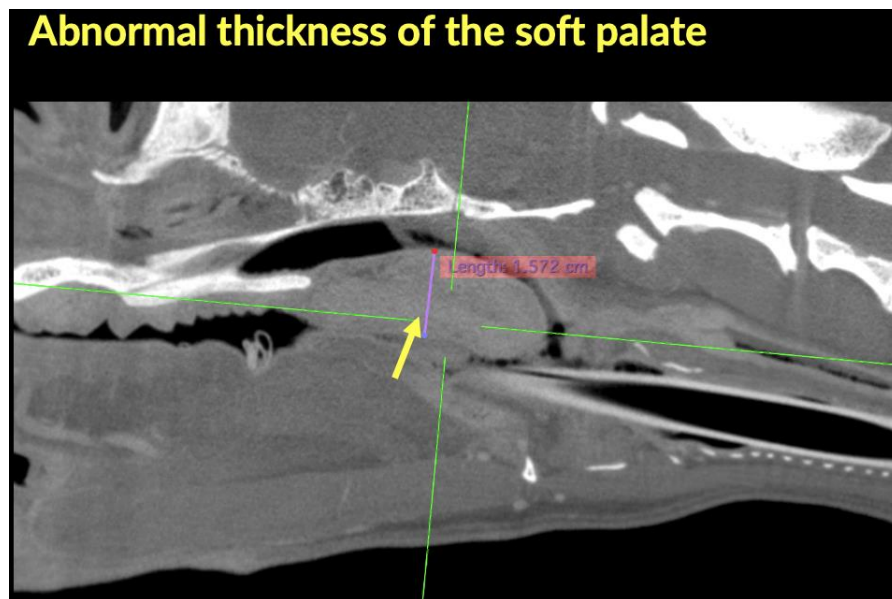
Dr. Blackmon

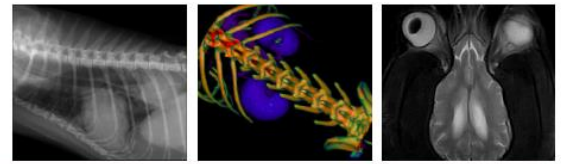
INVOICE

59877

DATE

8-22-23





PATIENT

Bessie Ortolf

SPECIES

Canine

BREED

English Bulldog

SEX

FS

AGE

11 Months

INTERPRETED BY

Tilde Rodrigues Froes,
DMV, MSc., Dr. Med
Vet., Dipl. CBraRVet

HOSPITAL NAME

Scottsdale Veterinary
Clinic

REFERRING VET

Dr. Blackmon

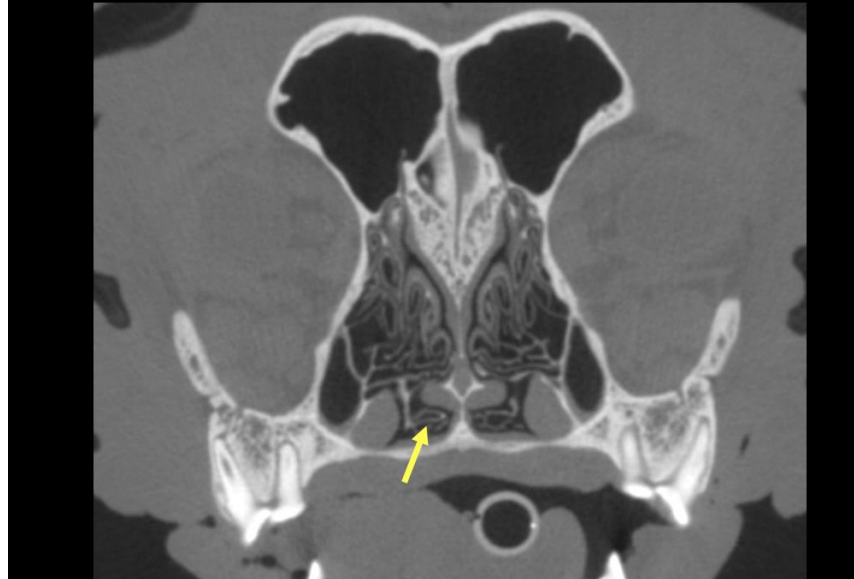
INVOICE

59877

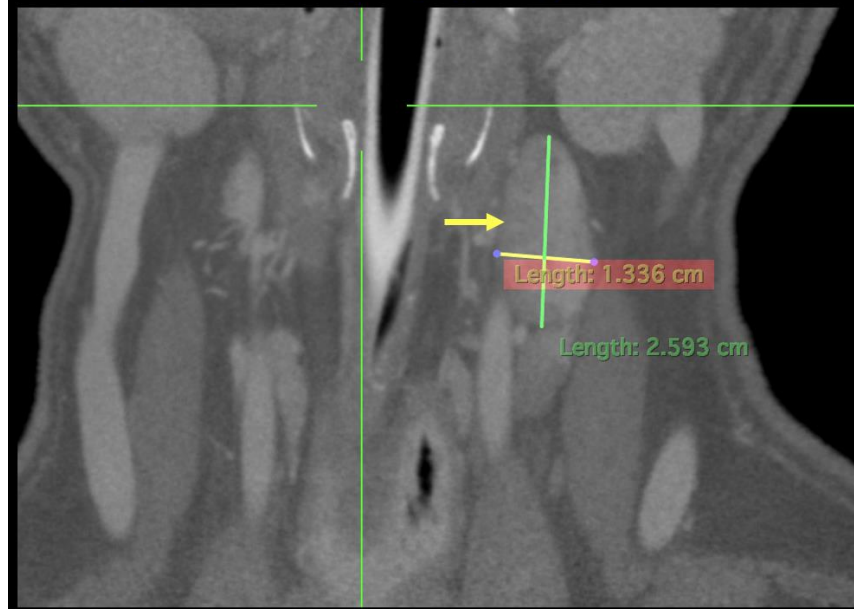
DATE

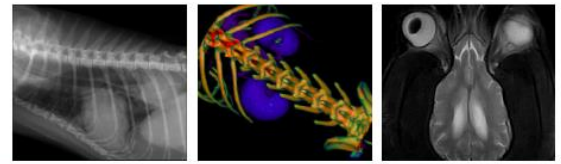
8-22-23

Aberrant turbinates within the nasopharyngeal meatus



Enlarged left retropharyngeal lymph node





PATIENT

Bessie Ortolf

The information and recommendations provided are based on the images presented by the referring veterinarian. No evaluation can be communicated regarding pathology that was not visible in the image/video clips provided.

SPECIES

Canine

Thank you for this referral. If the clinical or image interpretation does not parallel your findings or if I can be of any further assistance please contact me.

Tilde Rodrigues Froes, DMV, MSc., Dr. Med.Vet., Dipl.CBraRVet
info@sonopath.com

BREED

English Bulldog

SEX

FS

AGE

11 Months

INTERPRETED BY

Tilde Rodrigues Froes,
DMV, MSc., Dr. Med
Vet., Dipl. CBraRVet

HOSPITAL NAME

Scottsdale Veterinary
Clinic

REFERRING VET

Dr. Blackmon

INVOICE

59877

DATE

8-22-23