



PATIENT PRESENTING CLINICAL SIGNS

PATIENT Niddo Kitty Jirges Presented last July 12, 2023 Not eating since yesterday. Will lick food, was eating a paste food Swollen jaw - O noticed 2 days ago - was eating at first Drinking normally, but O did have to fill the water bowl C/S/V/D none L/B lump on back tail - has been there for a while - not too concerned about it Indoor/outdoor - lives on farm - not much for outdoor cats Possible kidney issues for quite some time - urinary issues- picky with litter boxes - will urinate out of the box PE: BAR; friendly; p/m mm; CRT 1-2s; no mur/arrh; no abn lung sounds; no abd dist; no pain or abns on abd palp; eyes, ears, LNs WNL; ambulating normally; BCS-3-4/9; mod dental dz, sl halitosis, R mandible is swollen and painful, discussed options to O, pulled blood, sedated; US- fluid pocket; sl irregular mandible; lanced and drained; adm Convenia SQ chem and cbc- nsf Assessment: mod dental dz mandibular swelling RO neoplasia vs abscess vs injury vs dental trauma- open Aug 2, 2023 Lump is back under jaw Saw on 7/12 for one lump On right side on Friday/Thursday noticed and has gone down a little Has normal energy E/D good Meds: none PE: focal swelling of 404, firm to touch; focal gingival inflammation in 407 Assessment: RO neoplasia vs dental dz

SPECIES Feline

BREED Domestic Medium Hair

SEX COMPUTED TOMOGRAPHIC STUDY OF THE HEAD

SEX FS A pre- contrast CT study of the head are provided for review totaling 1 series. One pre-contrast series of the head, bone algorithm.

AGE COMPUTED TOMOGRAPHIC FINDINGS

AGE 17 Years, 5 Months An expansile, amorphous, mixed, osteolytic, and proliferative bone lesion, predominantly osteolytic, is seen in the horizontal ramus of the right mandibula surrounding the alveolar bone and encompassing the adjacent teeth, triadans 407 and 408. There is a cortical interruption and indistinct transition zone. The lesion measures approximately 1.6cm by 1.0cm in length. A soft tissue mass effect is seen adjacently. A Severe reabsorption of the root of the triadan 407 with irregular lytic lesions at the dentine are seen.

INTERPRETED BY

Tilde Rodrigues Froes, DMV, MSc., Dr. Med Vet., Dipl. CBraRVet

There is diffuse horizontal and vertical bone loss adjacent to the remainder of the maxillary and mandibular teeth.

HOSPITAL NAME

State Avenue Vet Clinic

The nasal cavities, turbinates, choana, nasopharynx, and larynx are normal.

The cribriform plate is intact.

The frontal sinuses are unremarkable.

REFERRING VET

Dr. Jessie Evoniuk

The bulla cavities and external auditory canals are normal.

The temporomandibular joints are bilaterally congruent.

The globes and retrobulbar spaces are unremarkable.

INVOICE COMPUTED TOMOGRAPHIC DIAGNOSIS

- INVOICE** 59621
- Expansile mixed, osteolytic and proliferative bone lesion within the horizontal ramus of the right mandible, involving the adjacent teeth, triadans 407 and 408, and concurrent adjacent enlarged soft tissue mass effect. The differential diagnosis includes neoplasm process, for example,

DATE

8-2-23



PATIENT squamous cell carcinoma, fibrosarcoma, malignant melanoma, chondrosarcoma, osteosarcoma, or odontogenic tumor.

Niddo Kitty Jirges • Diffuse periodontal disease.

INTERPRETATION OF THE FINDINGS & FURTHER RECOMMENDATIONS

SPECIES

Feline

The tomographic findings of the right side horizontal mandible shows an aggressive lesion with involvement of the adjacent teeth, predominantly the triadan 407. In addition, the lesion increases in volume, and it is correlated to the presented clinical signs of right mandible pain and swelling. The primary differential diagnosis is neoplasm process; however, concurrent osteomyelitis is possible. The resectability is difficult because of the surgical safety margins. A consultation with an oncological specialist is suggested. A biopsy is required for diagnosis.

BREED

Domestic Medium Hair

SEX

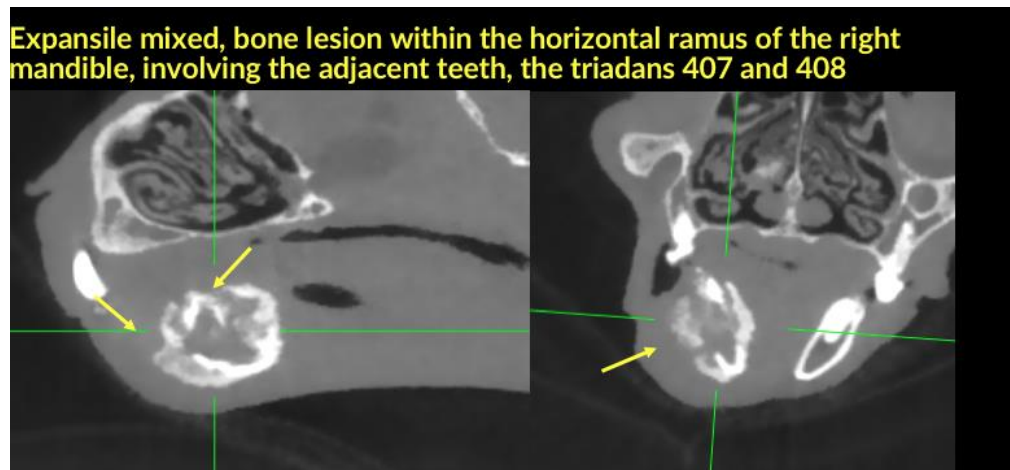FS

AGE

17 Years, 5 Months

INTERPRETED BY

Tilde Rodrigues Froes, DMV, MSc., Dr. Med Vet., Dipl. CBraRVet

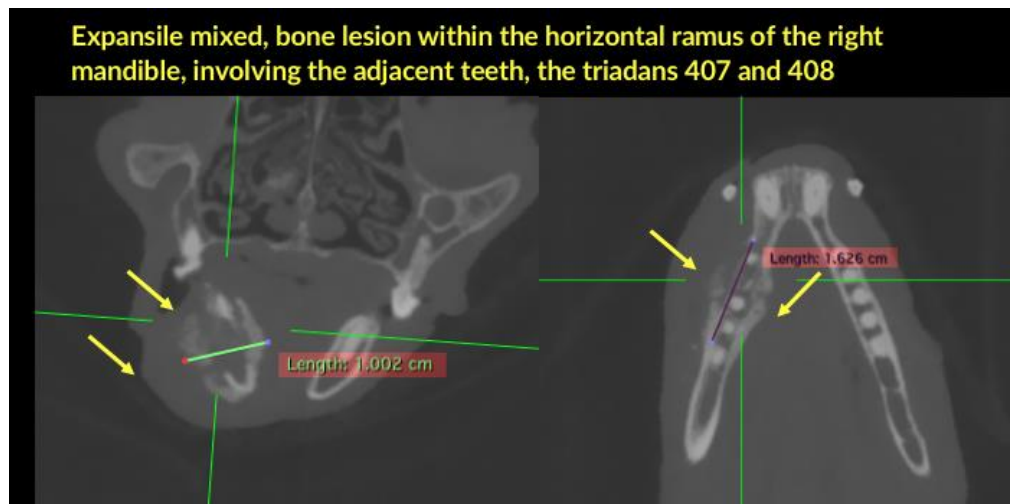


HOSPITAL NAME

State Avenue Vet Clinic

REFERRING VET

Dr. Jessie Evoniuk



INVOICE

59621

DATE

8-2-23



PATIENT

Niddo Kitty Jirges

SPECIES

Feline

The information and recommendations provided are based on the images presented by the referring veterinarian. No evaluation can be communicated regarding pathology that was not visible in the image/video clips provided.

BREED

Domestic Medium
Hair

Thank you for this referral. If the clinical or image interpretation does not parallel your findings or if I can be of any further assistance please contact me.

Tilde Rodrigues Froes, DMV, MSc., Dr. Med.Vet., Dipl.CBraRVet
info@sonopath.com

SEX

FS

AGE

17 Years, 5 Months

INTERPRETED BY

Tilde Rodrigues Froes,
DMV, MSc., Dr. Med
Vet., Dipl. CBraRVet

HOSPITAL NAME

State Avenue Vet
Clinic

REFERRING VET

Dr. Jessie Evoniuk

INVOICE

59621

DATE

8-2-23