



PATIENT PRESENTING CLINICAL SIGNS

Goldie Mancini Large mammary mass. Scheduled for Mastectomy and OHE. Met check first.
Abnormal PE/Chem/CBC/UA Results: Mild increased respiration rate and sounds, harsh upper airway sounds. Basic Chem and CBC within reference range Note, we were not able to position her in VD position due to anxiety, DV view submitted instead

SPECIES

Canine

RADIOGRAPHIC STUDY OF THE THORAX

Radiographs of the thorax, in three imaging planes are provided for review, totaling 3 images. One right lateral, one left lateral and one ventrodorsal view.

BREED

Lab Mix

RADIOGRAPHIC FINDINGS

The thoracic trachea is normal.

SEX

Female

The cardiac silhouette spans approximately 55% of the thoracic width, 3.0 intercostal spaces, with normal shape and contour. (VHS = 9.8). The pulmonary vessels are normal.

The pulmonary parenchyma is normal in opacity. No evidence of pulmonary soft tissue nodules.

AGE

13

The pleural space and mediastinum are normal. No evidence of enlarged mediastinal lymph nodes.

The diaphragm and thoracic wall are unremarkable.

The collimated musculoskeletal structures are normal.

INTERPRETED BY

Tilde Rodrigues Froes,
DMV, MSc., Dr. Med
Vet., Dipl. CBraRVet

RADIOGRAPHIC DIAGNOSIS

- Normal thorax
- No evidence of pulmonary metastatic disease.

HOSPITAL NAME

Lac Ste. Anne
Veterinary Services

INTERPRETATION OF THE FINDINGS & FURTHER RECOMMENDATIONS

The thoracic radiographs show a normal exam. No pulmonary or intrathoracic abnormalities were identified. No evidence of pulmonary metastatic disease.

REFERRING VET

Sarah Fryer

INVOICE

59623

DATE

8-2-23



PATIENT

Goldie Mancini

SPECIES

Canine

BREED

Lab Mix

SEX

Female

AGE

13

INTERPRETED BY

Tilde Rodrigues Froes,
DMV, MSc., Dr. Med
Vet., Dipl. CBraRVet

HOSPITAL NAME

Lac Ste. Anne
Veterinary Services

REFERRING VET

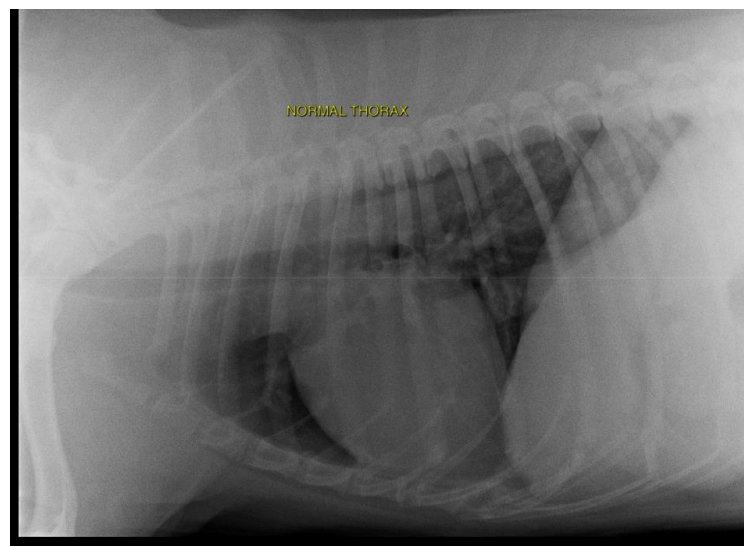
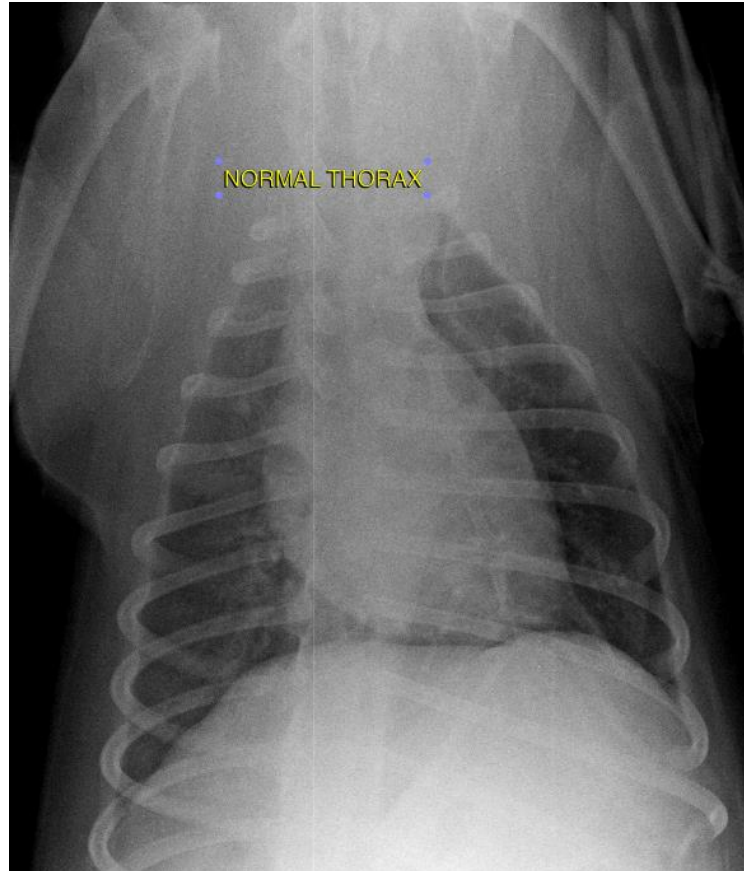
Sarah Fryer

INVOICE

59623

DATE

8-2-23





PATIENT

Goldie Mancini

The information and recommendations provided are based on the images presented by the referring veterinarian. No evaluation can be communicated regarding pathology that was not visible in the image/video clips provided.

SPECIES

Canine

Thank you for this referral. If the clinical or image interpretation does not parallel your findings or if I can be of any further assistance please contact me.

BREED

Lab Mix

Tilde Rodrigues Froes, DMV, MSc., Dr. Med.Vet., Dipl.CBraRVet
info@sonopath.com

SEX

Female

AGE

13

INTERPRETED BY

Tilde Rodrigues Froes,
DMV, MSc., Dr. Med
Vet., Dipl. CBraRVet

HOSPITAL NAME

Lac Ste. Anne
Veterinary Services

REFERRING VET

Sarah Fryer

INVOICE

59623

DATE

8-2-23