



**PATIENT PRESENTING CLINICAL SIGNS**

Shai Z Leonkovho  
Raja "Shay" GHC  
Greendyk

Preliminary screen for OFA rads

**RADIOGRAPHIC STUDY OF THE THORACIC LIMBS**

Two flexed lateral views of the thoracic limbs, focus on elbow joints, are provided for review.

**SPECIES RADIOGRAPHIC FINDINGS**

Canine **Left Thoracic Limb**

There is humeroulnar and humeroradial joint incongruity.

**BREED**

Leonberger

The apex of the medial coronoid process of the ulna is blunted.

Mild sclerosis of the subchondral bone of the semi lunar notch is seen.

**SEX** There is mild periarticular ossification in the proximal margin of the anconeal process of the ulna.

Male **Right Thoracic Limb**

There is humeroulnar and humeroradial joint incongruity.

**AGE**

3 Years, 4 Months

The apex of the medial coronoid process of the ulna is blunted.

Mild sclerosis of the subchondral bone of the semi lunar notch is seen.

**INTERPRETED BY RADIOGRAPHIC DIAGNOSIS**

Tilde Rodrigues Froes,  
DMV, MSc., Dr. Med  
Vet., Dipl. CBraRVet

- The apex of the medial coronoid process of the left and right ulna is blunted with elbow joint incongruity and indicates medial coronoid disease with mild secondary osteoarthritis (> Left side).

**INTERPRETATION OF THE FINDINGS & FURTHER RECOMMENDATIONS**

**HOSPITAL NAME**

Blairstown Animal  
Hospital

The bilateral radiographic findings of the elbow joints indicate medial coronoid disease. Correlation with clinical orthopedical history is suggested. A complete radiographic exam with all views, or computed tomography is suggested for further evaluation and confirmation.

**REFERRING VET**

Dr. Lovell

**INVOICE**

59772

**DATE**

8-17-23



**PATIENT**

Shai Z Leonkovho  
Raja "Shay" GHC  
Greendyk

**SPECIES**

Canine

**BREED**

Leonberger

**SEX**

Male

**AGE**

3 Years, 4 Months

**INTERPRETED BY**

Tilde Rodrigues Froes,  
DMV, MSc., Dr. Med  
Vet., Dipl. CBraRVet

**HOSPITAL NAME**

Blairstown Animal  
Hospital

**REFERRING VET**

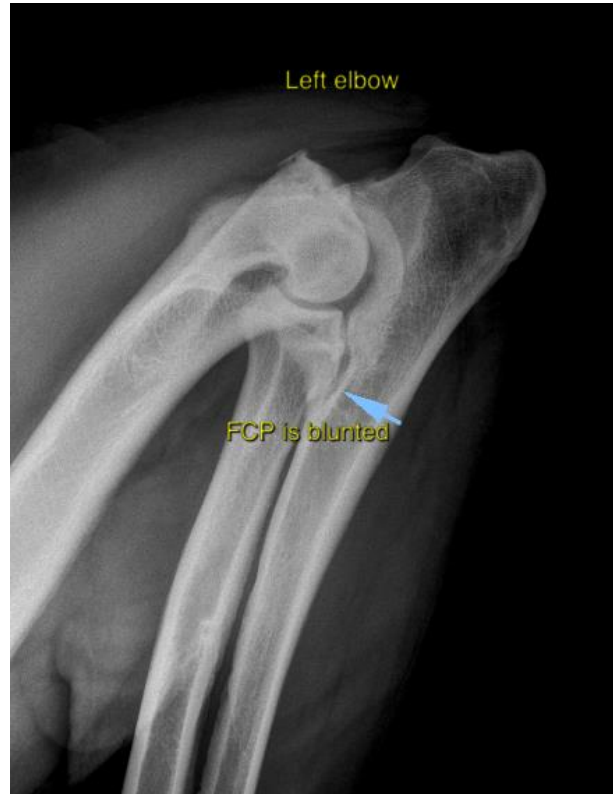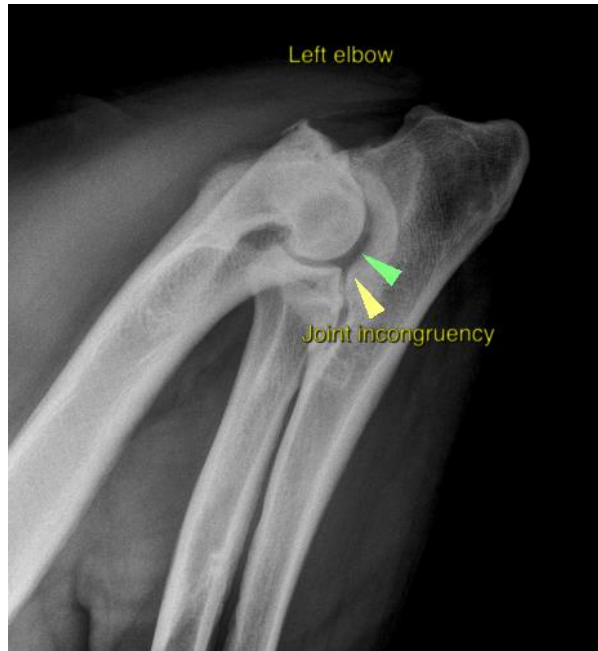
Dr. Lovell

**INVOICE**

59772

**DATE**

8-17-23





**PATIENT**

Shai Z Leonkovho  
Raja "Shay" GHC  
Greendyk

**SPECIES**

Canine

**BREED**

Leonberger

**SEX**

Male

**AGE**

3 Years, 4 Months

**INTERPRETED BY**

Tilde Rodrigues Froes,  
DMV, MSc., Dr. Med  
Vet., Dipl. CBraRVet

**HOSPITAL NAME**

Blairstown Animal  
Hospital

**REFERRING VET**

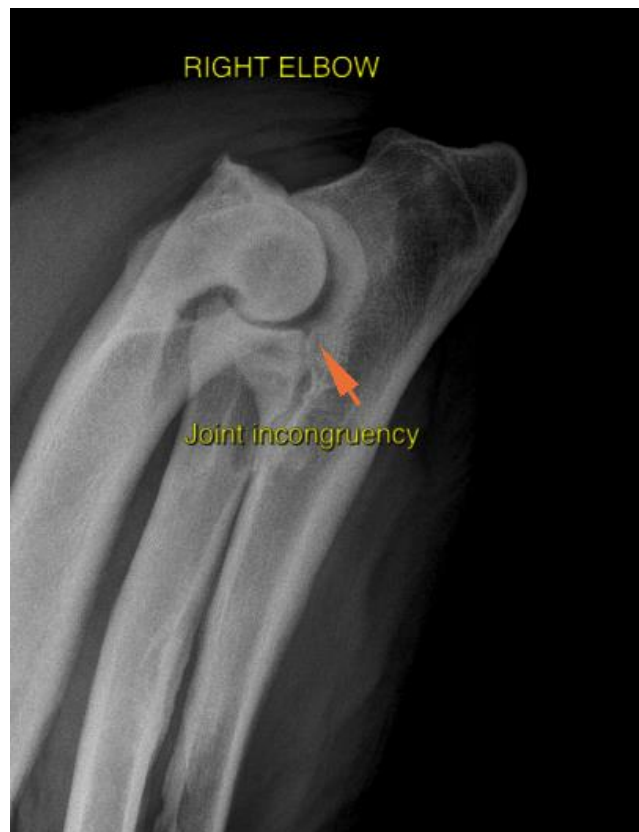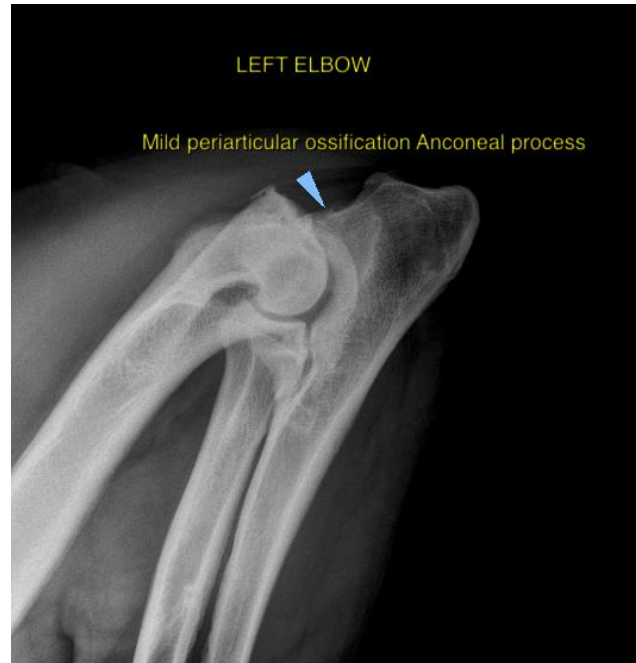
Dr. Lovell

**INVOICE**

59772

**DATE**

8-17-23





**PATIENT**

Shai Z Leonkovho  
Raja "Shay" GHC  
Greendyk

**SPECIES**

Canine

**BREED**

Leonberger

**SEX**

Male

**AGE**

3 Years, 4 Months

**INTERPRETED BY**

Tilde Rodrigues Froes,  
DMV, MSc., Dr. Med  
Vet., Dipl. CBraRVet

**HOSPITAL NAME**

Blairstown Animal  
Hospital

**REFERRING VET**

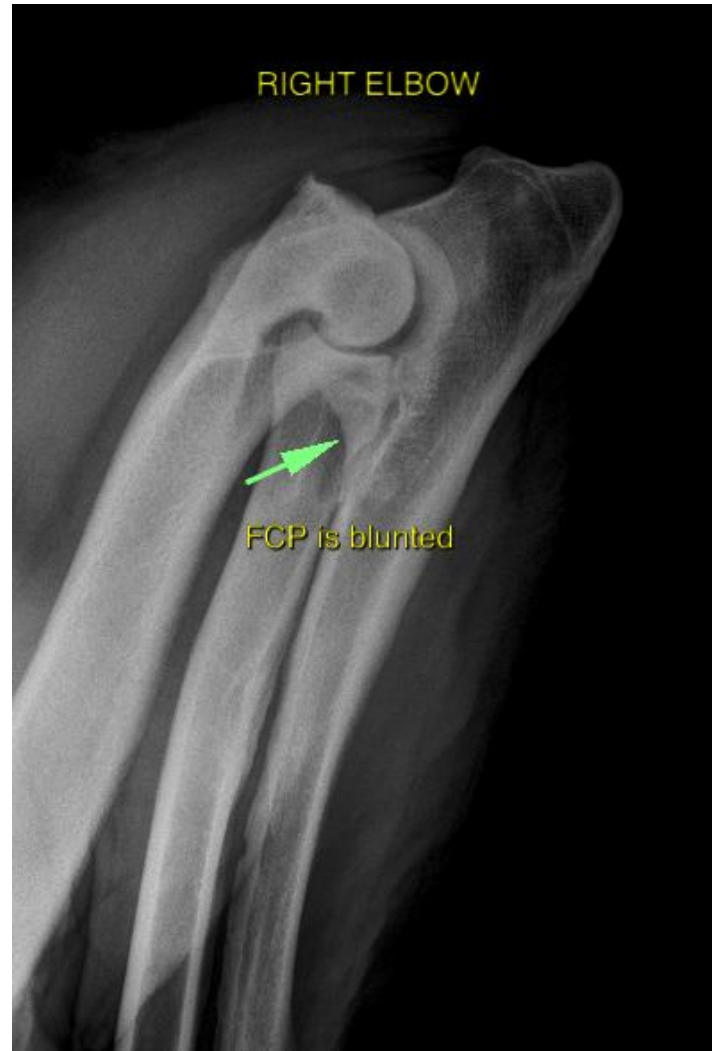Dr. Lovell

**INVOICE**

59772

**DATE**

8-17-23



The information and recommendations provided are based on the images presented by the referring veterinarian. No evaluation can be communicated regarding pathology that was not visible in the image/video clips provided.

Thank you for this referral. If the clinical or image interpretation does not parallel your findings or if I can be of any further assistance please contact me.

**Tilde Rodrigues Froes**, DMV, MSc., Dr. Med.Vet., Dipl.CBraRVet  
info@sonopath.com