



PATIENT PRESENTING CLINICAL SIGNS

Jack McKenney P presented for grade 1 heart murmur (declined echocardiogram at this time) and pre-op chest radiographs to check for mets. P has a mass removal (1-2 masses neck and leg) and high grade dental surgery scheduled.

SPECIES Abnormal PE/Chem/CBC/UA Results: Left lateral image obtained today was repeated (so 2 images of L lateral submitted) because abnormality was believed to be seen dorsal caudal thorax. Thyroid: TT4 0.5 - low, FT4 8.0 - low normal Chem: Alk phos 281 (was 261 last year) and creat 1.0 (normal)
Canine

RADIOGRAPHIC STUDY OF THE THORAX

BREED Orthogonal views of the thorax are provided for review totaling four images. One right lateral, two left lateral and one ventrodorsal view.
Lab Mix

RADIOGRAPHIC FINDINGS

SEX A rounded, predominantly homogeneous with partially defined contour soft tissue opaque mass effect is seen superimposed on the dorsal diaphragm and caudodorsal lung lobes, better seen on the lateral views. The soft tissue mass appears differently between the lateral views, sometimes with more heterogeneous characteristics with inner gas, and sometimes the soft tissue mass is not detected. The mass effect measures approximately 5.0cm by 4.2cm when visible.
NM

AGE The thoracic cranial esophagus is mildly gas-filled.
14 Years, 1 Month

The trachea is normal in luminal height diameter and pathway.

INTERPRETED BY The pulmonary parenchyma is normal in volume of expansion and normal opacification.

Tilde Rodrigues Froes, DMV, MSc., Dr. Med Vet., Dipl. CBraRVet The cardiac silhouette spans approximately 50% of the thoracic width, 3.0 intercostal spaces, with normal shape. (VHS = 10.5; VLAS = 1.9). The pulmonary vessels are normal.

The pleural space is normal. No evidence of enlarged mediastinal lymph nodes.

HOSPITAL NAME Only seen on the right lateral view, a lenticular homogeneously fat opaque mass is seen in the subcutaneous tissue ventrally to the 5th to 7th sternebrae, measuring approximately 6.7cm by 1.3cm in length.
RB Northside Animal Hospital

The musculoskeletal structures are unremarkable.

REFERRING VET The collimated abdomen is unremarkable.

Dr. Leslie Agulnick **RADIOGRAPHIC DIAGNOSIS**

- INVOICE**
- Variably visible between the lateral views, rounded soft tissue mass effect, superimposed with the dorsal diaphragm and lung lobes, the differential diagnosis includes sliding hiatal hernia.
 - No evidence of pulmonary metastatic disease.
 - Normal thorax
 - Ventral subcutaneous soft tissue lipoma

DATE

8-17-23



PATIENT INTERPRETATION OF THE FINDINGS & FURTHER RECOMMENDATIONS

Jack McKenney

The previously identified mass effect is located in the caudal mediastinum in the position of the caudal esophagus. The variable visibility of this structure and the radiographic characteristics indicate a hiatal hernia (sliding) and could be incidental. Concurrent esophagitis could be considered. Consider an endoscopic examination if the patient presents any clinical signs of esophagitis for further investigation. There is no evidence of pulmonary abnormality or metastatic pulmonary disease.

SPECIES

Canine

There were no signs of an enlarged cardiac silhouette. Due to the identification of the cardiac murmur, consider cardiac disease at the stage of not producing secondary radiographic changes.

BREED

Lab Mix

SEX

NM

AGE

14 Years, 1 Month

INTERPRETED BY

Tilde Rodrigues Froes,
DMV, MSc., Dr. Med
Vet., Dipl. CBraRVet

HOSPITAL NAME

RB Northside Animal
Hospital

REFERRING VET

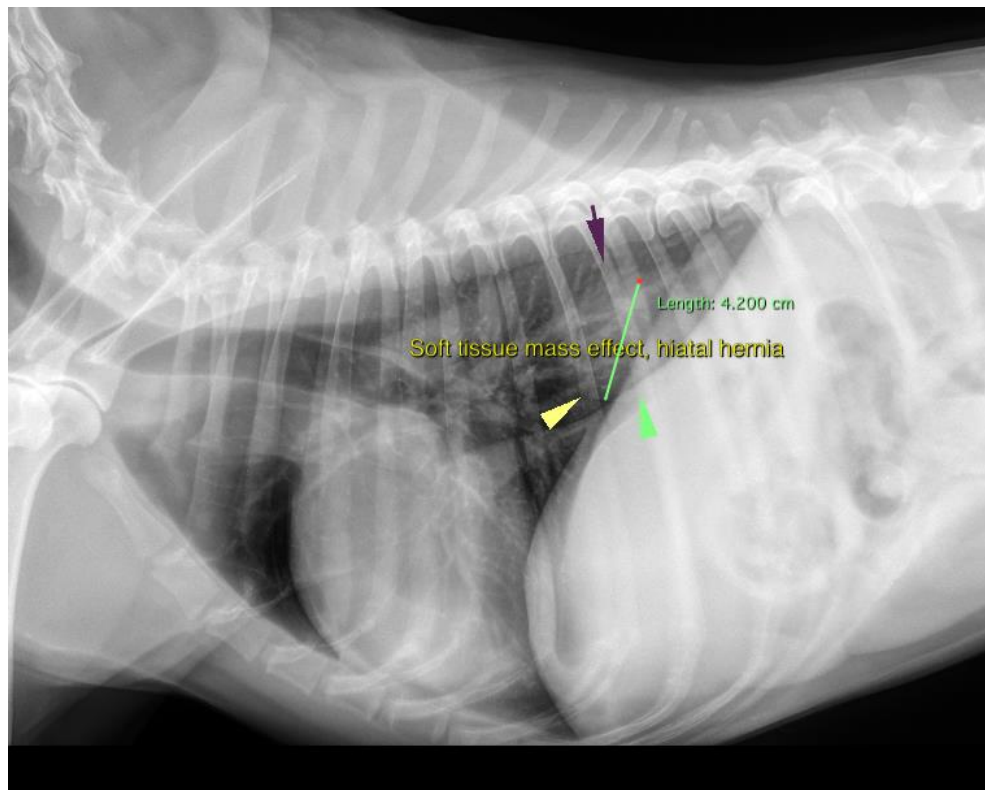
Dr. Leslie Agulnick

INVOICE

59781

DATE

8-17-23





PATIENT

Jack McKenney

SPECIES

Canine

BREED

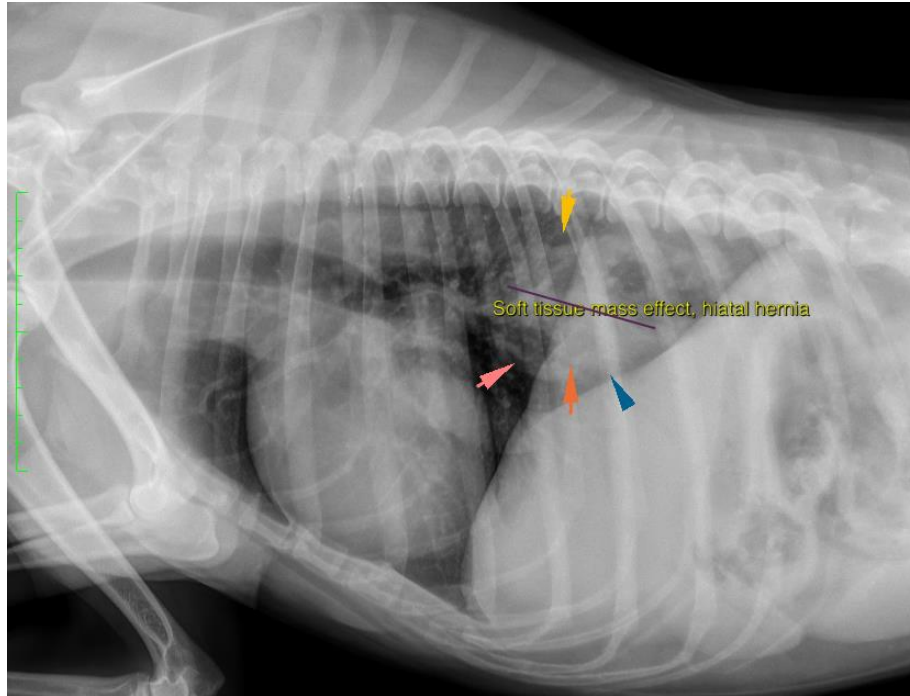
Lab Mix

SEX

NM

AGE

14 Years, 1 Month



INTERPRETED BY

Tilde Rodrigues Froes,
DMV, MSc., Dr. Med
Vet., Dipl. CBraRVet

HOSPITAL NAME

RB Northside Animal
Hospital

REFERRING VET

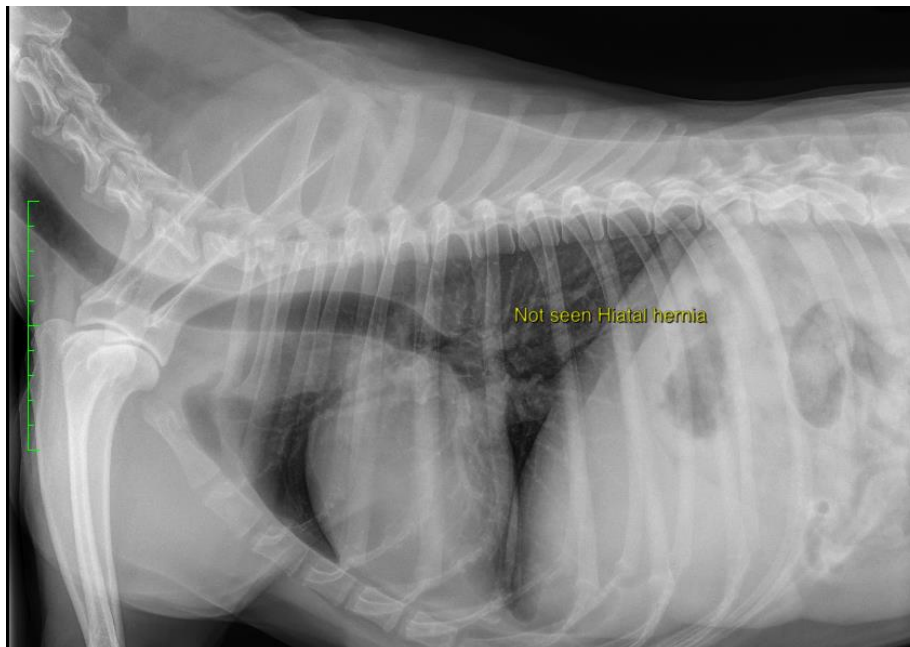
Dr. Leslie Agulnick

INVOICE

59781

DATE

8-17-23





PATIENT

Jack McKenney

SPECIES

Canine

BREED

Lab Mix

SEX

NM

AGE

14 Years, 1 Month

INTERPRETED BY

Tilde Rodrigues Froes,
DMV, MSc., Dr. Med
Vet., Dipl. CBraRVet

HOSPITAL NAME

RB Northside Animal
Hospital

REFERRING VET

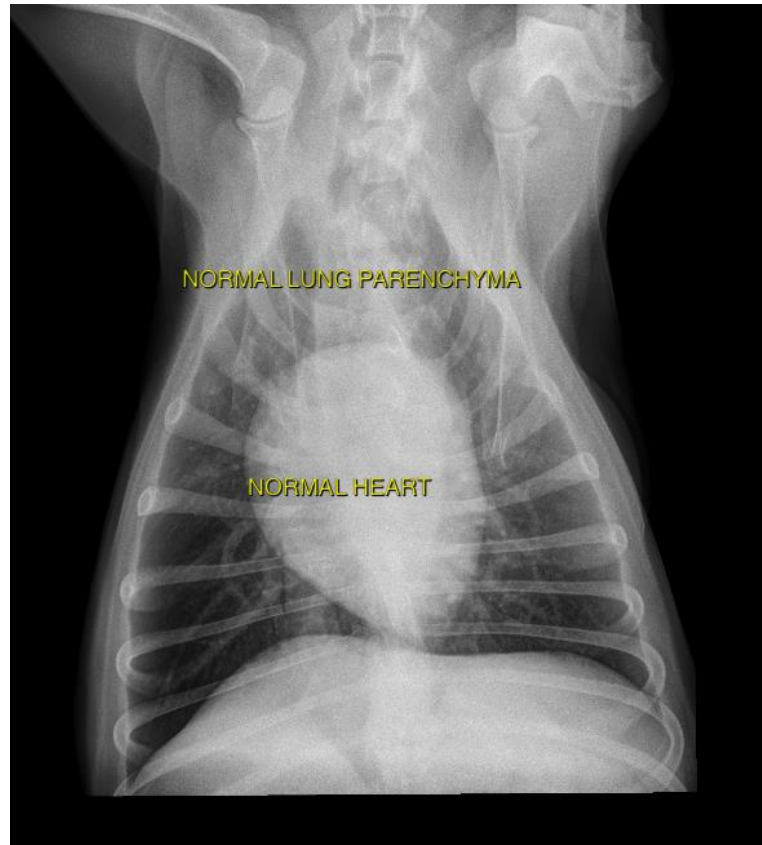
Dr. Leslie Agulnick

INVOICE

59781

DATE

8-17-23



The information and recommendations provided are based on the images presented by the referring veterinarian. No evaluation can be communicated regarding pathology that was not visible in the image/video clips provided.

Thank you for this referral. If the clinical or image interpretation does not parallel your findings or if I can be of any further assistance please contact me.

Tilde Rodrigues Froes, DMV, MSc., Dr. Med.Vet., Dipl.CBraRVet
info@sonopath.com