



PATIENT PRESENTING CLINICAL SIGNS

Tia Hofmiller Possible mass or kidney palpated in the mid cranial abdomen. No hx of constipation. P has lost weight. Hx of hyperthyroidism - has been on medication for years.

SPECIES RADIOGRAPHIC STUDY OF ABDOMEN

Feline Orthogonal views of the abdomen are available for review totaling three images. One ventrodorsal view, one right lateral and one left lateral view.

BREED RADIOGRAPHIC FINDINGS

DSH The liver and spleen are normal in size, shape, and contour.

The stomach contains a moderate amount of gas admixed with heterogeneous opaque ingesta material, which redistributes with the patient position.

SEX

Spayed Female The small intestines are normally distributed, mildly distended, and contain a moderate amount of gas homogeneous soft tissue fluid material.

AGE

The descending colon contains a moderate amount of heterogeneous soft tissue to dense opaque fecal material.

16 Years, 11 Months The right renal silhouette is partially identified, however, no evidence of enlarged renal silhouettes. The left renal silhouette is normal in size, shape, and contour.

INTERPRETED BY

The urinary bladder is moderately filled with the apex in the plane of cranial L5 and is homogeneously soft tissue opaque.

Tilde Rodrigues Froes, DMV, MSc., Dr. Med Vet., Dipl. CBraRVet

The abdominal serosal detail is normal, no mass effect is identified.

Multifocal thoracic, lumbar, and lumbosacral complete and incomplete spondylosis deformans are seen. Narrowing of the intervertebral disc spaces L6-L7 and L7-S1 is noted.

HOSPITAL NAME

Normal collimated geriatric thoracic structures.

The Pet Hospital of Stratford

RADIOGRAPHIC DIAGNOSIS

REFERRING VET

Dr. David

- Post-prandial stomach.
- Mild constipation.
- No evidence of mass effect in the abdomen
- Otherwise, normal abdomen.
- Multifocal spondylosis deformans, and variable chronic disc disease, with or without spinal cord and neural root impingement.

INVOICE INTERPRETATION OF THE FINDINGS & FURTHER RECOMMENDATIONS

59599 No radiographic abnormalities were identified in the abdominal cavity that could explain the clinical sign of weight loss. An abdominal ultrasound may be useful to evaluate the gastrointestinal tract, including gastrointestinal wall layering and thickness An abdominal ultrasound also has higher sensibility to detect mesenteric lymph node abnormalities, or other parenchymal disease.

DATE

8-1-23



PATIENT

Tia Hofmiller

SPECIES

Feline

BREED

DSH

SEX

Spayed Female

AGE

16 Years, 11 Months

INTERPRETED BY

Tilde Rodrigues Froes,
DMV, MSc., Dr. Med
Vet., Dipl. CBraRVet

HOSPITAL NAME

The Pet Hospital of
Stratford

REFERRING VET

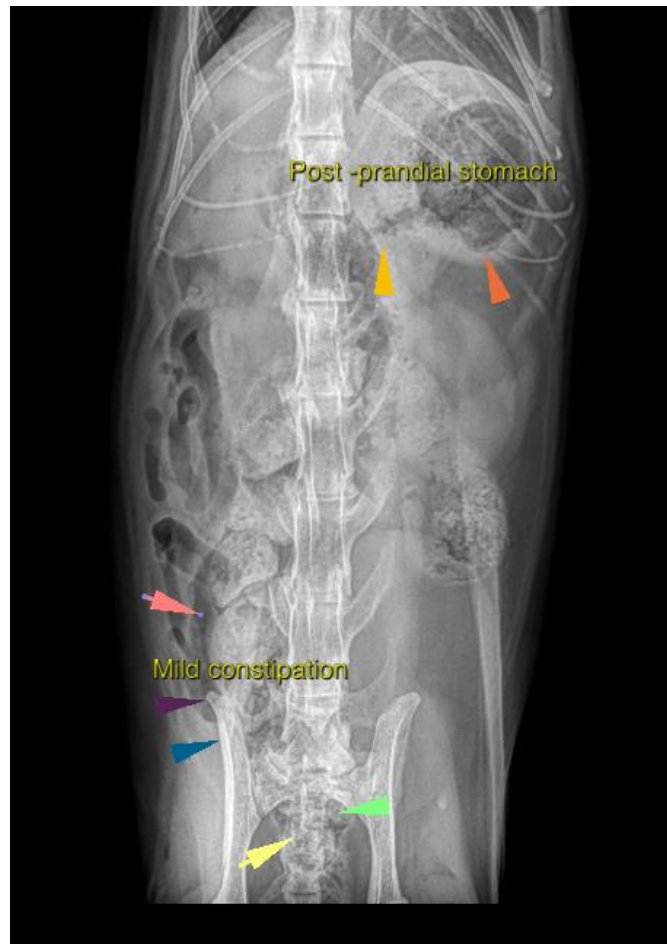
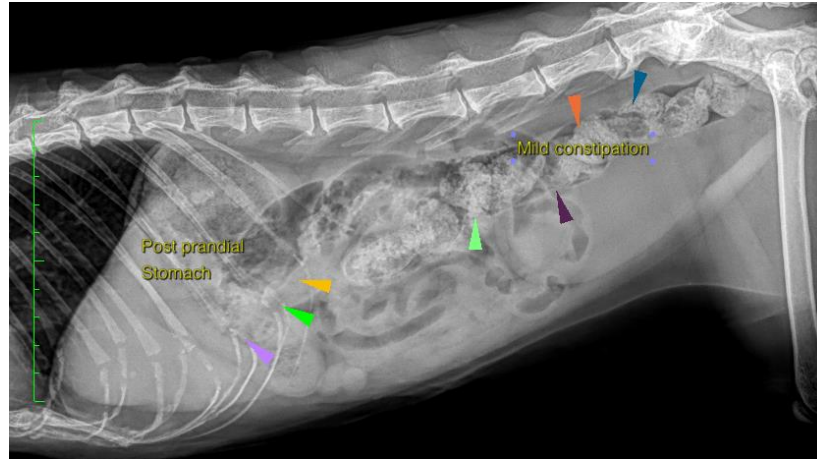
Dr. David

INVOICE

59599

DATE

8-1-23





PATIENT

Tia Hofmiller

The information and recommendations provided are based on the images presented by the referring veterinarian. No evaluation can be communicated regarding pathology that was not visible in the image/video clips provided.

SPECIES

Feline

Thank you for this referral. If the clinical or image interpretation does not parallel your findings or if I can be of any further assistance please contact me.

BREED

DSH

Tilde Rodrigues Froes, DMV, MSc., Dr. Med.Vet., Dipl.CBraRVet
info@sonopath.com

SEX

Spayed Female

AGE

16 Years, 11 Months

INTERPRETED BY

Tilde Rodrigues Froes,
DMV, MSc., Dr. Med
Vet., Dipl. CBraRVet

HOSPITAL NAME

The Pet Hospital of
Stratford

REFERRING VET

Dr. David

INVOICE

59599

DATE

8-1-23