



PATIENT PRESENTING CLINICAL SIGNS

Marley Spicer chronic idiopathic hepatopathy >1yr cutaneous lymphoma left side of nose noted peach seed in stomach removed via endoscopy
Abnormal PE/Chem/CBC/UA Results: cbc/chem wl

SPECIES

Canine

COMPUTED TOMOGRAPHIC STUDY OF THE HEAD AND THORAX

A pre- and post-contrast CT study of the cervical soft tissue and thorax are provided for review totaling 4 series. Three pre-contrast series of the cervical soft tissue and thorax, soft tissue, bone and lung algorithms. One post-contrast series of the cervical soft tissue and thorax, soft tissue algorithm.

BREED

Lab

COMPUTED TOMOGRAPHIC FINDINGS

CERVICAL SOFT TISSUE

SEX

The cervical soft tissue structures are normal, no mass effect is identified.

FN

The cervical muscle mass is symmetrical, and unremarkable.

AGE

No evidence of enlarged cervical lymph nodes.

7

The medial retropharyngeal lymph nodes and mandibular lymph nodes are unremarkable.

The salivary and thyroid glands are unremarkable.

INTERPRETED BY

Tilde Rodrigues Froes,
DMV, MSc., Dr. Med
Vet., Dipl. CBraRVet

The nasopharynx, larynx, and cervical trachea are unremarkable.

THORAX

The trachea is normal in luminal diameter and position.

HOSPITAL NAME

Advanced Veterinary
Imaging

The lumen of the main bronchus is normal.

Two hyperattenuating foci measuring 0.1cm are seen in the subpleural pulmonary parenchyma. The remaining pulmonary parenchyma is normal in volume expansion and attenuation.

REFERRING VET

Eamon

The cardiac silhouette and pulmonary vessels are normal. The contrast media adequately fills the cardiac chambers and vessels on post-contrast series.

The tracheobronchial lymph nodes are normal.

The sternal, mediastinal, and cranial mediastinal lymph nodes are unremarkable.

INVOICE

The pleural space and diaphragm are normal.

59616

On the collimated abdomen, a small mineral attenuating object is seen admixed within the stomach lumen, and measures 1.4cm by 1.8cm.

DATE

8-1-23



PATIENT The liver is homogenously soft tissue attenuating and uniformly contrast enhancing with normal size and shape. The gallbladder is unremarkable.

Marley Spicer

Few mineral osseous bodies are seen within the intertubercle groove of the shoulder joints, bilaterally.

SPECIES

Canine

BREED

Lab

COMPUTED TOMOGRAPHIC DIAGNOSIS

- Normal cervical structures, no mass effect or enlarged lymph nodes.
- Few pulmonary incidental osteomas, otherwise normal thorax.
- Bilateral shoulder intertubercular groove osseous bodies, bicipital tenosynovitis, shoulder osteoarthritis.
- Non-obstructive gastric mineral attenuating material, peach seed as correlated to the clinical history.

SEX INTERPRETATION OF THE FINDINGS & FURTHER RECOMMENDATIONS

FN A few incidental osteomas and non-obstructive small gastric foreign material are seen, and are clinically insignificant. No evidence of pulmonary metastatic disease or enlarged lymph nodes.

AGE

7

INTERPRETED BY

Tilde Rodrigues Froes,
DMV, MSc., Dr. Med
Vet., Dipl. CBraRVet

HOSPITAL NAME

Advanced Veterinary
Imaging

REFERRING VET

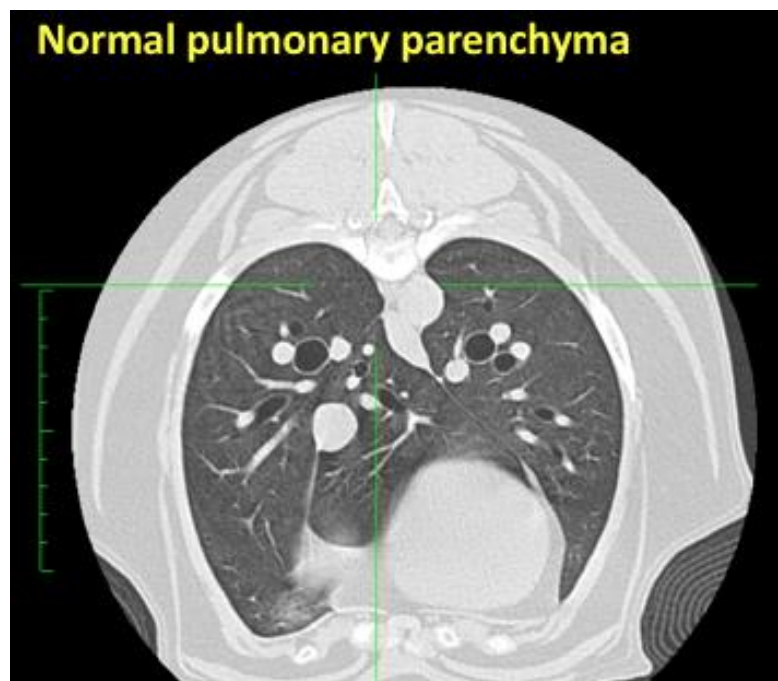
Eamon

INVOICE

59616

DATE

8-1-23





PATIENT

Marley Spicer

SPECIES

Canine

BREED

Lab

SEX

FN

AGE

7

INTERPRETED BY

Tilde Rodrigues Froes,
DMV, MSc., Dr. Med
Vet., Dipl. CBraRVet

HOSPITAL NAME

Advanced Veterinary
Imaging

REFERRING VET

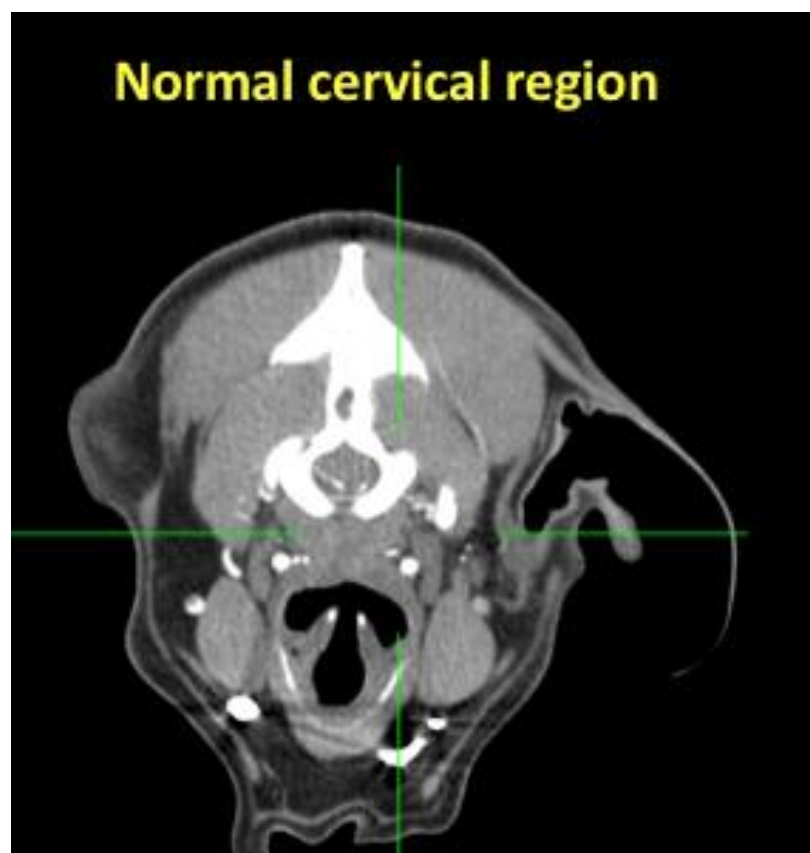
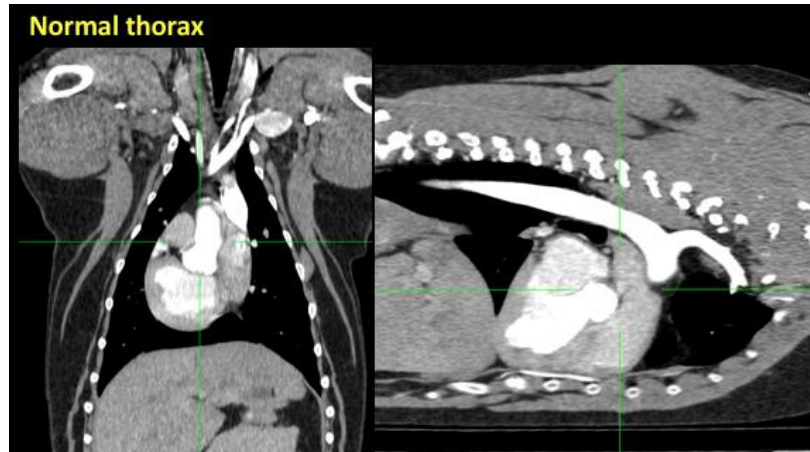Eamon

INVOICE

59616

DATE

8-1-23





PATIENT

Marley Spicer

SPECIES

Canine

BREED

Lab

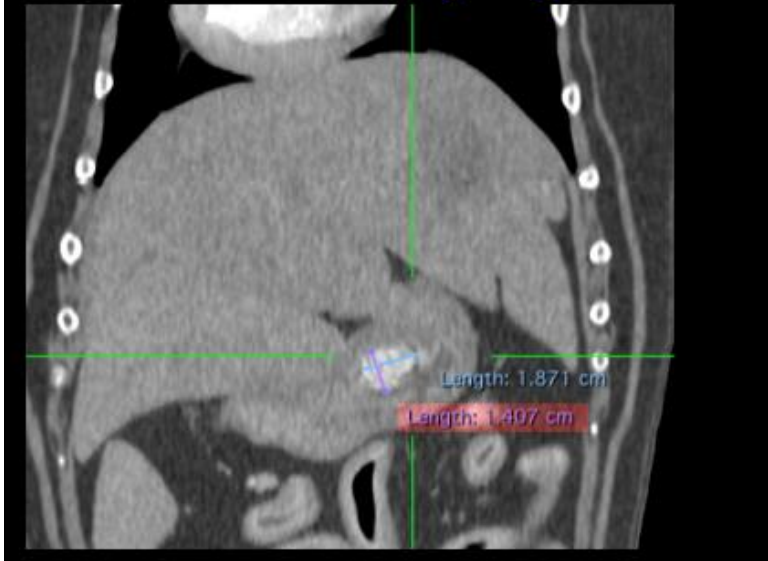SEX

FN

AGE

7

Non obstructive attenuating foreign material



INTERPRETED BY

Tilde Rodrigues Froes,
DMV, MSc., Dr. Med
Vet., Dipl. CBraRVet

The information and recommendations provided are based on the images presented by the referring veterinarian. No evaluation can be communicated regarding pathology that was not visible in the image/video clips provided.

Thank you for this referral. If the clinical or image interpretation does not parallel your findings or if I can be of any further assistance please contact me.

HOSPITAL NAME

Advanced Veterinary
Imaging

Tilde Rodrigues Froes, DMV, MSc., Dr. Med.Vet., Dipl.CBraRVet
info@sonopath.com

REFERRING VET

Eamon

INVOICE

59616

DATE

8-1-23