



PATIENT PRESENTING CLINICAL SIGNS

Cooper Strazza Reason for Ultrasound: Acute onset Left pelvic limb lameness. No history of injury Current Meds: Carprofen 75mg BID
Abnormal PE/Chem/CBC/UA Results: NA

SPECIES

Canine

RADIOGRAPHIC STUDY OF THE PELVIS AND PELVIC LIMBS

Radiographs of the pelvic limbs in two imaging planes are provided for review totaling 5 images. One ventrodorsal view, one lateral view focus on the right stifle joint, and one lateral view focus on the left stifle joint. One lateral view focus on left tarsal joint. One dorsoplantar view focus on left tarsal joint.

BREED

Labrador Retriever

RADIOGRAPHIC FINDINGS

There is regional soft tissue swelling surrounding the left tarsus and spreading out dorsally and laterally throughout the tarsocrural joint and dorsal surface of the proximal region of the metatarsal bone.

SEX

MN

No evidence of acute traumatic fracture, or aggressive bone disease.

AGE

12 Years

The coxofemoral joints are congruent, normal pelvis.

There is adequate coverage of the femoral heads by the dorsal acetabular margins of approximately 50%.

The stifle joints and fat-pad opacity are normal.

INTERPRETED BY

Tilde Rodrigues Froes, DMV, MSc., Dr. Med Vet., Dipl. CBraRVet

RADIOGRAPHIC DIAGNOSIS

- Extra-articular and/or intra-articular soft tissue swelling of the left tarsocrural and tarsal joints. The differential diagnosis includes soft tissue swelling correlated to inflammatory effusion, possible crural extensor retinaculum or tarsal extensor retinaculum partial tear, lateral collateral ligament partial tear.
- Normal pelvis and coxofemoral joints
- Normal stifle joints.

HOSPITAL NAME

Byram Animal Hospital

INTERPRETATION OF THE FINDINGS & FURTHER RECOMMENDATIONS

A left tarsocrural and tarsal swelling are likely correlated to the acute lameness of the left limb. The swelling indicates that a more acute stress occurs. Correlate these radiographic findings with specific orthopedic exams. Conservative therapy is suggested with non-steroidal anti-inflammatories in this acute phase and pain medication is suggested. If patient does not improve, a musculoskeletal ultrasound is suggested.

REFERRING VET

Dr. Carlos Abdul-Chani

INVOICE

59186

DATE

7-6-23



PATIENT

Cooper Strazza

SPECIES

Canine

BREED

Labrador Retriever

SEX

MN

AGE

12 Years

INTERPRETED BY

Tilde Rodrigues Froes,
DMV, MSc., Dr. Med
Vet., Dipl. CBraRVet

HOSPITAL NAME

Byram Animal
Hospital

REFERRING VET

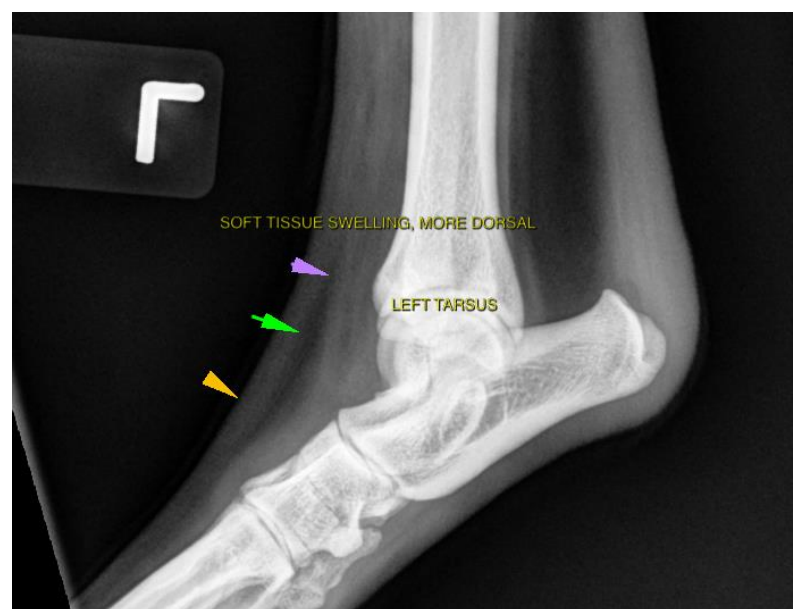
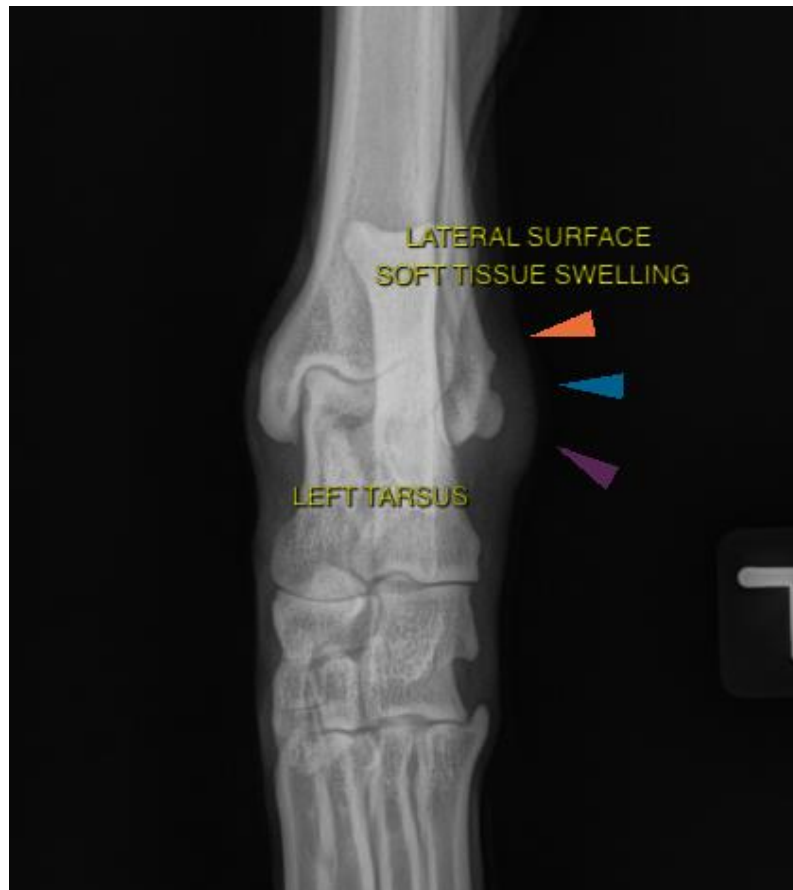Dr. Carlos Abdul-
Chani

INVOICE

59186

DATE

7-6-23





PATIENT

Cooper Strazza

SPECIES

Canine

BREED

Labrador Retriever

SEX

MN

AGE

12 Years

INTERPRETED BY

Tilde Rodrigues Froes,
DMV, MSc., Dr. Med
Vet., Dipl. CBraRVet

HOSPITAL NAME

Byram Animal
Hospital

REFERRING VET

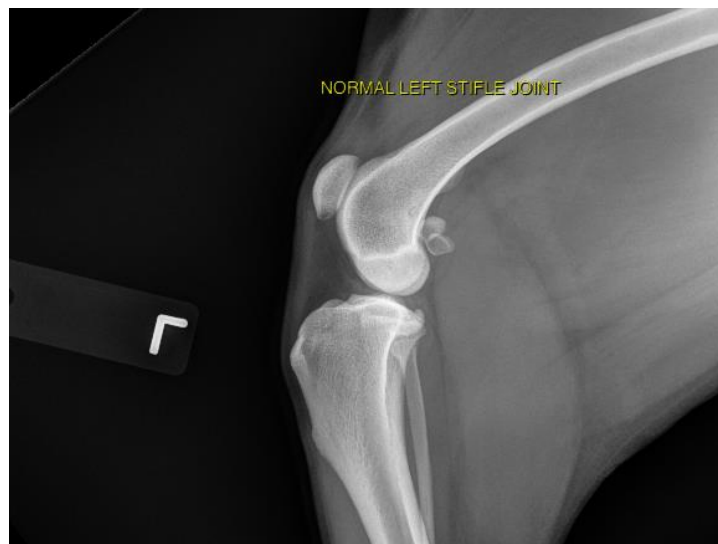
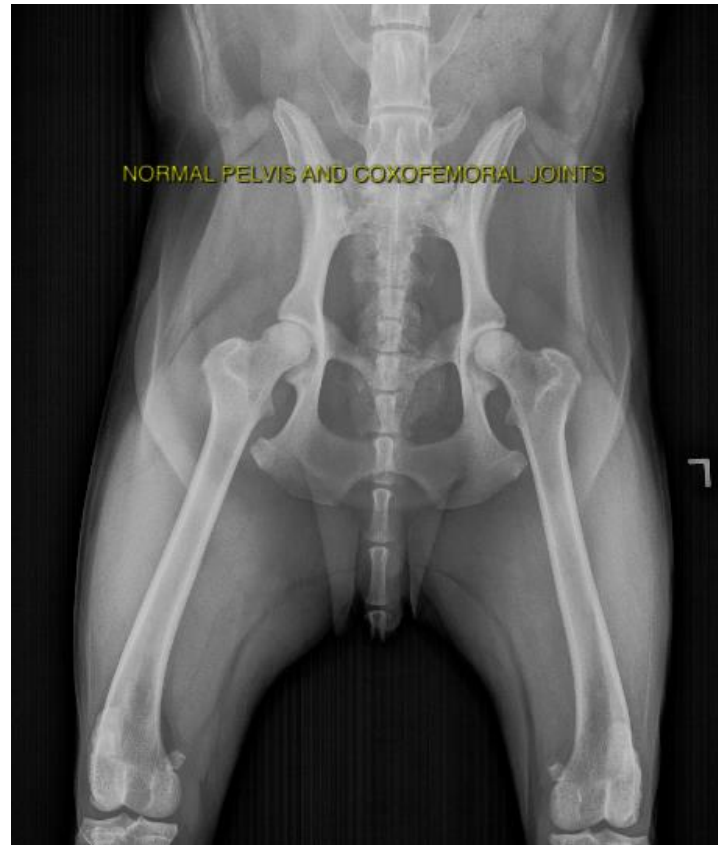Dr. Carlos Abdul-
Chani

INVOICE

59186

DATE

7-6-23





PATIENT

Cooper Strazza

SPECIES

Canine

BREED

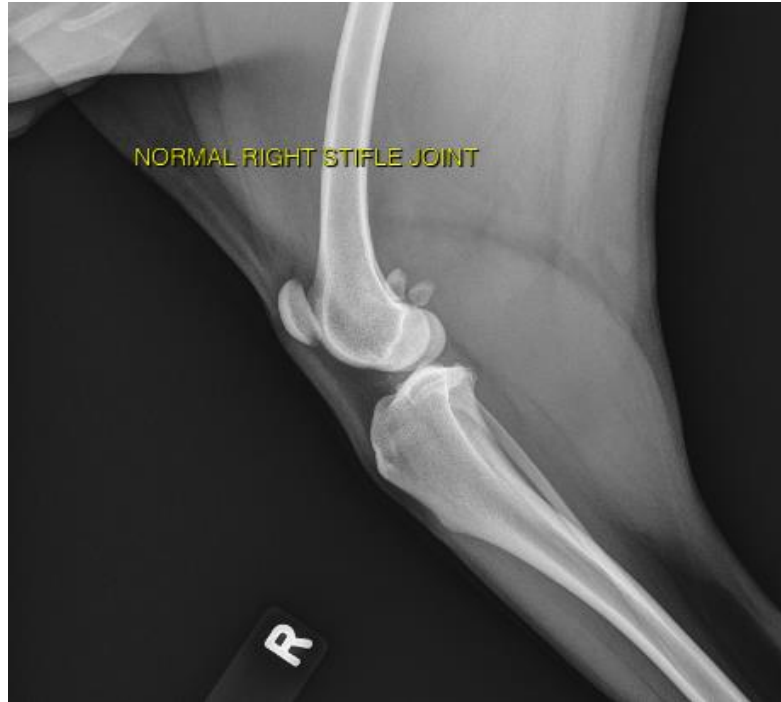Labrador Retriever

SEX

MN

AGE

12 Years



INTERPRETED BY

Tilde Rodrigues Froes,
DMV, MSc., Dr. Med
Vet., Dipl. CBraRVet

The information and recommendations provided are based on the images presented by the referring veterinarian. No evaluation can be communicated regarding pathology that was not visible in the image/video clips provided.

Thank you for this referral. If the clinical or image interpretation does not parallel your findings or if I can be of any further assistance please contact me.

HOSPITAL NAME

Byram Animal
Hospital

Tilde Rodrigues Froes, DMV, MSc., Dr. Med.Vet., Dipl.CBraRVet
info@sonopath.com

REFERRING VET

Dr. Carlos Abdul-
Chani

INVOICE

59186

DATE

7-6-23