



PATIENT PRESENTING CLINICAL SIGNS

Louie Poupore Coughing since early June- worse in AM or after resting, crackles noted, normal resp rate (40 while in Hosp and nervous)/HR 110, Grade V systolic murmur no improvement with lasix, resolved with initial Doxy/temeril P came back when discontinued, responded again with temeril P alone but recurred on tapered dose.

SPECIES

Canine

Abnormal PE/Chem/CBC/UA Results: normal ProBNP, 4dx negative, elevated Eosinophils, rest WNL

RADIOGRAPHIC STUDY OF THE THORAX

BREED

Dachshund

Radiographs of the thorax, in three imaging planes are provided for review, right lateral, left lateral and ventrodorsal views, totaling 3 images.

RADIOGRAPHIC FINDINGS

SEX

The trachea is normal.

NM

There is a diffuse mixed bronchial and unstructured interstitial pattern throughout the pulmonary parenchyma. Only seen on the ventrodorsal views, a focal patchy alveolar pattern is seen in the periphery of the caudal subsegment of the left cranial lung lobe. The pulmonary parenchyma presents variable volume expansion between the views.

AGE

12 Years

The cardiac silhouette spans approximately 55% of the thoracic width, 3.5 intercostal spaces, with normal shape. (VHS = 10.9), with convex border in the left caudodorsal contour. The pulmonary vessels are normal (VLAS = 1.9)

INTERPRETED BY

Tilde Rodrigues Froes, DMV, MSc., Dr. Med Vet., Dipl. CBraRVet

The mediastinum and pleural space are normal.

The diaphragm and thoracic wall are unremarkable.

The collimated abdominal structures are unremarkable.

HOSPITAL NAME

Stuga North Veterinary Care

Mild periarticular ossification is seen at the caudal aspect of both shoulders and in both elbow joints.

RADIOGRAPHIC DIAGNOSIS

REFERRING VET

Kellie Pesola

- Mild diffuse bronchial and interstitial pulmonary pattern. The differential diagnosis includes allergic lower airway disease, chronic bronchitis, infectious bronchitis.
- Focal patchy alveolar pulmonary pattern, differential diagnosis includes focal mild bronchopneumonia, aspiration pneumonia, or pulmonary passive atelectasis.
- Mild left-side compensated cardiomegaly.
- Bilateral shoulder and elbow osteoarthritis, incidental.

INVOICE

59456

INTERPRETATION OF THE FINDINGS & FURTHER RECOMMENDATIONS

The pulmonary radiographic findings can explain the clinical signs of chronic cough and crackles noted on the auscultation. The radiographic findings are likely correlated to respiratory disease.

DATE

7-19-23

No evidence of decompensated left side cardiac disease.



PATIENT

Considering a medical treatment for allergic/inflammatory bronchitis and due to the patchy alveolar opacification, a treatment for bronchopneumonia could be considered.

Louie Poupore

The patient's VLAS value is in normal range. A cut-off value for hemodynamically unstable patients is 2.3 to 2.5 value.

SPECIES

Canine

If patient does not improve, consider bronchoalveolar lavage for obtaining samples for cytology, culture, and sensitivity.

BREED

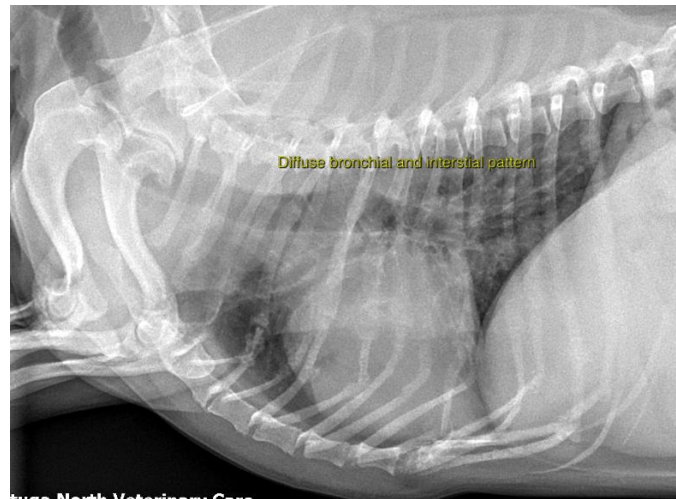
Dachshund

SEX

NM

AGE

12 Years



Stuga North Veterinary Care

INTERPRETED BY

Tilde Rodrigues Froes,
DMV, MSc., Dr. Med
Vet., Dipl. CBraRVet

HOSPITAL NAME

Stuga North
Veterinary Care

REFERRING VET

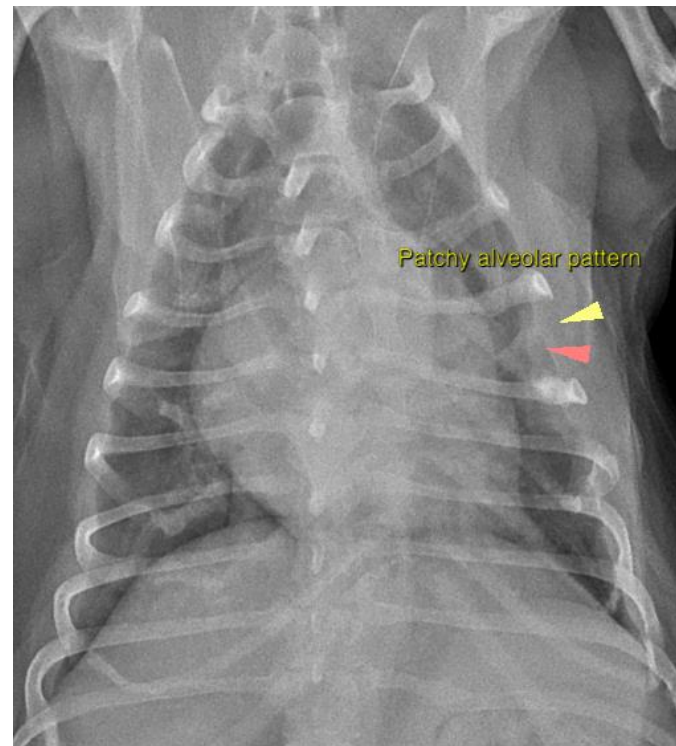
Kellie Pesola

INVOICE

59456

DATE

7-19-23





PATIENT

Louie Poupore

SPECIES

Canine

BREED

Dachshund

SEX

NM

AGE

12 Years

INTERPRETED BY

Tilde Rodrigues Froes,
DMV, MSc., Dr. Med
Vet., Dipl. CBraRVet

HOSPITAL NAME

Stuga North
Veterinary Care

REFERRING VET

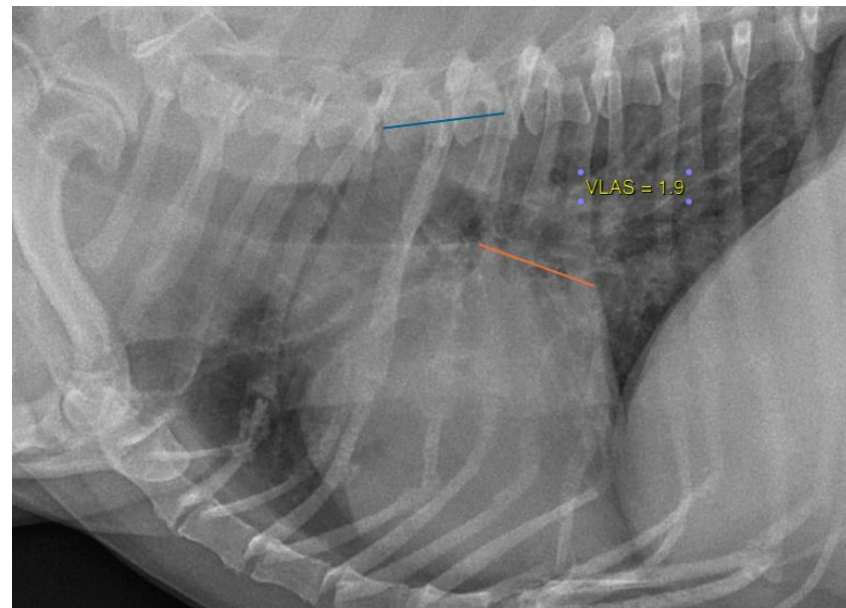
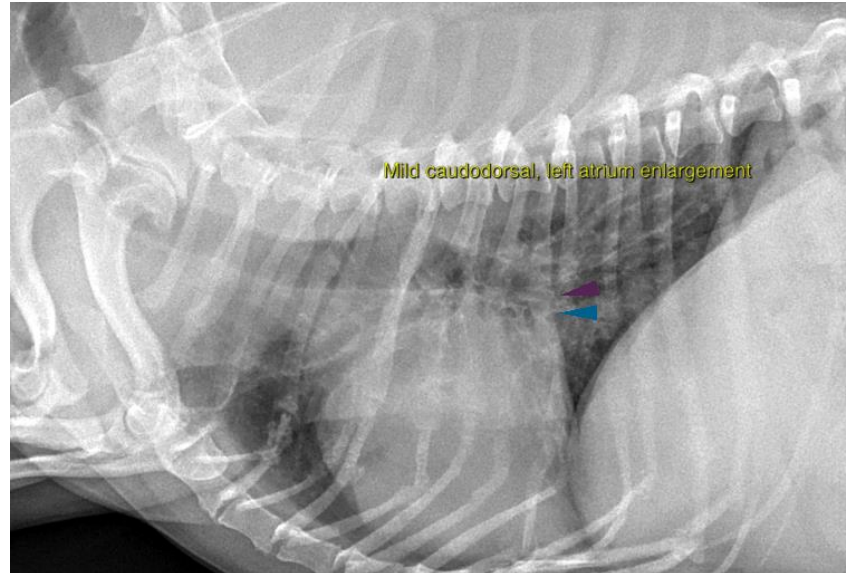
Kellie Pesola

INVOICE

59456

DATE

7-19-23





PATIENT

Louie Poupore

SPECIES

Canine

BREED

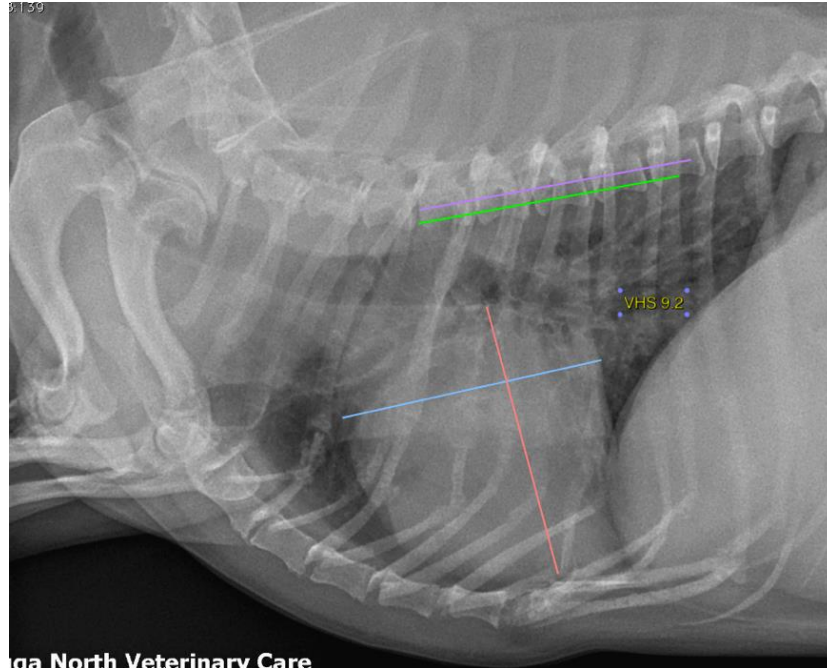
Dachshund

SEX

NM

AGE

12 Years



INTERPRETED BY

Tilde Rodrigues Froes,
DMV, MSc., Dr. Med
Vet., Dipl. CBraRVet

The information and recommendations provided are based on the images presented by the referring veterinarian. No evaluation can be communicated regarding pathology that was not visible in the image/video clips provided.

Thank you for this referral. If the clinical or image interpretation does not parallel your findings or if I can be of any further assistance please contact me.

HOSPITAL NAME

Stuga North
Veterinary Care

Tilde Rodrigues Froes, DMV, MSc., Dr. Med.Vet., Dipl.CBraRVet
info@sonopath.com

REFERRING VET

Kellie Pesola

INVOICE

59456

DATE

7-19-23