



PATIENT PRESENTING CLINICAL SIGNS

Jackson Deutsch Acute coughing episode after vomiting, very lethargic T=104
Abnormal PE/Chem/CBC/UA Results: Pending

SPECIES RADIOGRAPHIC STUDY OF THE THORAX

Canine Orthogonal views of the thorax are provided for review totaling two images. One right lateral view and one left lateral view.

BREED RADIOGRAPHIC FINDINGS

Goldendoodle The thoracic trachea is normal.

SEX There is a diffuse pulmonary pattern and mixed bronchial, unstructured interstitial, and more exacerbated ventrally distributed alveolar pattern. The alveolar pattern is silhouetting the cardiac silhouette.

Male Neutered

The cardiac silhouette and pulmonary vessels are normal. (VHS = 9.5)

AGE The pleural space and mediastinum are normal.

11 Years The diaphragm is normal.

The collimated abdomen is unremarkable.

INTERPRETED BY

Tilde Rodrigues Froes, DMV, MSc., Dr. Med Vet., Dipl. CBraRVet

The musculoskeletal structures are unremarkable.

RADIOGRAPHIC DIAGNOSIS

- Moderate diffuse mixed pulmonary pattern and ventrally distributed alveolar pattern. The differential diagnosis includes aspiration pneumonia and infectious bronchopneumonia (e.g., bacterial).
- Otherwise, normal thorax.

HOSPITAL NAME

New Bridge Veterinary Practice

INTERPRETATION OF THE FINDINGS & FURTHER RECOMMENDATIONS

The pulmonary radiographic findings can explain the patient's clinical signs. Medical therapy is suggested. If the patient does not improve, a bronchoalveolar lavage may be useful in obtaining samples for cytology, culture, and sensitivity. In addition, consider a recheck with three-view radiographs in 15-20 days.

REFERRING VET

Dr. Abina Glennon

INVOICE

59280

DATE

7-11-23



PATIENT

Jackson Deutsch

SPECIES

Canine

BREED

Goldendoodle

SEX

Male Neutered

AGE

11 Years

INTERPRETED BY

Tilde Rodrigues Froes,
DMV, MSc., Dr. Med
Vet., Dipl. CBraRVet

HOSPITAL NAME

New Bridge
Veterinary Practice

REFERRING VET

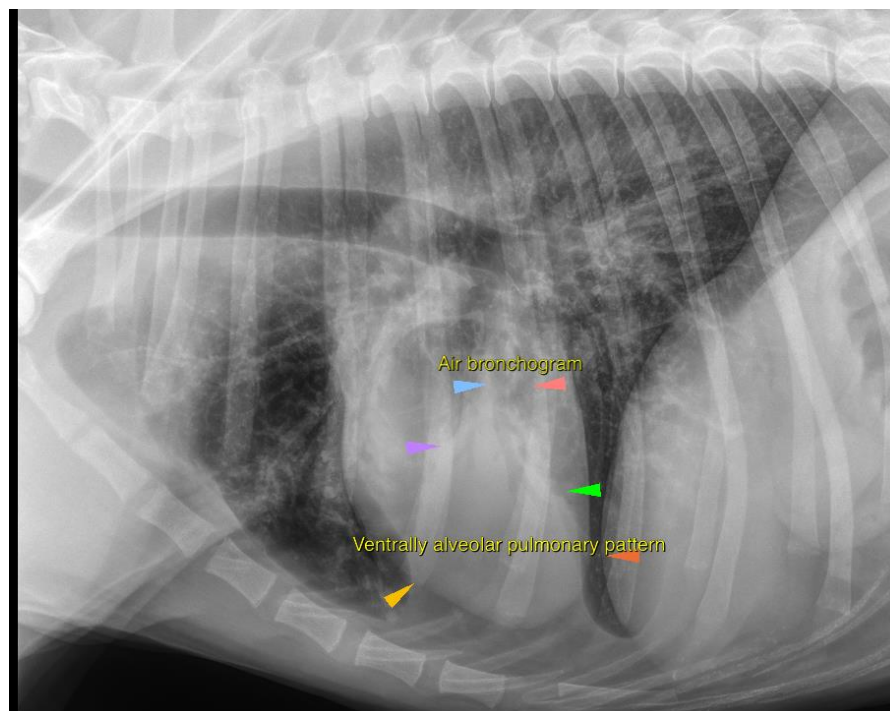
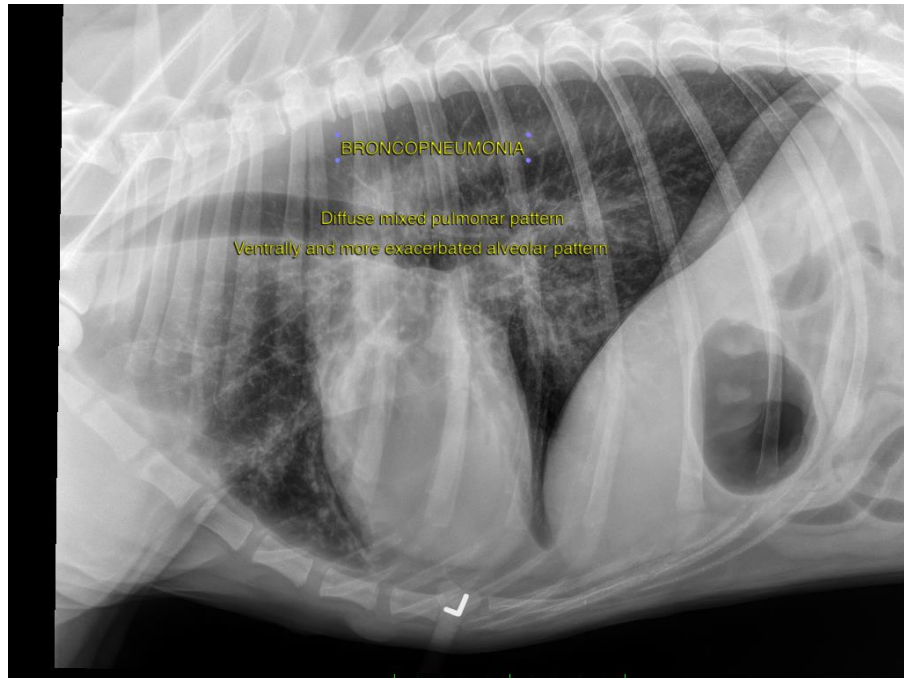
Dr. Abina Glennon

INVOICE

59280

DATE

7-11-23





PATIENT

Jackson Deutsch

The information and recommendations provided are based on the images presented by the referring veterinarian. No evaluation can be communicated regarding pathology that was not visible in the image/video clips provided.

SPECIES

Canine

Thank you for this referral. If the clinical or image interpretation does not parallel your findings or if I can be of any further assistance please contact me.

BREED

Goldendoodle

Tilde Rodrigues Froes, DMV, MSc., Dr. Med.Vet., Dipl.CBraRVet
info@sonopath.com

SEX

Male Neutered

AGE

11 Years

INTERPRETED BY

Tilde Rodrigues Froes,
DMV, MSc., Dr. Med
Vet., Dipl. CBraRVet

HOSPITAL NAME

New Bridge
Veterinary Practice

REFERRING VET

Dr. Abina Glennon

INVOICE

59280

DATE

7-11-23