



PATIENT PRESENTING CLINICAL SIGNS

Robin Priehs 4 month history of upper airway congestion, coughing and gagging. Non-responsive to various antibiotics and steroids. Biopsies, fungal and bacterial cultures taken after CT scan

SPECIES COMPUTED TOMOGRAPHIC STUDY OF THE HEAD

Canine A pre- and post-contrast CT study of the head are provided for review totaling two series. One pre-contrast series and one post-contrast series, bone algorithm.

BREED COMPUTED TOMOGRAPHIC FINDINGS

JRT The nasal cavities are filled with a moderate amount of multifocal hypoattenuating fluid material, more mid to rostral portion. There is moderate asymmetry with loss of turbinate architecture and mucosal enhancement (> right side). No evident mass effect is seen in the nasal cavities or hyperostosis changes.

SEX MN There is a small focal osteolytic lesion within the dorsal nasal planum causing a minor interruption in the nasal bone.

AGE There is a small amount of hypoattenuating fluid accumulation within the choana. The nasopharynx is normal.

15 Years, 5 Months There is diffuse horizontal and vertical bone loss in the maxillary and mandibular bones. A more regional irregular geographic lysis is associated with the triadans 104, 208, & 209.

INTERPRETED BY

Tilde Rodrigues Froes, DMV, MSc., Dr. Med Vet., Dipl. CBraRVet

Multiple teeth are missing including the triadans 105, 106, 108, 109, 110, 210, 301, 302, 305, 308, 30, 310, 311, 408, 409, 410 and 411. There is a remaining root at the triadan 106.

There are some lytic lesions in the dentin at the triadans 104 and 107.

There is oronasal communication adjacent to the root and resorptive lesion at the triadans 104 and 208.

HOSPITAL NAME

Wilson Veterinary Hospital

The frontal sinuses and sphenoidal sinuses are unremarkable.

The cribriform plate is intact.

REFERRING VET

Dr. Keith Burge

The tympanic bullae and the external auditory canals are unremarkable.

No mass effect is seen in the brain or abnormal enhancing.

The temporomandibular joints are bilaterally congruent.

INVOICE

59060

The globes and retrobulbar spaces are unremarkable.

The medial retropharyngeal lymph nodes and mandibular lymph nodes are unremarkable.

DATE

6-28-23



PATIENT COMPUTED TOMOGRAPHIC DIAGNOSIS

- Robin Priehs
- Moderate destructive rhinitis, more right side. The lesions are more prominent adjacent and contiguous to the dental findings and regions where an oronasal communication are noted especially corresponding with the triadans 104 and 208.
- SPECIES**
- Diffuse periodontal disease, moderate periapical resorptive lesions adjacent to the triadans 104, 208 and 209, likely associated regional osteomyelitis.
- Canine
- Multiple teeth are missing.
 - Caries at the triadans 104 and 107.
 - Small focal osteolytic change in the nasal bone and nasal dorsal planum - focal osteomyelitis, less likely small traumatic fracture.
- BREED**
- Fluid retention in the choana.

JRT

INTERPRETATION OF THE FINDINGS & FURTHER RECOMMENDATIONS

SEX The moderate destructive rhinitis is likely correlated to the severe dental disease, and this is linked to the presented clinical signs of upper airway congestion. Other concurrent differential diagnosis includes bacterial, viral, lymphocytic, plasmocytic, or less likely fungal rhinitis.

MN

There is no evidence of mass effects or radiopaque foreign material in the nasal cavities.

AGE Correlate the oral tomographic findings with the oral and dental exams. For more effective treatment to the chronic rhinitis consider a dental treatment.

15 Years, 5 Months

INTERPRETED BY

Tilde Rodrigues Froes,
DMV, MSc., Dr. Med
Vet., Dipl. CBraRVet

HOSPITAL NAME

Wilson Veterinary
Hospital

REFERRING VET

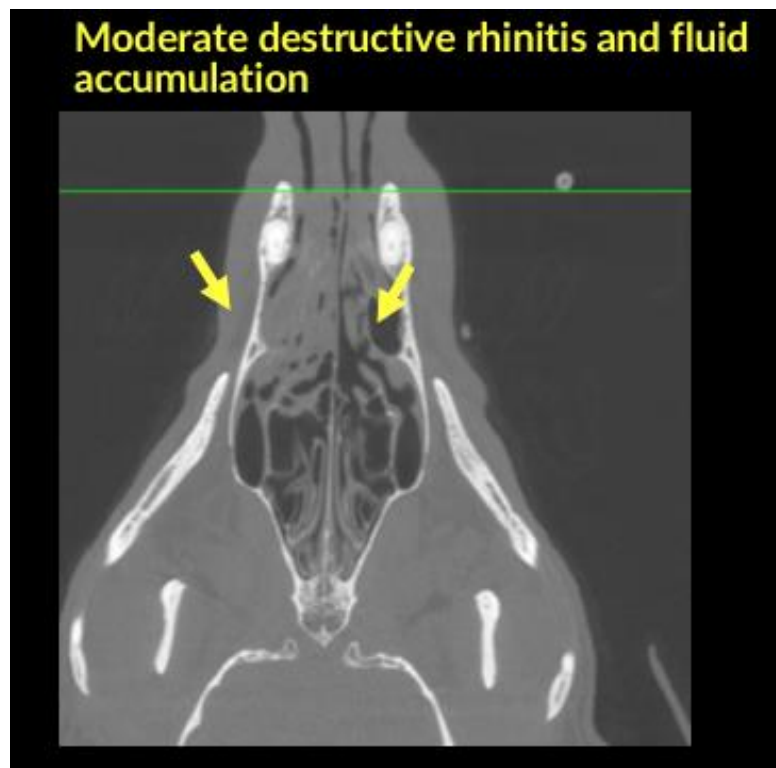
Dr. Keith Burge

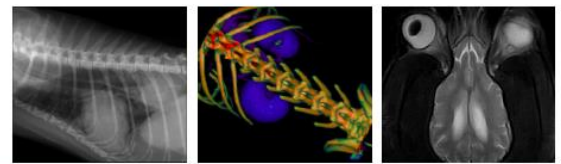
INVOICE

59060

DATE

6-28-23





PATIENT

Robin Priehs

SPECIES

Canine

BREED

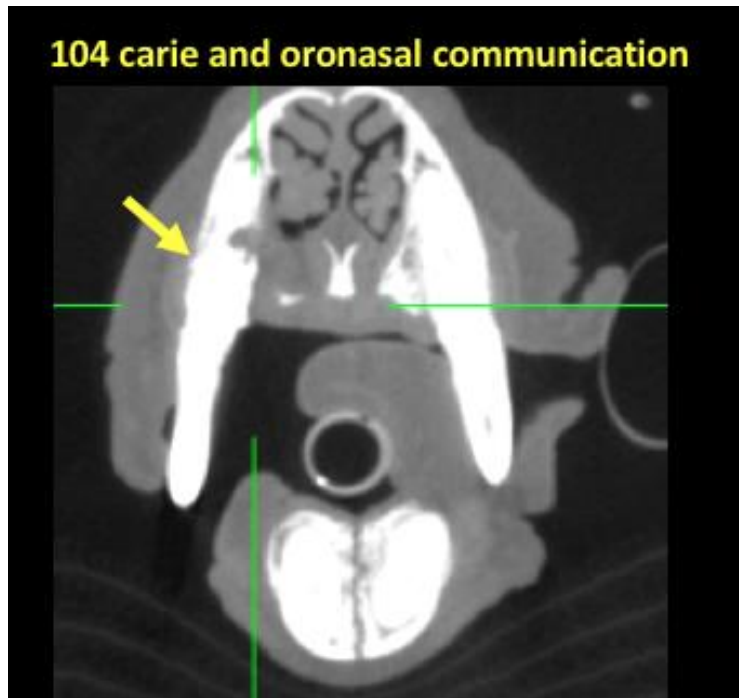
JRT

SEX

MN

AGE

15 Years, 5 Months



INTERPRETED BY

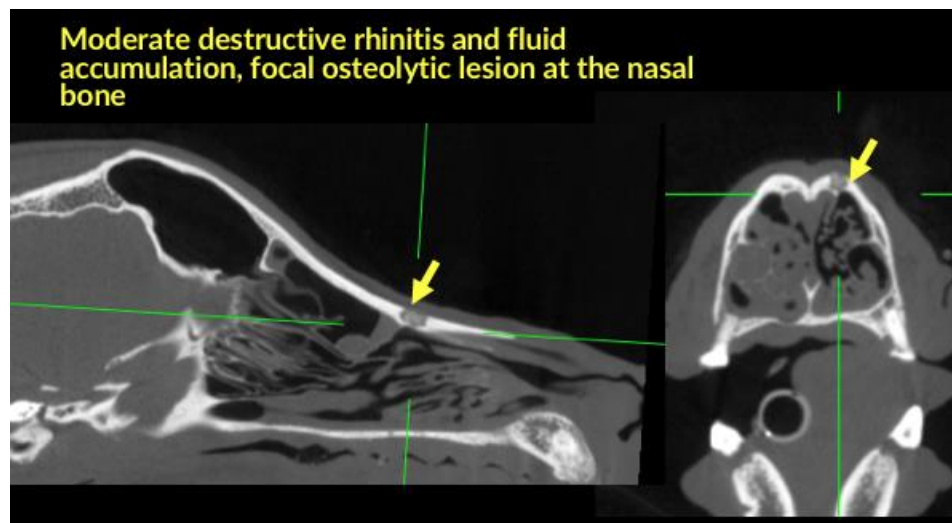
Tilde Rodrigues Froes,
DMV, MSc., Dr. Med
Vet., Dipl. CBraRVet

HOSPITAL NAME

Wilson Veterinary
Hospital

REFERRING VET

Dr. Keith Burge



INVOICE

59060

DATE

6-28-23



PATIENT

Robin Priehs

SPECIES

Canine

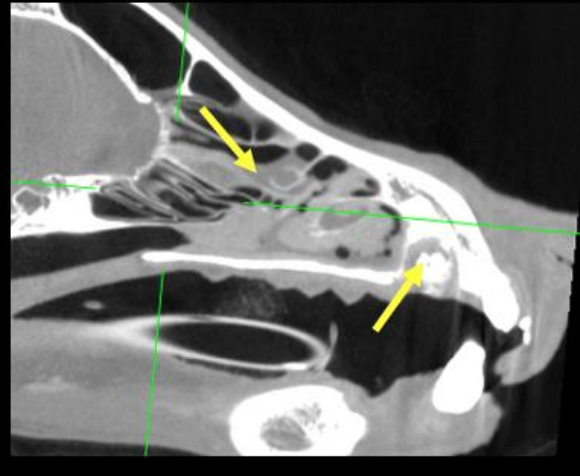
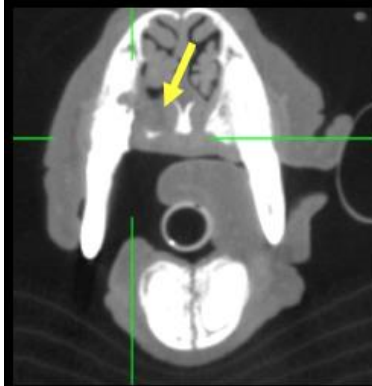BREED

JRT

SEX

MN

Moderate destructive rhinitis and fluid accumulation, resorptive lesion at the triadan 104



AGE

15 Years, 5 Months

The information and recommendations provided are based on the images presented by the referring veterinarian. No evaluation can be communicated regarding pathology that was not visible in the image/video clips provided.

INTERPRETED BY

Tilde Rodrigues Froes,
DMV, MSc., Dr. Med
Vet., Dipl. CBraRVet

Thank you for this referral. If the clinical or image interpretation does not parallel your findings or if I can be of any further assistance please contact me.

Tilde Rodrigues Froes, DMV, MSc., Dr. Med.Vet., Dipl.CBraRVet
info@sonopath.com

HOSPITAL NAME

Wilson Veterinary
Hospital

REFERRING VET

Dr. Keith Burge

INVOICE

59060

DATE

6-28-23