



PATIENT PRESENTING CLINICAL SIGNS

Dove Harmon Pt had UTI and blood in her urine, even after 2 rounds of abx, still having blood in urine. BW: wnl

SPECIES RADIOGRAPHIC STUDY OF THE ABDOMEN

Feline Orthogonal views of the abdomen are available for review totaling 4 images. One ventrodorsal view and three lateral views.

RADIOGRAPHIC FINDINGS

BREED The urinary bladder is mildly filled with the apex in the plane of L6. A rounded mineral opaque calculi is centrally located measuring 1.0cm x 0.7cm in diameter.

DSH

The renal silhouettes are normal in size, shape, and contour.

SEX The liver and spleen are normal in size, shape, and contour.

SF

The stomach contains a minimal amount of gas admixed with homogeneous soft tissue opaque fluid material.

AGE

The small intestines are normally distributed, of normal diameter, and contain a moderate amount of gas and homogeneous soft tissue fluid material.

10 Years

The colon contains a moderate amount of heterogeneous soft tissue, opaque fecal material, and gas.

INTERPRETED BY

The abdominal serosal detail and retroperitoneal space are normal.

Tilde Rodrigues Froes,
DMV, MSc., Dr. Med
Vet., Dipl. CBraRVet

The collimated musculoskeletal structures and thorax are normal.

RADIOGRAPHIC DIAGNOSIS

- Moderately sized nonobstructive cystic calculus. The differential diagnosis includes concurrent cystitis.
- Otherwise, normal abdomen.

HOSPITAL NAME

The Pet Hospital of
Stratford

INTERPRETATION OF THE FINDINGS & FURTHER RECOMMENDATIONS

The identification of a cystic calculi can explain the lower urinary clinical signs, and recurrence of blood in the urine. Concurrent inflammatory and/or infectious disease is considered. Consider surgical removal. A bladder ultrasonography could be considered for analysis of the bladder wall.

REFERRING VET

Dr. Giuliani

INVOICE

59062

DATE

6-28-23



PATIENT

Dove Harmon

SPECIES

Feline

BREED

DSH

SEX

SF

AGE

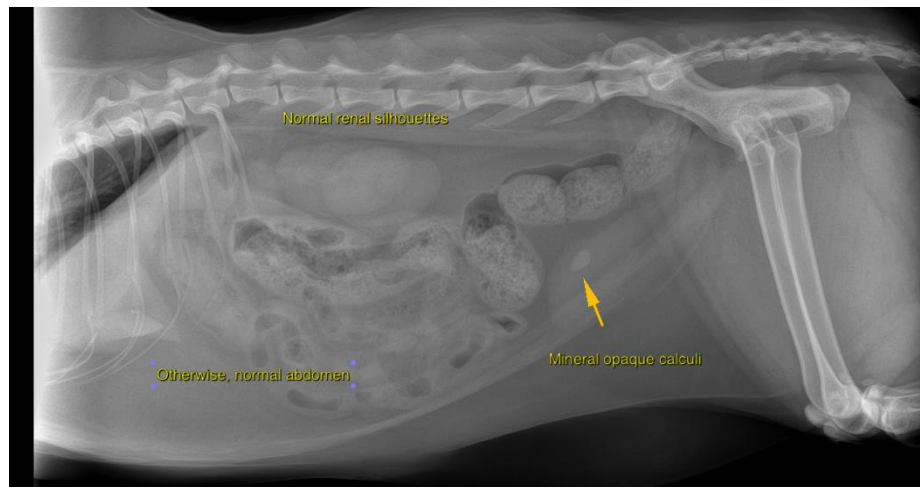
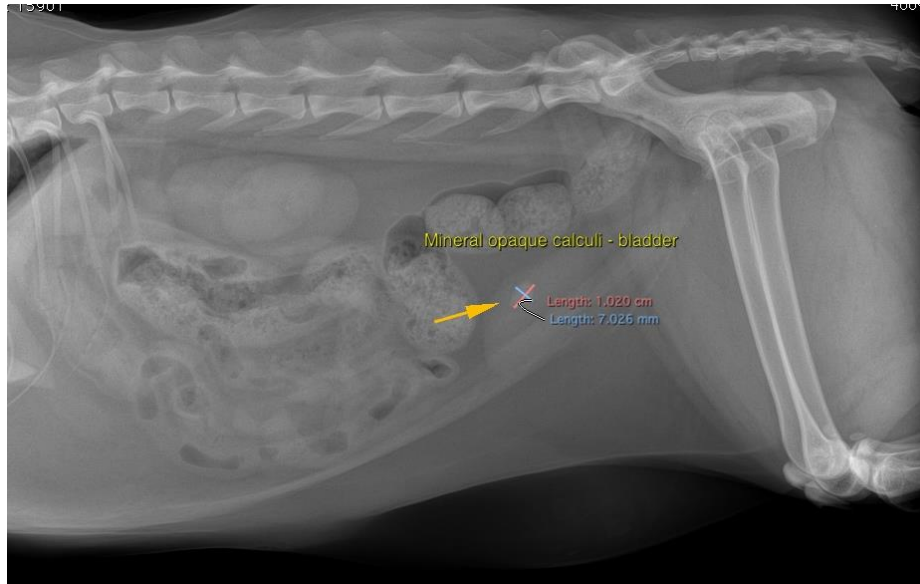
10 Years

INTERPRETED BY

Tilde Rodrigues Froes, DMV, MSc., Dr. Med Vet., Dipl. CBraRVet

HOSPITAL NAME

The Pet Hospital of Stratford



REFERRING VET

Dr. Giuliani

The information and recommendations provided are based on the images presented by the referring veterinarian. No evaluation can be communicated regarding pathology that was not visible in the image/video clips provided.

INVOICE

59062

Thank you for this referral. If the clinical or image interpretation does not parallel your findings or if I can be of any further assistance please contact me.

DATE

6-28-23

Tilde Rodrigues Froes, DMV, MSc., Dr. Med.Vet., Dipl.CBraRVet
info@sonopath.com