



PATIENT PRESENTING CLINICAL SIGNS

Blue Bell Beer Female Spayed Feline 12 year old with chronically elevated liver enzymes Not symptomatic currently. Pet has been on Ursodiol 50mg SID and Denamarin 90mg SID for 1.5 months (current); treated with 2 rounds of Droncit and a 10 days course of Amoxicillin.

SPECIES Abnormal PE/Chem/CBC/UA Results: Increase of Alkphos , ALT and bile acids. GGT Normal, calcium high.

Feline

COMPUTED TOMOGRAPHIC STUDY OF THE ABDOMEN

BREED A pre-and post-contrast CT study of the abdomen are provided for review, totaling 3 series. A pre-contrast, post-contrast arterial phase, post-contrast venous/portal phase of full abdomen.

Domestic Short Hair

COMPUTED TOMOGRAPHIC FINDINGS

SEX The liver is homogenously soft tissue attenuating and uniformly contrast enhancing with normal size and shape. The gallbladder contains hypoattenuating fluid material with thin wall. The biliary cystic duct is normally distended. The intra-hepatic biliary tract is unremarkable. The common bile duct is normal in size and pathway. No evidence of radiopaque biliary mineralization.

FS

AGE

The portal vein, intra-hepatic and hepatic vasculature are normal.

12

The renal silhouettes are normal in size, shape, contour, and attenuation pre- and post-contrast. The renal length is 4.1cm in the right kidney. The renal length is 4.0cm in the left kidney.

INTERPRETED BY

The urinary bladder is moderately filled, with the apex in the plane of L6, and is homogeneously soft tissue hypoattenuating. No evidence of radiopaque calculi.

Tilde Rodrigues Froes, DMV, MSc., Dr. Med Vet., Dipl. CBraRVet

The spleen is mildly diffusely enlarged, homogeneously soft tissue attenuating, and uniformly contrast enhancing, likely correlated to the anesthesia.

HOSPITAL NAME

The stomach is empty and normally positioned, containing a minimal amount of intraluminal gas.

Mobile Pet Imagine

The duodenum and small intestine are nondilated and contain a small amount of fluid attenuating material and gas.

REFERRING VET

The colon and rectum contain gas admixed with a moderate amount of heterogeneously soft tissue attenuating fecal material.

Villasmil

The pancreas and mesentery are normal.

INVOICE

The adrenal glands and retroperitoneal space are normal.

59063

The abdominal lymph nodes and adrenal glands are normal.

The musculoskeletal structures collimated on the field are normal.

DATE

The collimated thorax is unremarkable.

6-28-23



PATIENT COMPUTED TOMOGRAPHIC DIAGNOSIS

Blue Bell Beer

- Normal liver parenchyma and biliary tract, no evidence of biliary lithiasis, or obstruction.
- Mild homogeneous splenomegaly, likely correlated to anesthesia. The differential diagnosis includes lymphoid hyperplasia, extra medullary hematopoiesis, or less likely infiltrative disease.
- Otherwise, normal abdomen.

SPECIES

Feline

INTERPRETATION OF THE FINDINGS & FURTHER RECOMMENDATIONS

BREED

Domestic Short Hair

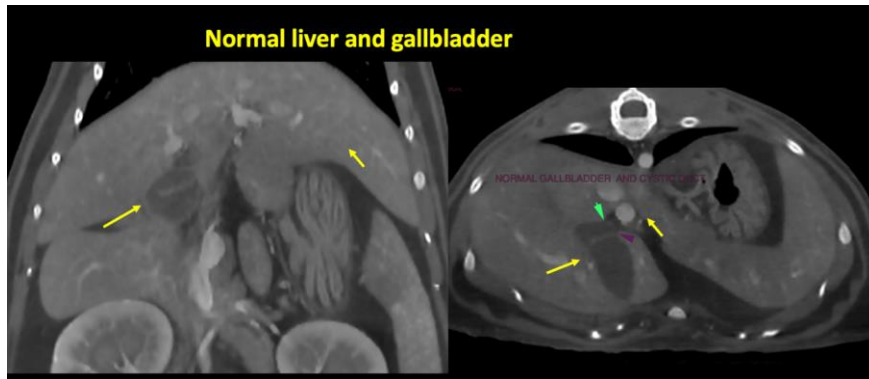No evidence of biliary obstruction or lithiasis. No signs of hepatic nodules, masses, or morphological abnormalities in the liver that could be correlated with increased laboratory abnormalities. Consider hepatopathy without morphological changes, and more acute disease in these cases, possible cholecystitis and cholangiohepatitis that do not change the tomographic aspect of the liver.

SEX

FS

AGE

12



INTERPRETED BY

Tilde Rodrigues Froes,
DMV, MSc., Dr. Med
Vet., Dipl. CBraRVet

HOSPITAL NAME

Mobile Pet Imagine

REFERRING VET

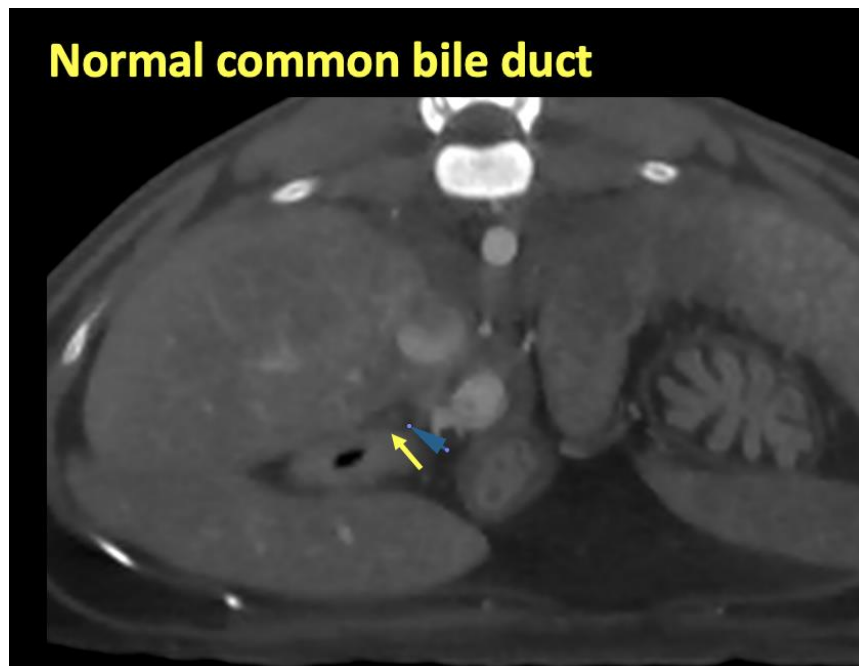
Villasmil

INVOICE

59063

DATE

6-28-23





PATIENT

Blue Bell Beer

SPECIES

Feline

BREED

Domestic Short Hair

SEX

FS

AGE

12

INTERPRETED BY

Tilde Rodrigues Froes,
DMV, MSc., Dr. Med
Vet., Dipl. CBraRVet

HOSPITAL NAME

Mobile Pet Imagine

REFERRING VET

Villasmil

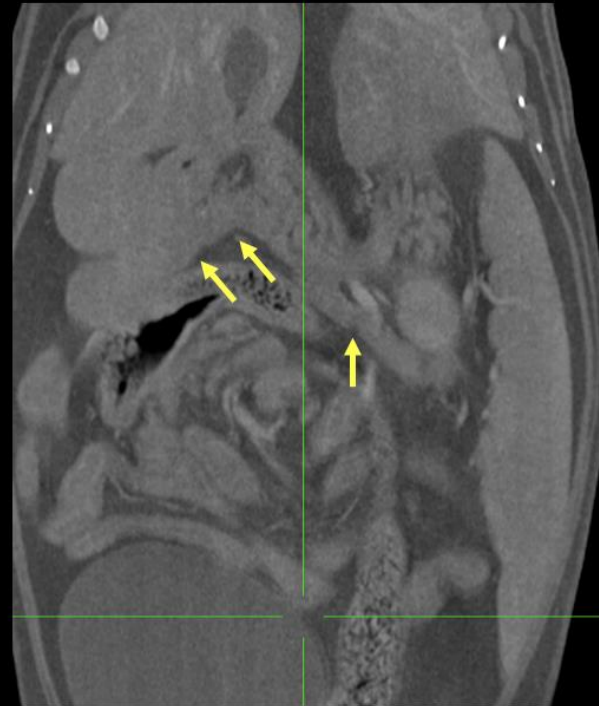
INVOICE

59063

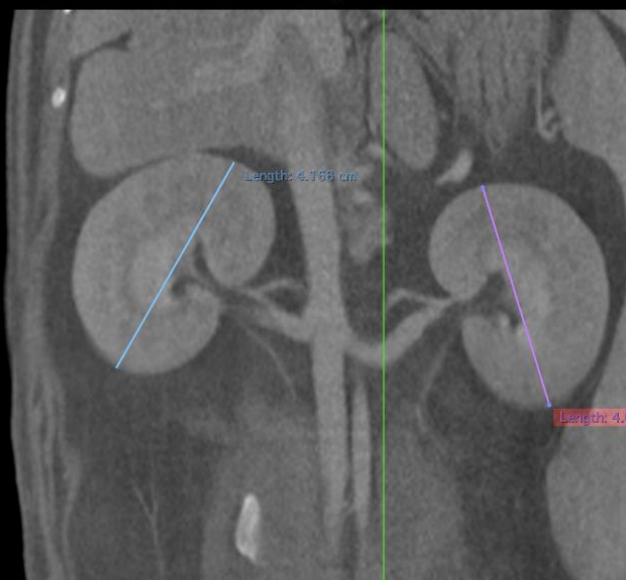
DATE

6-28-23

Normal pancreas



Normal kidneys





PATIENT

Blue Bell Beer

The information and recommendations provided are based on the images presented by the referring veterinarian. No evaluation can be communicated regarding pathology that was not visible in the image/video clips provided.

SPECIES

Feline

Thank you for this referral. If the clinical or image interpretation does not parallel your findings or if I can be of any further assistance please contact me.

BREED

Domestic Short Hair

Tilde Rodrigues Froes, DMV, MSc., Dr. Med.Vet., Dipl.CBraRVet
info@sonopath.com

SEX

FS

AGE

12

INTERPRETED BY

Tilde Rodrigues Froes,
DMV, MSc., Dr. Med
Vet., Dipl. CBraRVet

HOSPITAL NAME

Mobile Pet Imagine

REFERRING VET

Villasmil

INVOICE

59063

DATE

6-28-23